

# Dynamic and Static Stabilization of Anterior Shoulder Instability With the Subscapular Sling Procedure



Jan Arild Klungsøyr, M.D., Terje Vagstad, M.D., Peter Johannes Klungsøyr, M.D., Alf Inge Hellevik, M.D., Ph.D., and Jon Olav Drogset, M.D., Ph.D.

**Abstract:** There are numerous arthroscopic techniques available to address anterior shoulder instability. Complications are various, and in pursuit of new treatment options, an alternative arthroscopic technique with less potential for complications has been developed. The novel subscapular sling with a semitendinosus graft provides both dynamic and static stability. This procedure uses a semitendinosus graft as a sling around the upper two-thirds of the subscapular tendon, attached to the anterior glenoid rim. The sling phenomenon present in the Latarjet procedure was the basis of the development. The efficacy of the subscapular sling procedure has been verified in biomechanical studies and further investigated in a clinical pilot study. The procedure can be performed without altering the anatomy of nearby structures such as the coracoid process, the conjoined tendon, and the axillary and musculocutaneous nerves. The authors propose the arthroscopic subscapular sling procedure as an alternative to existing surgical treatment options for recurrent anterior shoulder instability.

Anterior shoulder instability is a challenge both for patients and surgeons. There are many treatment options available, depending on the structures injured.<sup>1</sup> In cases of mere anterior soft-tissue damage, the traditional Bankart repair may be used.<sup>2</sup> Bone-transferring procedures are preferable in shoulders with severe glenoid bone loss and residual luxation following previous soft-tissue stabilization.<sup>3-5</sup> Both Bankart and bone-grafting procedures been known to have complications.<sup>6-11</sup> The potential for better treatment options led to the development of the

subscapular sling with a semitendinosus (ST) graft.<sup>12,13</sup> Feasibility and biomechanical cadaveric studies have been performed,<sup>12,13</sup> and a clinical pilot study of the subscapular sling shows promising preliminary results. The purpose of this paper is to present the surgical procedures involved in the subscapular sling method with an ST graft. The ST graft is pulled through a slit in the subscapular tendon and attached to the anterior glenoid rim to replace the torn labrum. A sling is constructed around the upper two-thirds of the subscapular tendon and provides, together with the reconstruction of the labrum, both static and dynamic stabilization of the shoulder (Fig 1).

From the Norwegian University of Science and Technology (NTNU), Faculty of Medicine and Health Sciences, Trondheim (J.A.K.); Department of Orthopaedic Surgery, Ålesund Hospital, Møre and Romsdal Hospital Trust, Ålesund (J.A.K., T.V., P.J.K., A.I.H.); and Department of Orthopedic Surgery, Trondheim University Hospital and Norwegian University of Science and Technology (NTNU), Trondheim (J.O.D.), Norway.

The authors report the following potential conflicts of interest or sources of funding: The study was funded by Aalesund Hospital, Møre and Romsdal Health Trust, Norway, and the Norwegian University of Science and Technology, Trondheim, Norway. Full ICMJE author disclosure forms are available for this article online, as [supplementary material](#).

Received January 13, 2021; accepted March 18, 2021.

Address correspondence to Jan Arild Klungsøyr, M.D., Department of Orthopaedic Surgery, Ålesund Hospital, Møre and Romsdal Hospital Trust, Ålesund, Norway. E-mail: [janarild.klungsoyr@gmail.com](mailto:janarild.klungsoyr@gmail.com)

© 2021 THE AUTHORS. Published by Elsevier Inc. on behalf of the Arthroscopy Association of North America. This is an open access article under the CC BY license (<http://creativecommons.org/licenses/by/4.0/>).

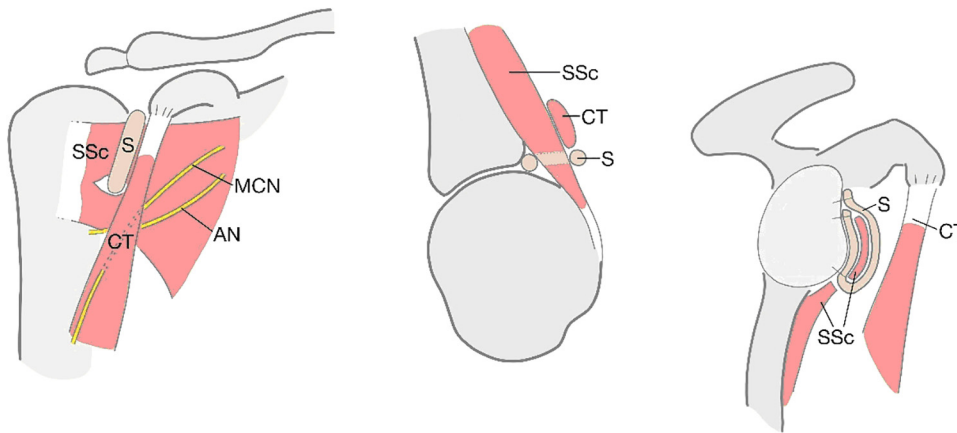
2212-6287/2164

<https://doi.org/10.1016/j.eats.2021.03.027>

## Surgical Procedure (With Video Illustration)

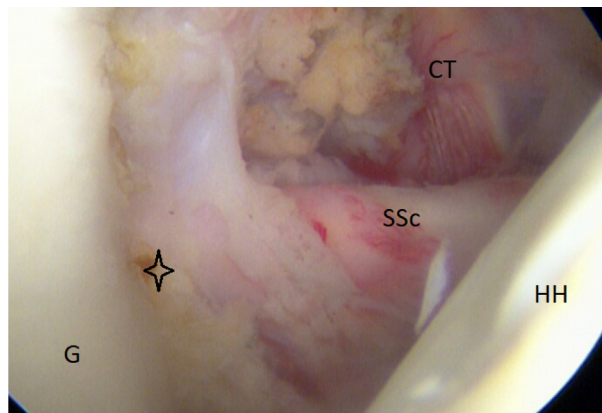
The surgical procedure is illustrated in [Video 1](#). The patient is placed in the beach chair position under general anesthesia with an optional brachial plexus block. For ease of graft harvest and patient positioning, the ipsilateral knee is used when possible. The knee is draped, and local anesthesia with adrenalin is applied to avoid the use of a tourniquet. The anatomic landmarks of the shoulder are marked ([Fig 2](#)). Standard posterior portal, anterior, and anterosuperior portals are positioned with the anterior portal cranial to the superior edge of the subscapular tendon.

A diagnostic arthroscopy is performed after an external examination of the shoulder stability. The

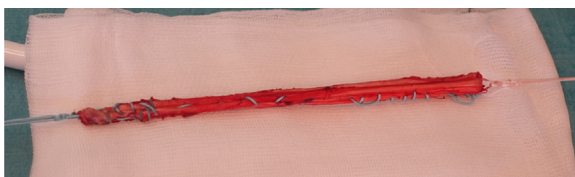

**Fig 1.** Schematic drawings of the subscapular sling. Sling (S), subscapular tendon (SSc), conjoint tendon (CT), axillary nerve (AN), and musculocutaneous nerve (MCN).

**Fig 2.** Patient in beach chair position during surgery of the left shoulder. Coracoid process (CP). Posterior portal for viewing; the anterosuperior (AS), anterior (A), and anterior lateral portal (AL) for instrumenting.



**Fig 3.** Arthroscopic view of a right shoulder, posterior viewing portal. The star sign indicates the lost anterior labrum on the glenoid (G). (CT conjoint tendon; HH, humeral head; SSc, subscapular tendon.)

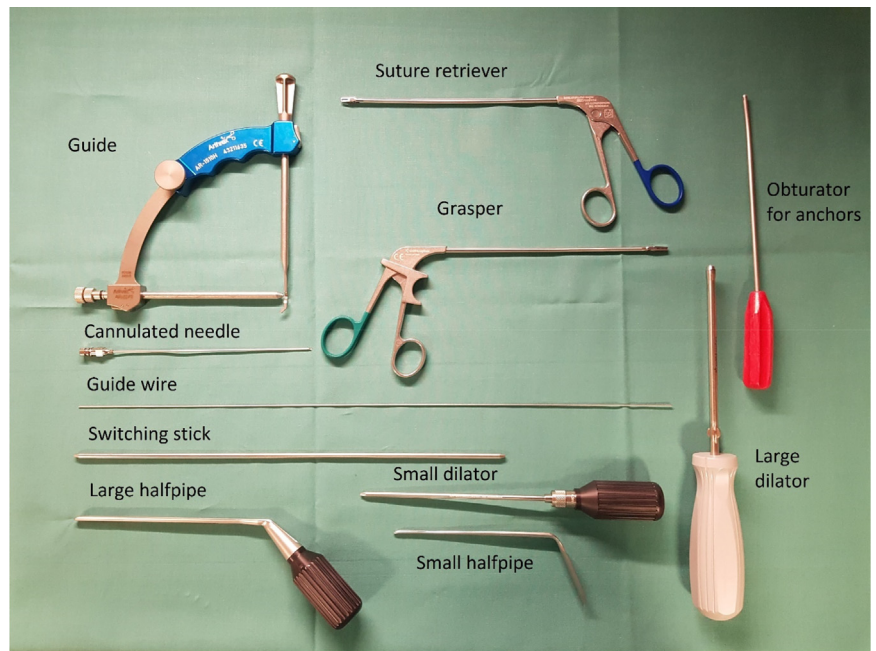


**Fig 4.** Semitendinosus graft doubled and whipstitched ready for fixation.

rotator cuff and in particular the subscapular tendon are inspected to rule out injuries. Furthermore, the amount of glenoid bone loss, on/off-track Hill–Sachs lesions, and labral and ligament ears are assessed (Fig 3).

The ST tendon is identified through a small skin incision on the proximal medial tibia and harvested with a corkscrew tendon stripper. The graft is doubled, whip stitched, and the length is measured. Additional

**Fig 5.** Arthroscopic instruments needed to perform the subscapular sling procedure.



sutures are placed at both ends of the graft to ease the advancement into the joint and around the subscapular tendon before fixation (Fig 4). Before skin closure, a 12-gauge catheter is advanced on the medial side of the thigh along the remaining hamstrings tendon to administer ropivacaine.

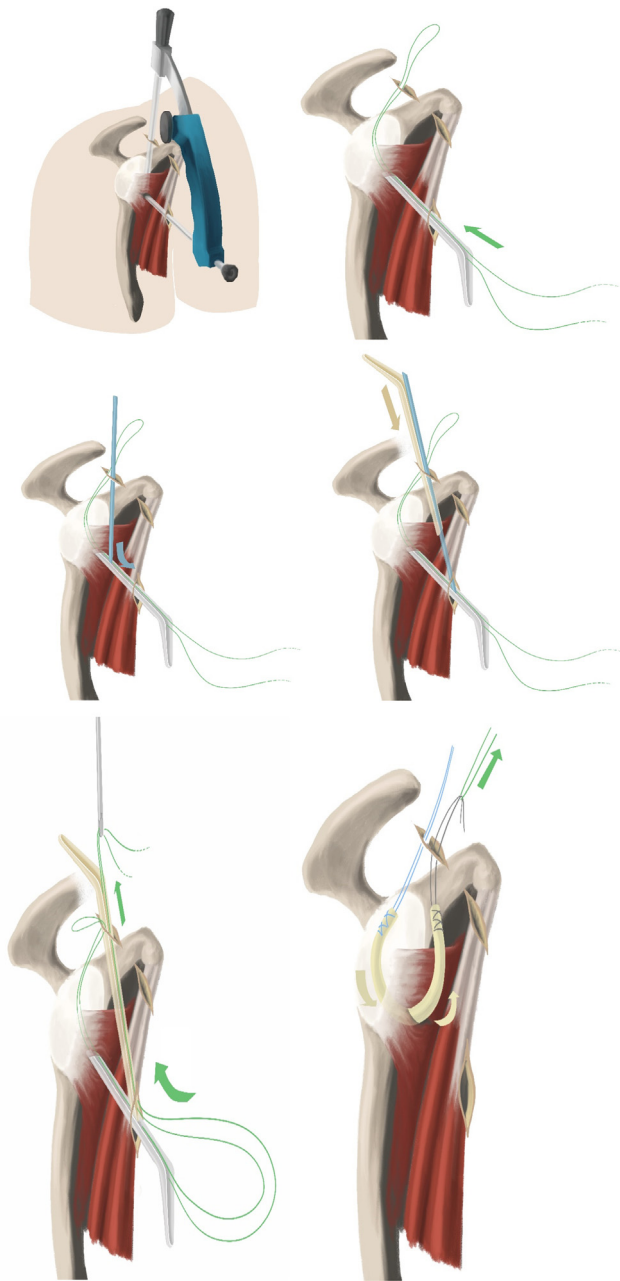
Remnants of the anterior labrum are removed from the 2- to 5-o'clock position using different rasps, shaver, and radiofrequency coblation. The anterior glenoid must be cleared of soft tissue to support ingrowth of the ST graft. The anterior portion of the subscapular tendon is cleared, and the axillary nerve is identified and kept at a distance from the portals and instruments during surgery. All instrumentation is performed lateral to the conjoined tendon, thus also preserving the musculocutaneous nerve, which is not visualized. The lower anterolateral portal is created lateral to the conjoined tendon from anterior to posterior direction using an aiming guide, cannulated needle, guidewire, switching stick, and halfpipe instruments with the shoulder in 20° of external rotation (Figs 5-7 and Video 1). The aiming guide has a marking at 3 cm, allowing the surgeon to decide the proportion of the subscapular tendon to be included in the sling.

After the correct placement of the aiming guide, a long, cannulated needle is advanced into the joint and a switching stick slid carefully over it (Figs 8 and 9).

Dilators of increasing size are advanced over the switching stick and finally, a halfpipe instrument is placed through the subscapular tendon into the joint (Figs 9 and 10).

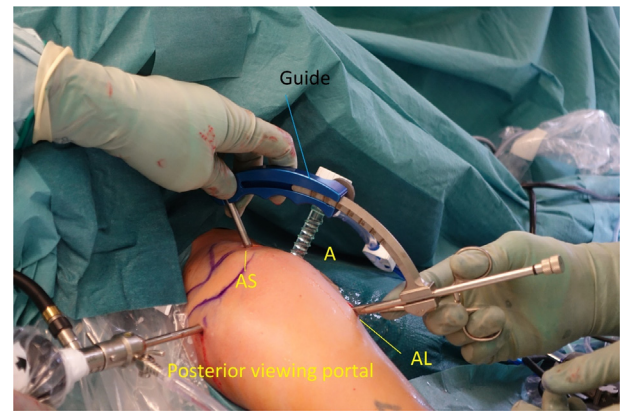
A banana knife or a coblation device is passed over the halfpipe and used to make a slit in the longitudinal direction between the lower and middle third of the subscapular tendon. This is performed with a neutral rotation of the shoulder and cutting from medial to lateral under visual control. A short switching stick or blunt round instrument is advanced on the anterior wall of the subscapular tendon through the anterosuperior portal down to the halfpipe to facilitate the placement of a pulling suture (#2) and subsequently the ST-graft (Figs 6 and 11). With the help of a grasper, the pulling suture (#2) is introduced into the joint between the glenoid and the posterior wall of the subscapular tendon from the anterosuperior portal through the slit in the subscapular tendon and back out through the anterosuperior portal (Figs 6, 12, and 13). The tendinous graft end is connected to this suture and pulled into the joint and around the subscapular tendon through the anterosuperior portal (Fig 14).

It is of immense importance to keep the shoulder in at least 20° of internal rotation at this point of the procedure to avoid impingement of the graft between the humeral head and the subscapular tendon. An external



**Fig 6.** Schematic drawings of a right shoulder. The aiming guide and the creation of the slit in the subscapular tendon with halfpipes is demonstrated. The green pulling suture advances the semitendinosus graft into the glenohumeral joint and around the subscapular tendon.

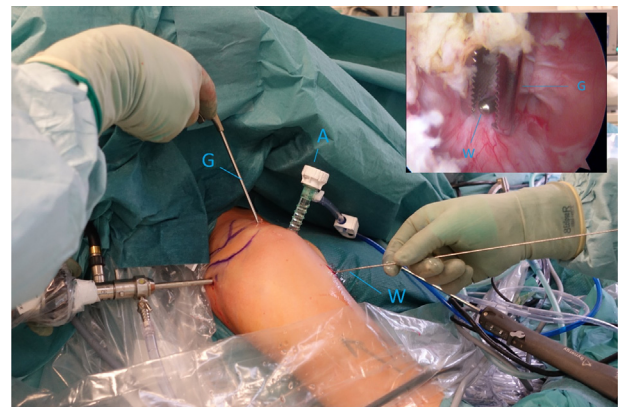
rotation would hinder the gliding and correct placement of the ST graft. FiberTak Soft anchors (Arthrex, Naples, FL) are placed from the 3- to 5-o'clock position to fixate the graft to the anterior glenoid rim to replace the lost anterior labrum (Figs 15 and 16). After the firm attachment is confirmed with a grasper, the remaining end of the graft, situated on the anterior side of the subscapular tendon, is pushed into the glenoid rim at approximately the 2 o'clock position. Two additional



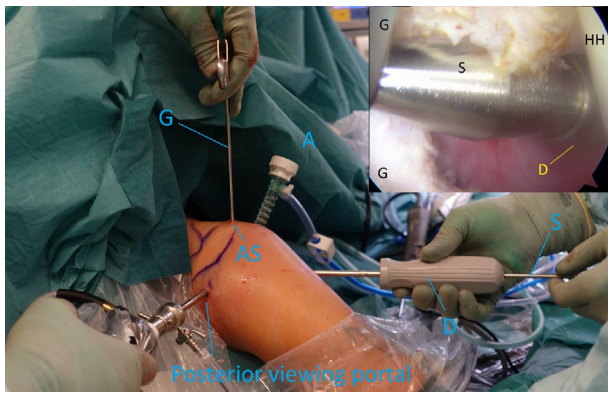
**Fig 7.** Right shoulder. The correct placement of the aiming guide in the antersuperior (AS) and anterolateral (AL) portals. An 8-mm arthroscopic cannula is in the anterior portal (A).

anchors are placed at this level, and the suture limbs are pulled through the ST-graft fibers to achieve a solid attachment (Figs 17-20).

To prevent a reduction in external rotation and abduction, the arm is at this point of the procedure held in 30° of abduction and 20° of external rotation to prevent the sling being too tight. The remaining graft is cut and removed from the joint. The graft fixation is assessed and the shoulder advanced carefully into the 90/90 position to judge the stability and containment of the joint. The joint is flushed, and the portals and camera are removed. The small incisions are sutured, and the shoulder is placed in a supportive sling for 4 weeks. Patients are recommended a postoperative rehabilitation program instructed by a physiotherapist. Pendulum and limited rotational exercises are started on the first postoperative day.



**Fig 8.** Right shoulder with a supplementary arthroscopic view, posterior viewing portal. Guidewire (W) is in the anterolateral portal, and the grasper (G) is in the antersuperior portal to control right position of the guidewire.

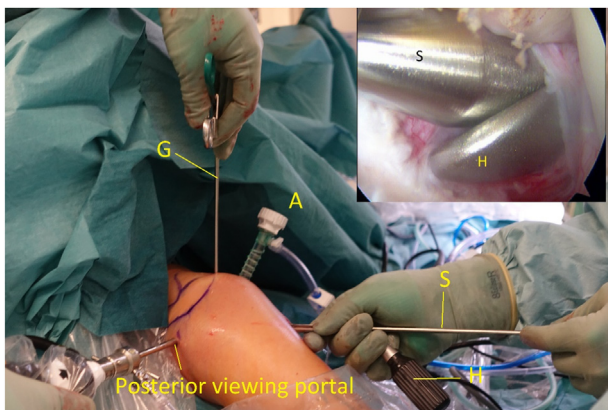


**Fig 9.** Right shoulder with a supplementary arthroscopic view, posterior viewing portal. Switching stick (S) and dilator (D) are in the anterolateral portal. (A, anterior portal; AS, anterosuperior portal; G, Grasper; HH, humeral head.)

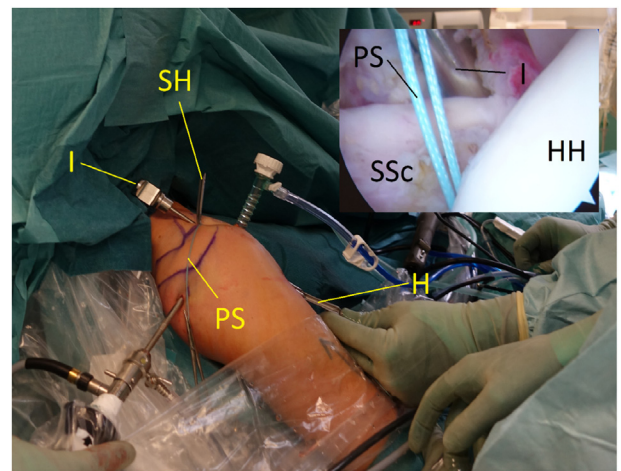
**Discussion**

This paper presents the surgical technique of the novel subscapular ST sling. The sling supports the subscapular tendon and pulls it in a posterior direction to prevent an anterior dislocation. The ST graft replaces the lost anterior labrum and has, together with the subscapular tendon sling, both a static and dynamic stabilizing effect on the shoulder (Fig 21).

This procedure is an alternative option to other arthroscopic stabilizing procedures to treat anterior shoulder instability. After a Bankart stabilization, one third of the patients (mainly male patients younger than the age of 22 years) experience residual dislocation or do not return to their preinjury sporting level.<sup>7,14-16</sup> In cases of previously performed soft-tissue stabilizing with recurrence, treatment options are usually different bone grafting procedures.<sup>17</sup> The iliac crest bone grafting procedure and the Latarjet render good

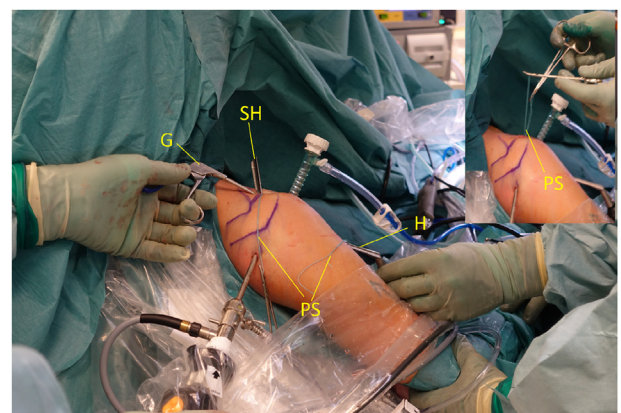


**Fig 10.** Right shoulder with a supplementary arthroscopic view, posterior viewing portal. Switching stick (S) and half-pipe (H) are in the anterolateral portal. Grasper (G) is in the anterosuperior portal and cannula in the anterior portal (A).

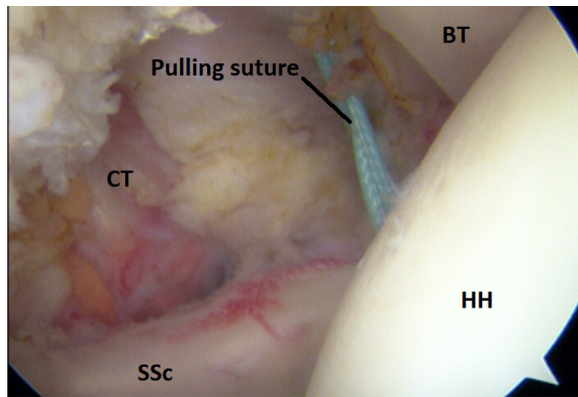


**Fig 11.** Right shoulder with a posterior arthroscopic view. Halfpipe (H) in the anterolateral portal, small halfpipe (SH) in the anterosuperior portal with the introducer (I). The pulling suture (PS) is situated posterior of the subscapular tendon (SSc) and the introducer (I) anterior of the subscapular tendon out through the anterolateral portal, humeral head (HH).

results but do have complications.<sup>6,8,18</sup> The subscapular sling is part of a development in recent years seeking to find a surgical technique with fewer potential complications. Such a new procedure could fill the large gap between the Bankart fixation and the more difficult and anatomy-changing bone procedures. The pursuit of new procedures may also lead to the development of better arthroscopic instruments and subsequently improve the treatment options available.



**Fig 12.** Right shoulder. The pulling suture (PS) with one limb in the anterosuperior portal and the other limb in the anterolateral portal. Small halfpipe (SH), halfpipe (H), and grasper (G) facilitate the placement of the pulling suture around the subscapular tendon with both limbs out of the anterosuperior portal (small picture). The correct placement of the pulling suture is verified before the graft is pulled into the joint.

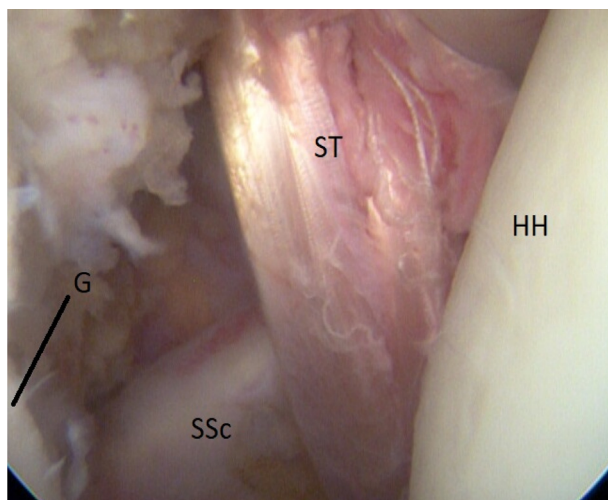


**Fig 13.** Arthroscopic view of a right shoulder, posterior viewing portal. Ti-cron #2 pulling suture situated posterior and anterior of the subscapular tendon and lateral of the conjoined tendon (CT). (BT, biceps tendon; HH, humeral head; SSc, subscapular tendon).

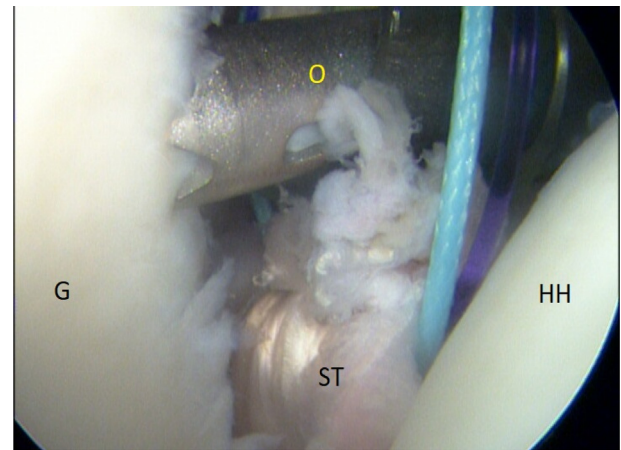
Bone grafting procedures may change the anatomy of the shoulder. They are performed by both open surgery and arthroscopically.<sup>3,19</sup> The proposed technique leaves the coracoid and adjacent tendons untouched and not transferred, which potentially reduces the risks of nerve injury, because portals and instrumentation are not needed medial to the conjoined tendon. A remplissage procedure could be advocated in engaging Hill–Sachs lesions,<sup>20,21</sup> but has to our knowledge not been combined with the subscapular sling.

Table 1 displays the advantages and disadvantages of the subscapular sling procedure.

The drawbacks of this procedure include the use of an ST autograft, but allografts may also be an option. There are reports of reduction in flexion strength at the donor



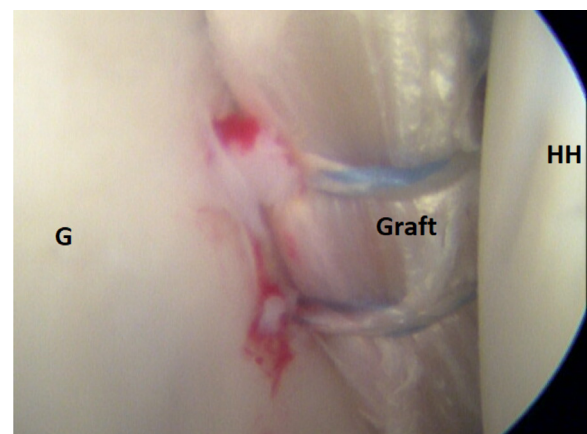**Fig 14.** Intraoperative view of a right shoulder, posterior viewing portal. The semitendinosus graft (ST) is pulled into the joint and through the subscapular slit around the subscapular tendon (SSc). (G, anterior glenoid rim; HH, humeral head.)



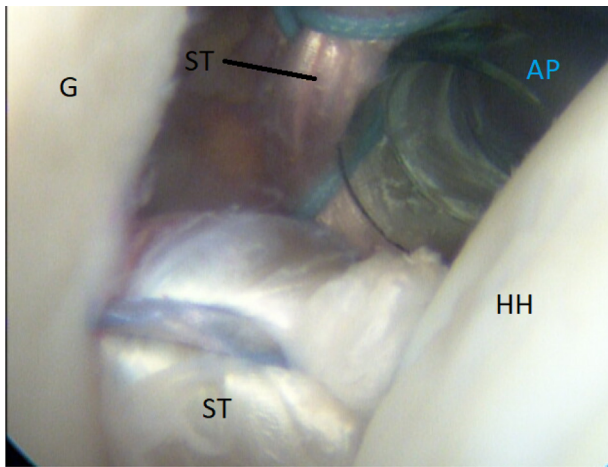
**Fig 15.** Arthroscopic view of a right shoulder, posterior viewing portal. Placement of the first anchor at 3 o'clock through the obturator (O). (G, glenoid; HH, humeral head; ST, semitendinosus graft.)

site, but sequelae are otherwise limited to postoperative pain and loss of sensation around the donor site.<sup>22,23</sup> Patients scheduled for this operation must be informed about the potential of pain, thrombosis, and loss of sensation. Postoperative administration of low-molecular-weight heparin should be considered to avoid thrombosis. The long-term effects of this technique are unknown. Postoperative magnetic resonance imaging has confirmed an intact reconstructed labrum, sling, and subscapular tendon (Fig 22). The sling may nevertheless cause erosion and rupture of the subscapular tendon. Ruptures of such kind or muscle atrophy of the subscapularis have not been detected.

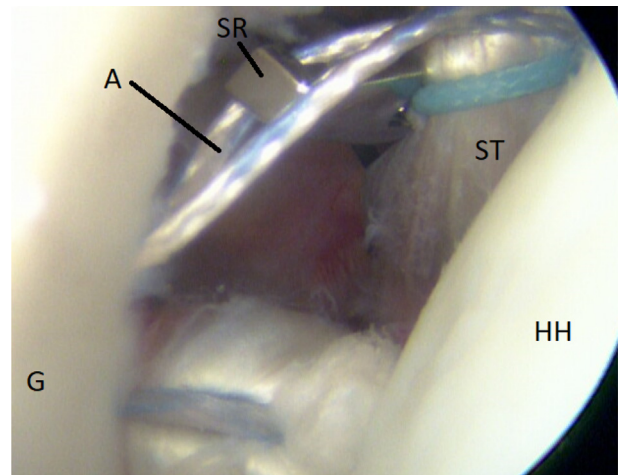
The graft-sling and the subscapular tendon can eventually lose firmness and strength and subsequently reduce the stability of the shoulder. Firm attachment and ingrowth of the graft on the anterior glenoid rim



**Fig 16.** Arthroscopic view of a right shoulder, posterior viewing portal. The attached semitendinosus graft is on the anterior glenoid rim. (G, glenoid; HH, humeral head.)



**Fig 17.** Right shoulder, posterior viewing portal. Arthroscopic view of the correct placement of semitendinosus (ST) graft on the anterior rim is shown. Medial of the anterior portal (AP) is the anterior limb of the ST graft before final fixation of the sling.



**Fig 19.** Arthroscopic view of a right shoulder, posterior viewing portal, is shown. Anchor at 2:30. Suture retriever (SR) pulls a strand from the anchor (A) on the medial side of the semitendinosus (ST) graft to achieve rigid fixation. (G, glenoid; HH, humeral head.)


are essential to achieve a negative joint pressure and suction effect. These effects may diminish if the healing is disturbed by poor graft quality and/or bone quality. The tightness of the sling is important to assess during surgery. An overconstrained sling would hinder the external rotation and may also, in the long run, induce arthritis because of the excessive pressure on the anterior part of the glenohumeral joint.

Table 2 displays the indications and contraindications for this procedure. A torn subscapular tendon is an absolute contraindication because the dynamic stability of the subscapular sling is dependent on an unimpaired tendon. An elongated subscapular tendon with a partial tear may be a relative contraindication. The subscapular

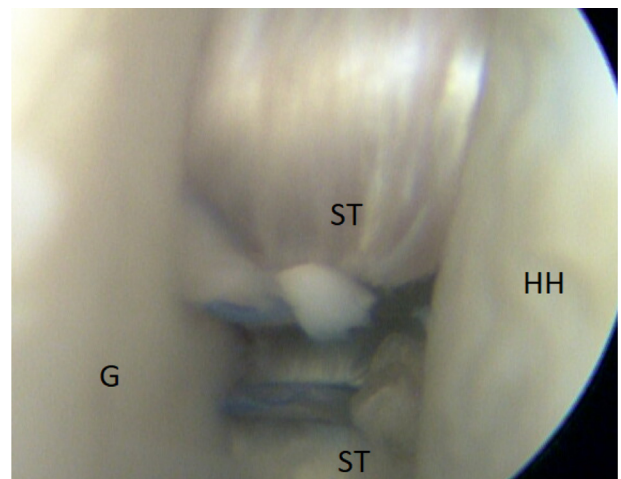
sling has not been tested with substantial glenoid bone loss and should in these cases be avoided until further studies have investigated its efficacy. A further development could be to use a quadriceps tendon–bone graft in shoulders with severe glenoid bone loss.<sup>24</sup> The subscapular sling procedure with a ST graft may in future be included in the possible treatment options for patients suffering from residual anterior shoulder instability.

### Acknowledgments

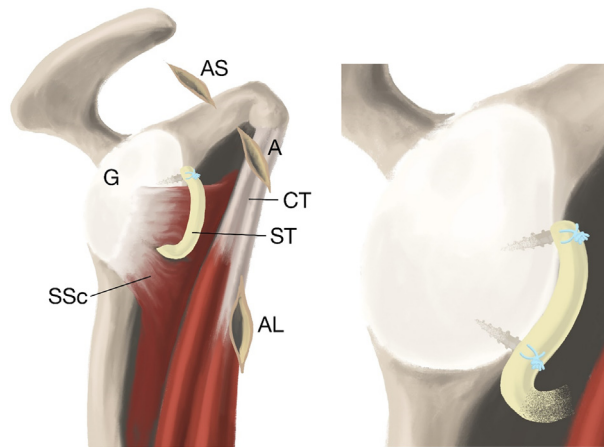
We appreciate Dr. Paul Saunderson, who revised the English text.



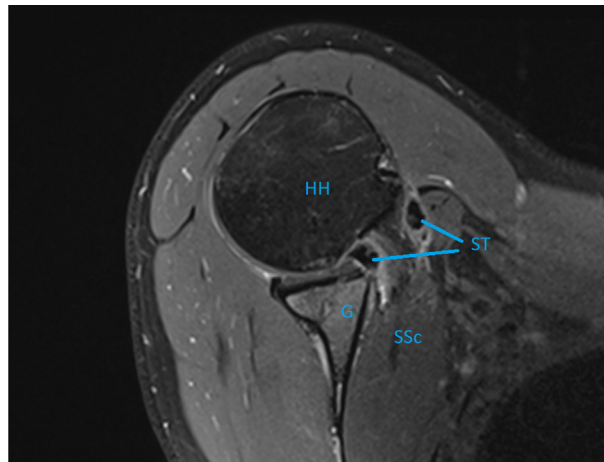
**Fig 18.** Arthroscopic view of a right shoulder, posterior viewing portal, is shown. Placement of an anchor at 2:30 through the obturator (O). (G, glenoid; HH, humeral head; ST, semitendinosus graft.)



**Fig 20.** Final construct of the semitendinosus (ST) graft-sling on the anterior rim of the glenoid (G). Reconstruction of the lost anterior labrum is achieved. Humeral head (HH) is centered in the glenoid (G) cavity.



**Fig 21.** Schematic drawings of the completed sling. Attachment of the graft (ST) on the anterior glenoid (G) rim with anchors and the completed sling (ST) around the subscapular tendon (SSc). (A, anterior portal; AL, anterolateral portal; AS, anterosuperior portal; CT, conjoined tendon).



**Fig 22.** Sagittal magnetic resonance imaging of a right shoulder displaying the intact semitendinosus sling (ST) and the subscapular tendon/muscle (SSc). (G, glenoid; HH, humeral head.)

**Table 1.** Advantages and Disadvantages of the Subscapular Sling Procedure

Advantages	Disadvantages
Arthroscopic technique—easier learning curve	No extension of the glenoid bone margins
Less invasive and minimal change of anatomy	Graft is smaller than the conjoined tendon
Portals lateral of conjoined tendon with less risk of nerve injury	Dependent on full integrity of the subscapular tendon
No overhang of bone on the anterior rim	Semitendinosus autograft with possible sequelae
Soft-tissue reconstruction of labrum with the graft	
No tenodesis of subscapular tendon	

**Table 2.** Suggested Indications and Contraindications for the Subscapular Sling Procedure

Indications	Contraindications
Residual anterior shoulder instability	Posterior and multidirectional instability
Intact subscapular tendon	Torn subscapular tendon
Previous Bankart repair	Previous bony procedures
Minimal glenoid bone loss	Severe glenoid bone loss



## References

- Arner JW, Peebles LA, Bradley JP, Provencher MT. Anterior shoulder instability management: Indications, techniques, and outcomes. *Arthroscopy* 2020;36:2791-2793.
- Balke M, Shafizadeh S, Bouillon B, Banerjee M. Management of shoulder instability: The current state of treatment among German orthopaedic surgeons. *Arch Orthop Trauma Surg* 2016;136:1717-1721.
- Hurley ET, Lim Fat D, Farrington SK, Mullett H. Open versus arthroscopic Latarjet procedure for anterior shoulder instability: A systematic review and meta-analysis. *Am J Sports Med* 2019;47:1248-1253.
- Longo UG, Loppini M, Rizzello G, Ciuffreda M, Maffulli N, Denaro V. Latarjet, Bristow, and Eden-Hybinette procedures for anterior shoulder dislocation: Systematic review and quantitative synthesis of the literature. *Arthroscopy* 2014;30:1184-1211.
- Auffarth A, Schauer J, Matis N, Kofler B, Hitzl W, Resch H. The J-bone graft for anatomical glenoid reconstruction in recurrent posttraumatic anterior shoulder dislocation. *Am J Sports Med* 2008;36:638-647.
- Griesser MJ, Harris JD, McCoy BW, et al. Complications and re-operations after Bristow-Latarjet shoulder stabilization: A systematic review. *J Shoulder Elbow Surg* 2013;22:286-292.
- Randelli P, Ragone V, Carminati S, Cabitza P. Risk factors for recurrence after Bankart repair a systematic review. *Knee Surg Sports Traumatol Arthrosc* 2012;20:2129-2138.
- Gartsman GM, Waggenspack WN Jr, O'Connor DP, Elkousy HA, Edwards TB. Immediate and early complications of the open Latarjet procedure: A retrospective review of a large consecutive case series. *J Shoulder Elbow Surg* 2017;26:68-72.
- Hovellius L, Rahme H. Primary anterior dislocation of the shoulder: Long-term prognosis at the age of 40 years or younger. *Knee Surg Sports Traumatol Arthrosc* 2016;24:330-342.
- Hendy BA, Padegimas EM, Kane L, et al. Early post-operative complications after Latarjet procedure: A single-institution experience over 10 years [published online September 30, 2020]. *J Shoulder Elbow Surg*. <https://doi.org/10.1016/j.jse.2020.09.002>.
- Goodloe JB, Traven SA, Johnson CA, Woolf SK, Nutting JT, Slone HS. Increased risk of short-term complications and venous thromboembolism in Latarjet-Bristow procedures compared with Bankart repairs. *Arthroscopy* 2021;37:806-813.
- Klungsoyr PJ, Guldal F, Vagstad T, Klungsoyr JA. A new subscapular sling operation to stabilize the shoulder. A cadaver study. *J Exp Orthop* 2015;2:12.
- Vagstad T, Klungsoyr PJ, Drogset JO, et al. The novel arthroscopic subscapular sling procedure grants better stability than an arthroscopic Bankart repair in a cadaveric study. *Knee Surg Sports Traumatol Arthrosc* 2020;28:2316-2324.
- Kennedy MI, Murphy C, Dornan GJ, et al. Variability of reporting recurrence after arthroscopic Bankart repair: A call for a standardized study design. *Orthop J Sports Med* 2019;7:2325967119846915.
- van der Linde JA, van Kampen DA, Terwee CB, Dijkman LM, Kleinjan G, Willems WJ. Long-term results after arthroscopic shoulder stabilization using suture anchors: An 8- to 10-year follow-up. *Am J Sports Med* 2011;39:2396-2403.
- Memon M, Kay J, Cadet ER, Shahsavari S, Simunovic N, Ayeni OR. Return to sport following arthroscopic Bankart repair: A systematic review. *J Shoulder Elbow Surg* 2018;27:1342-1347.
- Bushnell BD, Creighton RA, Herring MM. Bony instability of the shoulder. *Arthroscopy* 2008;24:1061-1073.
- Willemot L, De Boey S, Van Tongel A, Declercq G, De Wilde L, Verborgt O. Analysis of failures after the Bristow-Latarjet procedure for recurrent shoulder instability. *Int Orthop* 2019;43:1899-1907.
- Bishop JY, Hidden KA, Jones GL, Hettrich CM, Wolf BR, Group MS. Factors influencing surgeon's choice of procedure for anterior shoulder instability: A multicenter prospective cohort study. *Arthroscopy* 2019;35:2014-2025.
- Hurley ET, Toale JP, Davey MS, et al. Remplissage for anterior shoulder instability with Hill-Sachs lesions: A systematic review and meta-analysis. *J Shoulder Elbow Surg* 2020;29:2487-2494.
- Longo UG. Editorial Commentary: Unsolved problems in shoulder instability—the dilemma of bone loss! *Arthroscopy* 2019;35:1267-1268.
- Yasuda K, Tsujino J, Ohkoshi Y, Tanabe Y, Kaneda K. Graft site morbidity with autogenous semitendinosus and gracilis tendons. *Am J Sports Med* 1995;23:706-714.
- Gifstad T, Sole A, Strand T, Uppheim G, Grontvedt T, Drogset JO. Long-term follow-up of patellar tendon grafts or hamstring tendon grafts in endoscopic ACL reconstructions. *sa Knee Surg Sports Traumatol Arthrosc* 2013;21:576-583.
- Klungsoyr JA, Vagstad T, Ferle M, et al. The novel arthroscopic subscapular quadriceps tendon-bone sling procedure provides increased stability in shoulder cadavers with severe glenoid bone loss. *Knee Surg Sports Traumatol Arthrosc* 2021;29:170-180.