

Applying Unsterile Microporous Tape onto Surgical Wounds: Tape Contamination and Clinical Rationale

Kjersti Ausen, MD, PhD*†
 Marthe L. Kroknes, MSc‡
 Gudjon Gunnarson, MD§
 Andreas Radtke, MD, PhD¶**

Background: Fomites are surfaces that carry contaminants and may cause infection. We wanted to assess the bacterial load on rolls of nonsterile microporous tape in a hospital setting and explore the scientific rationale behind the existing practice of applying unsterile adhesives onto a surgical wound.

Methods: We analyzed the aerobic bacterial contamination in rolls of microporous tape collected from surgical theaters, outpatient clinics, and storage rooms at St. Olav's University Hospital, Trondheim, Norway between 2018 and 2020. We also reviewed the literature for relevant publications.

Results: A total of 58 rolls were collected; 55 were included for final analysis. Exposed tape surfaces were significantly more contaminated than unexposed surfaces. Tape rolls from outpatient clinics were significantly more contaminated and contained a significantly greater variety of microbes than rolls from operation theaters and storage rooms. Unexposed surfaces from both operation theaters and storage rooms demonstrated very little contamination.

Conclusions: Rolls of tape may act as fomites, but widespread use of adhesives is inevitable in hospital settings. Removing the outer layer of a tape roll before use may significantly reduce bacterial contamination. Given sufficient vigilance to avoid cross-contamination, inner layers of tape may represent a close-to-sterile alternative as surgical dressing. However, the economic savings constitute a negligible fraction of the total costs of the surgery, and the risk of contamination seems apparent. Scientific support of dressing a fresh surgical wound with unsterile microporous tape is lacking, and we therefore do not recommend the practice except in situations with very limited resources. (*Plast Reconstr Surg Glob Open* 2021;9:e3635; doi: 10.1097/GOX.0000000000003635; Published online 15 June 2021.)

INTRODUCTION

Nonsterile microporous tape is commonly available in operating theatres and is not uncommonly applied

directly onto surgical wounds in an otherwise sterile field. When questioned, surgeons often claim that this is an established practice, never causing any problems, sometimes adding that they take precaution not to use the first revolution of the tape.

Nosocomial infections can be induced by fomites—surfaces which carry contaminants—and rolls of tape can act as fomites in a hospital setting.^{1–3} The purpose of this study was to assess the bacterial load on rolls of adhesive tape readily available in operating theatres and the corresponding outpatient clinics in a single hospital surgical practice, and to explore existing literature for the rationale behind the application of unsterile adhesives onto a surgical wound.

From *Section for Plastic and Reconstructive Surgery, Clinic of Surgery, St Olav's University Hospital, Trondheim, Norway; †Department of Circulation and Medical Imaging, Norwegian University of Science and Technology – NTNU, Trondheim, Norway; ‡Department of Medical Microbiology, St Olav's University Hospital, Trondheim, Norway; §Section for Plastic and Reconstructive Surgery, Sorlandet Hospital, Kristiansand, Norway; ¶Unit of Infection Control, St Olav's University Hospital, Trondheim, Norway; and **Department of Clinical and Molecular Medicine, Norwegian University of Science and Technology - NTNU, Trondheim, Norway.

Received for publication February 21, 2021; accepted April 21, 2021.

Copyright © 2021 The Authors. Published by Wolters Kluwer Health, Inc. on behalf of The American Society of Plastic Surgeons. This is an open-access article distributed under the terms of the [Creative Commons Attribution-Non Commercial-No Derivatives License 4.0 \(CCBY-NC-ND\)](https://creativecommons.org/licenses/by-nc-nd/4.0/), where it is permissible to download and share the work provided it is properly cited. The work cannot be changed in any way or used commercially without permission from the journal.

DOI: 10.1097/GOX.0000000000003635

Disclosure: All the authors have no financial interest in relation to the content of this article. This study has been financed by St Olav's University Hospital and the Liaison Committee between the Central Norway Regional Health Authority and the Norwegian University of Science and Technology – NTNU.

Related Digital Media are available in the full-text version of the article on www.PRSGlobalOpen.com.

Scientific Rationale behind Unsterile Surgical Adhesives

Sutureless closure of surgical excisions was initially promoted in the 1950s, as Gillman et al⁴ demonstrated the epithelial downgrowth that occurs along sutures, resulting in unsightly scarring. Elek and Conen⁵ showed that the multiple skin penetrations of suturing and the presence of foreign material increased the risk of wound infection. Gillman subsequently promoted the closure of surgical wounds with regular tape from the local stationary store, claiming that as this tape contained both phenol and latex, it was virtually self-sterilizing, and that no infections were observed.⁶

Adhesive bandaging materials have been used throughout medical history but have been associated with skin irritation and hypersensitivity reactions.⁷ The Minnesota, Mining and Manufacturing Company (3M) succeeded in the mid-1950s in developing a well-tolerated hypoallergenic acrylate adhesive,⁷ which in combination with a microporous nonwoven layer of rayon fibers led to the introduction of the microporous adhesive surgical tape. Enthusiastic reports followed in the early 1960s.⁸⁻¹³ Microporous tape gained popularity because its structure allows sufficient moisture to evaporate to create a favorable microenvironment for the skin, with less bacterial proliferation than under occlusive barriers.^{14,15} Its elastic yet adhesive properties even when moistened makes it well tolerated by most patients and provides strength without blistering.⁷ Several publications also suggested a decrease in wound infections when using tape instead of sutures for outer layer closure particularly in contaminated wounds,^{16,17} but organic suture material at the time was associated with more infection than synthetic suture material.¹⁸

Microporous tape has stood the test of time and comes in both sterile versions (adhesive strips, 3M Steri-Strips) and unsterile versions (tape rolls, 3M Micropore). The use of 3M Steri-Strips for superficial wound closure has been widely published.¹⁹ The tape has somewhat more elastic properties than the strips, and may therefore convey less shearing forces onto the skin.¹⁵ Publications have demonstrated good results from using microporous tape in addition to—or even instead of—subcuticular suturing,^{8,10,16,20-22} but these studies all used a sterile version of microporous tape. Taube et al²² reports “...this method of skin closure has many advantages. However, the combination is not used widely, perhaps because sterile Micropore has not hitherto been made available by the manufacturers.” Several authors provided practical tips on how to sterilize surgical tape,^{7,22,23} while Berkowitz² pointed out that adhesive tape could be a potential source of nosocomial bacteria.

Bundy²⁴ proposed the use of pre-packaged unsterile surgical tape as a safer and cheaper means of wound closure, documenting close-to-sterility quality in prepacked clean rolls of tape. Bundy also documented that surgical tapes shelved in surgical suite cabinets for 2 weeks had considerable contamination of their exposed dry surface, but the unexposed adhesive surface and the unexposed dry surface after unwinding had virtually no contamination. Redelmeier et al²⁵ and Harris et al³ also collected

tape rolls from various hospital locations, confirming that rolls used for catheter fixation contained microbes likely to contribute to catheter infections. Redelmeier also demonstrated that removing the outer exposed layer of the tape roll significantly reduced the bacterial burden and that the inner layer only sporadically contained bacteria, which was in accordance with Bundy’s findings. Bundy stated that “Wound closure in this manner would benefit the patient in the field, in the emergency room, or in third world countries where the supply of sterile tape is limited.”

In a comment to the article by Bundy et al,²⁴ Krupp²⁶ stated that “We have been using unsterilized surgical adhesive tape such as Micropore or Mefix for covering clean surgical wounds, sutured or stapled, for about 20 years with excellent results. In no single case has the unsterilized tape covering the fresh surgical wound ever provoked an infection.”

Very few good scientific articles are available on potentially increased risk of infection when applying unsterile dressings onto a surgical wound. Shanahan et al²⁷ published a randomized prospective material in 410 patients where nonsterile microporous tape was compared with sterile tape (Micropore 3M versus Steri-Strips) for closure on top of subcuticular sutures. They found no difference in wound infections but claimed significantly lower cost when using nonsterile microporous tape. However, they applied tincture of benzoin onto the wound and let it dry before tape application. Tincture of benzoin is an old and widely used skin seal antiseptic agent that provides an antiseptic barrier between the surgical wound and the unsterile tape. Application of a wound sealant or antiseptic film onto the wound surface decreases the risk of infection when applying nonsterile tape, and Shanahan also argues why the pretreatment of the wound with tincture of benzoin accelerates wound sealing and may negate the necessity of sterilization. Shanahan concludes that “the use of unsterile Micropore tape on surgical wounds has no disadvantages over conventional dressings.” Because neither headline nor conclusion mentions that the unsterile tape is applied on top of an antiseptic sealant, it is easy to miss this important aspect of Shanahan’s method.

In a recent retrospective analysis of 1216 cosmetic breast surgery patients, Hever et al²⁸ suggested no difference between the use of Micropore tape and other conventional wound dressings in the prevalence of post-operative wound healing problems in cosmetic breast surgery. Hever states that “evidence suggests that the use of Micropore TM tape as a dressing for surgical incisions may be associated with reduced/comparable rates of infection in surgical wounds.” They also suggest that introduction of Micropore as inner dressing may “have significant cost implications, both in terms of reducing the costs associated with the dressing of surgical wounds, and costs associated with managing infective complications.” Hever, however, links the claimed evidence of reduced rates of infection to an article by Lipscombe and Juma,²⁹ who applied unsterile versus sterile microporous tape onto disinfected but intact skin in volunteers and merely measured the bacterial growth underneath the tapes at 1 week after application. The fact that that microporous tapes provide favorable

microenvironments with less bacterial proliferation than occlusive barriers has been well documented.^{14,15} As the retrospective analysis by Hever compared microporous tape to nonmicroporous dressings, a comparison between unsterile versus sterile microporous dressing is still lacking.

METHODS

This was a descriptive single-blinded study conducted from 2018 to 2020 in collaboration with the Unit of Infection Control at St. Olav's University Hospital, Trondheim, Norway. A total of 48 rolls of microporous tape were collected on eight separate occasions at least two months apart from surgical theatres, outpatient clinics, and storage rooms in a department with combined plastic, hand, and orthopedic surgical activity. Another 10 rolls were also collected from 10 different operating theatres at four other surgical units in the same hospital.

Collection was done as unexpected visits during operations or outpatient consultations, stating "if surgeons asked for microporous tape, what would they get?" The investigator put on a sterile glove, took the roll offered, and inverted the glove back over the roll. 3M Micropore surgical tape 1-inch width is the standard microporous tape in the hospital; if a location failed to have Micropore available, 3M Transpore surgical tape 1-inch width was collected instead. The time, date, and location of each roll was registered. Control rolls were collected directly from storage rooms using the same procedure with a sterile glove and avoiding contact with neighboring surfaces. Neither Micropore nor Transpore come in individual wrappings; they are delivered and stored in boxes of 25 rolls each. All rolls were transported to the laboratory for further processing within a maximum of 2 hours.

Microbiological Culturing

The following areas were investigated in all tape rolls (Fig. 1): the exposed outer surface of the first revolution of tape (area A), the exposed sides of the roll (area B), and the adhesive (unexposed) surface of the first revolution of tape (area C). During the last 4 collections, the outer (unexposed) surface of the second revolution of tape (area D) was also investigated.

An investigator blinded to the origin of the tape rolls performed the microbiological analyses. Culturing procedure was adapted from the method described by Berkowitz et al² (See appendix, Supplemental Digital Content 1 for details on culturing and reading. <http://links.lww.com/PRSGO/B677>.) Briefly, culturing was done within 3 hours of collection on blood agar petri dishes. Each of the 4 defined surfaces were pressed or rolled onto the agar plates (Fig. 2). Incubation took place at $35 \pm 2^\circ\text{C}$ for 48 hours and in room temperature for 24 hours. Macroscopic counting of colony forming units (CFU) was performed after 72 hours. Only aerobic bacterial contamination was investigated.

Statistics

Number of CFU were noted separately for the 4 defined areas of tape (Fig. 1) and results stratified according to collection site. Results are presented both as mean

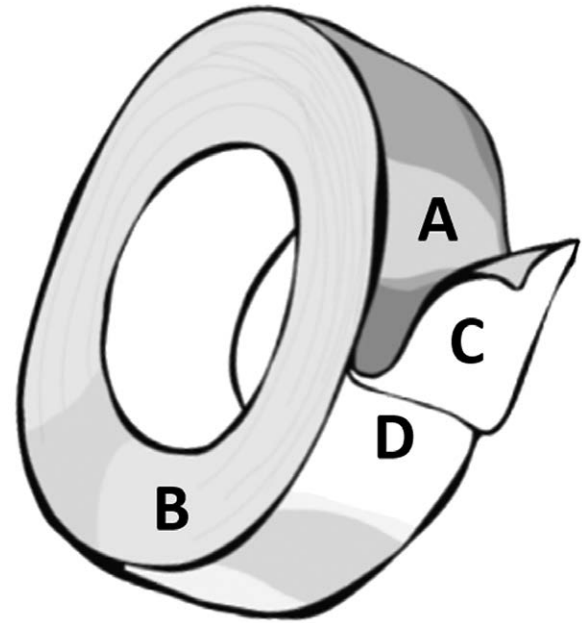


Fig. 1. Surface areas investigated for contaminants. A, Outer surface of first revolution of tape (exposed). B, Sides of the roll of tape (exposed). C, Inner surface of first revolution of tape (unexposed). D, Outer surface of second revolution of tape (unexposed).

\pm SD (SD) and as median (range). Overgrowth as defined by >100 CFU is registered as "100." Number of CFU is compared between and within rolls using nonparametric independent or dependent samples tests, as appropriate (Kruskal–Wallis and Wilcoxon's Signed Rank test).

Literature Search

With the aid of a university librarian, we searched MEDLINE, Embase, and the Cochrane Library for relevant articles. We also reviewed the reference lists of relevant articles.

RESULTS

A total of 58 rolls were collected. Three rolls were discarded after analysis due to contamination after collection or processing error, and the remaining 55 rolls were included for final analyses. A full account of all tape rolls and the microbiological findings are supplied in Supplemental Digital Content 2. (See table, Supplemental Digital Content 2, which displays aerobic bacterial contamination of rolls of microporous tape, detailed data. <http://links.lww.com/PRSGO/B678>.)

Tape rolls from outpatient examination rooms were significantly more contaminated and contained a significantly greater variety of microbes than rolls from operation theaters and storage rooms (Fig. 3, Tables 1 and 2) ($P=0.001$). There was a trend toward more contamination on rolls collected from operation theaters than from storage rooms, but the difference did not reach significance. Exposed surfaces (areas A and B, Fig. 1) were significantly more contaminated than unexposed surfaces (areas C and D) both in outpatient ($P<0.001$) and surgical theater settings ($P=0.002$). In outpatient examination rooms, the

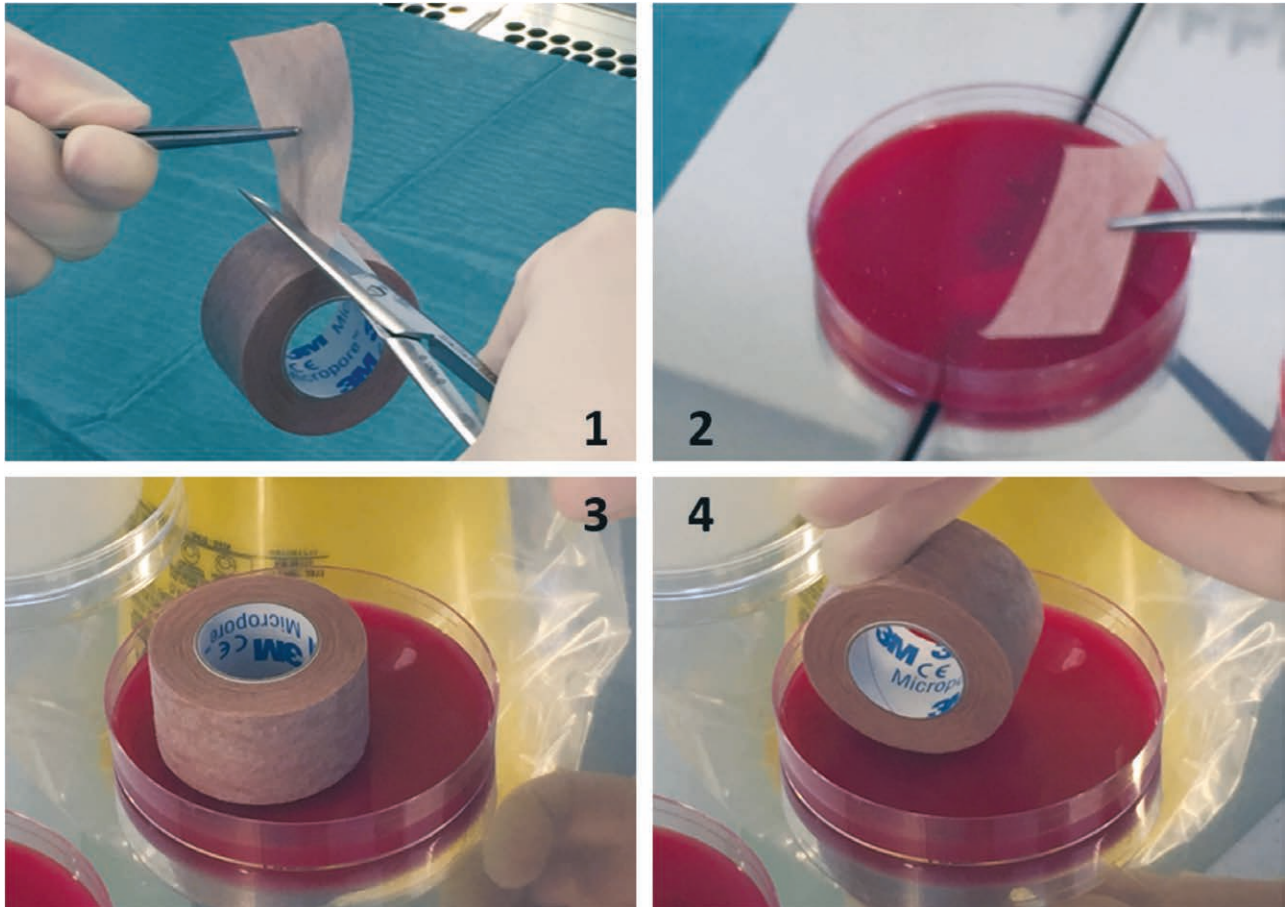


Fig. 2. 1: The first part of the first revolution of tape was cut for analysis of its outer and inner surface. Extra tape was removed to ensure that the entire first revolution was removed. 2: Both sides of the first part of tape were pressed onto a petri dish, representing areas A and C in Figure 1. 3: The side of the tape roll was pressed onto a petri dish, representing area B in Figure 1. 4: Finally, the newly exposed second revolution of tape was rolled onto a petri dish, representing area D in Figure 1.

unexposed sticky surface of the first revolution of tape (area C) was also generally contaminated, albeit significantly less than the exposed surface ($P < 0.001$). However, the contamination of outpatient tape rolls became significantly lower after discarding the first revolution of tape (Fig. 1, significantly less contamination of D compared with C, $P = 0.016$). Unexposed surfaces from both operation theaters and storage rooms demonstrated very little contamination (Table 1).

Table 2 lists the microbes found in the different locations. Predominantly the bacteria found were either skin commensal bacteria like coagulase-negative Staphylococci or Micrococcus species, or represented typical environmental species like Bacillus. However, pathogenic bacteria were also found such as *Staphylococcus aureus* and *Enterobacter cloacae*.

DISCUSSION

Our study has several limitations. It is a merely descriptive single hospital study and does not aim to address any association between contaminated surgical tape and wound infection. The contamination of a tape roll does not equal surgical wound contamination or infection

although it might pose such a risk. The real contamination of any given tape roll may vary significantly according to handling routines, location, time, date and patient population, and we have not collected enough samples to correct for possible effect-modifying variables. We have also only analyzed aerobic bacteria and no other pathogens.

Our findings confirm that rolls of tape may act as fomites. Our findings also suggest that with sufficient vigilance, ensuring that the contaminated outer revolution is discarded without concurrent contamination of the surgical field or the newly exposed tape, the inner revolutions of a roll of tape may represent a close-to-sterile alternative as a surgical dressing. Both findings are supported by previous studies.^{3,24,25}

We have not been able to identify any prospective randomized studies comparing nonsterile versus sterile microporous dressings onto raw surgical wounds without a primary wound sealant or antiseptic barrier. Only sporadic case reports of surgical infections attributed to contaminated adhesives have been published.^{30,31} The lack of scientifically demonstrated hard endpoints such as wound infection may however be due to lack of proper studies in susceptible populations. Cosmetic breast surgery patients in the population investigated by Hever et al²⁸ are generally

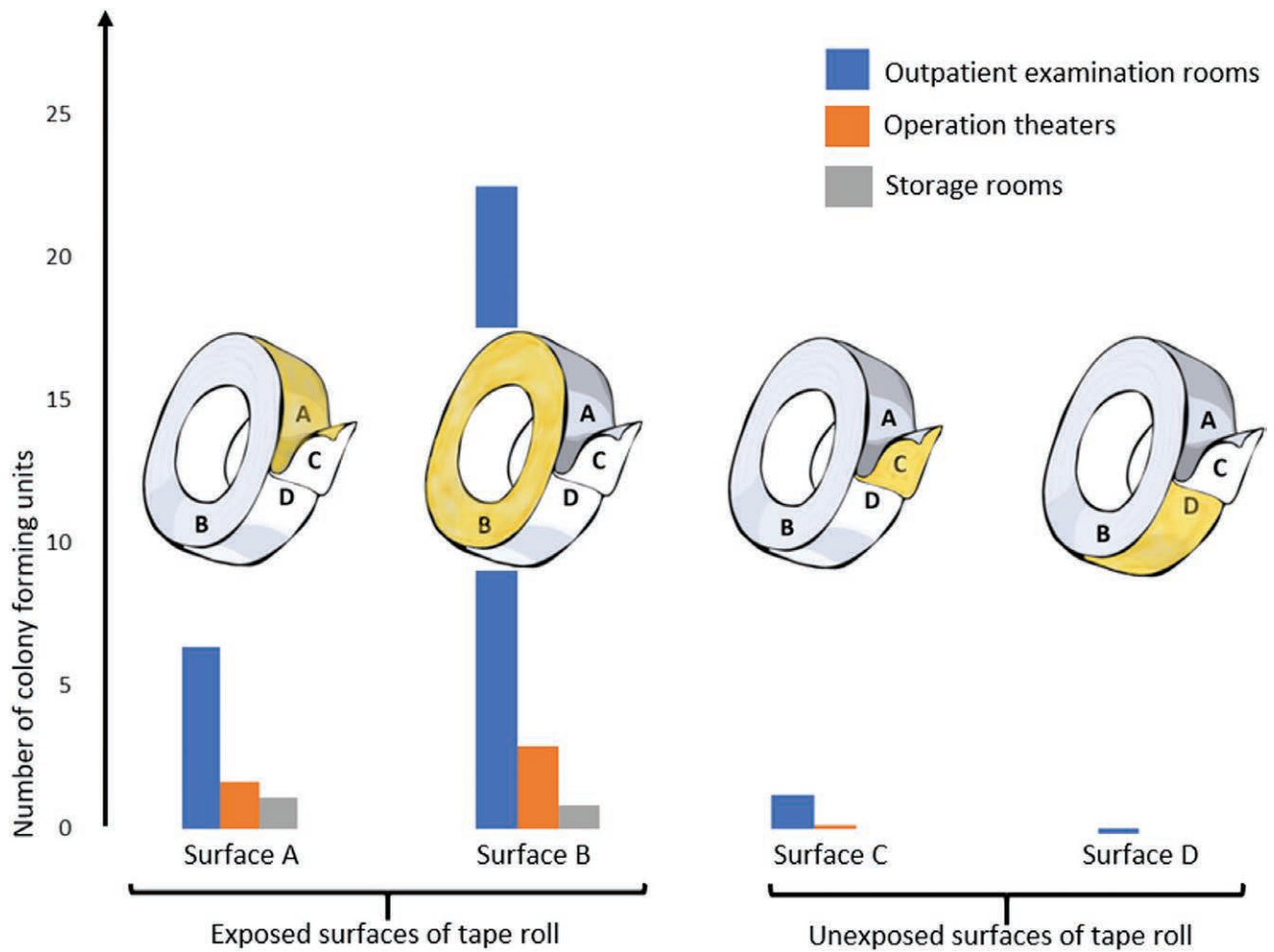


Fig. 3. Number of colony forming units on the different surfaces of microporous tape according to collection site.

Table 1. Aerobic Bacterial Contamination of Rolls of Microporous Tape

	Outpatient Examination Rooms (n = 22 rolls)	Operation Theaters (n = 21 rolls)	Storage Rooms (n = 12 rolls)
Colony forming units (n)			
Total per roll			
Mean ± SD	29.5 ± 26.6	4.6 ± 6.6	1.9 ± 2.2
Median (range)	23.5 (2 to >100)	3 (0 to 32)	1 (0 to 6)
Exposed surfaces			
Area A			
Mean ± SD	6.4 ± 5.0	1.6 ± 3.2	1.1 ± 1.4
Median (range)	6 (0 to 14)	1 (0 to 15)	0.5 (0 to 4)
Area B			
Mean ± SD	22.5 ± 27.1	2.9 ± 3.7	0.8 ± 0.9
Median (range)	14.5 (0 to >100)	2 (0 to 17)	0.5 (0 to 2)
Unexposed surfaces			
Area C			
Mean ± SD	1.2 ± 1.3	0.1 ± 0.4	None
Median (range)	1 (0 to 4)	0 (0 to 1)	None
Area D			
Mean ± SD	0.2 ± 0.6	None	None
Median (range)	0 (0 to 2)	None	None
No. different species per roll			
Mean ± SD	3.6 ± 1.3	1.7 ± 0.9	1.1 ± 1.2
Median (range)	3.5 (2 to 6)	1.5 (0 to 3)	1 (0 to 3)

Table 2. Identified Aerobic Microbes on Rolls of Microporous Tape

Outpatient Examination Rooms 22 Tape Rolls	No*	Operation Theaters 21 Tape Rolls	No*
<i>Abiotrophia defectiva</i>	1	<i>Bacillus firmus</i>	1
<i>Acinetobacter radioresistens</i>	1	<i>Bacillus flexus</i>	2
<i>Bacillus circulans</i>	1	<i>Bacillus licheniformis</i>	1
<i>Bacillus halosaccarovorans</i>	2	<i>Kocuria rhizophila</i>	1
<i>Bacillus infantis</i>	2	<i>Micrococcus luteus</i>	11
<i>Bacillus licheniformis</i>	3	<i>Paenibacillus pasadenensis</i>	1
<i>Bacillus megaterium</i>	1	<i>Paenibacillus residui</i>	1
<i>Bacillus simplex</i>	3	<i>Pantoea species</i>	1
<i>Bacillus thermoamulovorans</i>	1	<i>Staphylococcus capitis</i>	3
<i>Corynebacterium freneyi</i>	1	<i>Staphylococcus epidermidis</i>	7
<i>Corynebacterium pseudodiphtheriticum</i>	1	<i>Staphylococcus hominis</i>	3
<i>Dermacoccus nishinomiyaensis</i>	1	<i>Staphylococcus pasteurii</i>	1
<i>Enterobacter cloacae</i>	1	<i>Staphylococcus warneri</i>	1
<i>Micrococcus luteus</i>	21	<i>Streptococcus parasanguinis</i>	1
<i>Micrococcus lylae</i>	1		
<i>Moxarella osloensis</i>	4		
<i>Oerskovia turbata</i>	1		
<i>Paenibacillus glucanolyticus</i>	1		
<i>Paenibacillus timonensis</i>	1		
<i>Paracoccus yeii</i>	1		
<i>Rothia dentocariosa</i>	1		
<i>Staphylococcus aureus</i>	4		
<i>Staphylococcus capitis</i>	4		
<i>Staphylococcus caprae</i>	1		
<i>Staphylococcus cohnii</i>	1		
<i>Staphylococcus epidermidis</i>	11		
<i>Staphylococcus hominis</i>	5		
<i>Staphylococcus pettencoferi</i>	1		
<i>Streptococcus mitis</i>	1		
<i>Turicella otitidis</i>	1		
		Storage Rooms 12 Tape Rolls	No*
		<i>Bacillus amyloliquefaciens</i> ssp <i>plantarum</i>	2
		<i>Bacillus halosaccovorans</i>	1
		<i>Bacillus infantis</i>	1
		<i>Bacillus licheniformis</i>	1
		<i>Bacillus simplex</i>	2
		<i>Micrococcus luteus</i>	2
		<i>Bacillus halosaccovorans</i>	1

*The number of rolls of tape on which the microbe was identified.

young and healthy, and a higher bacterial inoculum is tolerated, given good host defenses. The more fragile population of a general hospital may react differently. Wilcox et al³² reported in 1999 that a 5-year *Staphylococcus aureus*-outbreak at a neonatal unit was traced to shared use of an adhesive product, and Lalayanni³³ published an outbreak of *Rhizopus oryzae* associated with adhesive tapes to stabilize IV catheters in hematological neutropenic patients.

Hever²⁸ proposes “a large-scale, randomized control trial to compare the use of Micropore tape versus conventional wound dressings for the routine dressing of surgical wounds in elective surgery.” The feasibility of such a study is questionable. Ethical approval for use of unsterile bandages in surgery may not be obtained except for settings with very limited resources. Moreover, such a study needs a vast number of participants. The incident of surgical wound infection varies according to procedure; from <1% in orthopedic joint replacement surgery to 10% in gastrointestinal surgery,³⁴ and only a small fraction of the infections are likely to be attributable to the choice of dressing, given that the dressings are clean and not heavily contaminated. Moreover, unsterile wound dressings would most likely mainly cause superficial wound infections, which are often not reported or treated by the general practitioner. If unsterile wound dressings as practiced by Hever et al were to increase the risk of infection by 50%, assuming baseline risk given sterile dressings is 3% and thus risk with unsterile dressings being 4.5%, a randomized study needs 2500 participants in each group.³⁵

Ensuring the sterility of the innermost layer of the wound dressing would seem logical when the principles of sterility are otherwise applied in a surgical field. Outer

layers of tape were consistently contaminated, while the inner layer of tape rolls seemed to carry exceedingly fewer bacterial colonies. Routine discarding of the first revolution of a tape roll stored under nonaseptic conditions should therefore be encouraged. However, vigilance and strict procedure is needed to ensure no cross-contamination between outer and inner layers when passing the tape from outside a surgical field and to the surgeon. The documented lack of bacteria in inner layers is from a laboratory setting where cutting and handling of the pieces of tape was done within strict sterility. It is the authors’ opinion from personal observations that unscrubbed personnel are less prone to adhere to optimal procedure when handling the roll of tape, and the risk of passing the outer contaminants to the inner layers is considerable.

Heavily contaminated outer surfaces of tape rolls may be a sign of a more contaminated environment in general. This notion may be supported by our observation of more contaminated tapes in outpatient settings, where consultation rooms may be used both for minor surgery and for wound dressing changes. Our findings underscore the importance of maintaining antiseptic conditions when conducting minor surgery in such locations.

Bundy claimed in 1988 that sterile tape was 5600% more expensive than unsterile tape, while Shanahan claimed in 1990 that switching to unsterile microporous tape as dressing would “in a region of 8 million total population represent a saving of £1 million per annum,” without demonstrating the calculation. If the only argument for using unsterile versus sterile microporous tape is cost, absolute price should be presented in addition to relative price. Today, a roll of 10 meters of Micropore tape

costs less than \$1, a package of six 7.5 cm Steri-Strips costs \$1–2. Thus, 1 meter of Micropore tape (given that little is wasted) costs approximately \$0.1, while 1 meter of Steri-Strips (1.5 packages) costs \$4. This can be presented as a 4000% relative increase in expense. However, the absolute cost of the one to two packages of steri-strips needed to ensure a sterile coverage of most surgical wounds is \$1–4. Mean cost of care in an operating room was recently estimated to be approximately \$36 per minute.³⁶

CONCLUSIONS

Widespread use of adhesive tape is inevitable in a hospital setting, as catheters, tubes, IV-lines, and bandages need securing. Health personnel should therefore be aware that removing the outer layer of a tape roll before use appears to significantly reduce bacterial contamination. Hospitals may also consider introducing single use tape rolls. We do feel that there is enough evidence to question the ongoing practice of dressing a fresh surgical wound with unsterile microporous tape, except in situations with very limited resources. The economic savings when unsterile versus sterile microporous tapes are used constitute a negligible fraction of the total costs of the surgery, and the risk of contamination seems apparent.

Kjersti Ausen, MD, PhD

Section for Plastic and Reconstructive Surgery
Clinic of Surgery, St Olav's University Hospital
PO Box 3250 Torgarden
N-7006 Trondheim, Norway
E-mail: kjerstiausen@gmail.com

ACKNOWLEDGMENT

The authors thank Sindre Andre Pedersen at the Norwegian University of Science and Technology – NTNU University Library for extensive assistance with the literature searches

REFERENCES

- Bauer E, Densen P. Infections from contaminated elastoplast. *N Engl J Med*. 1979;300:370.
- Berkowitz DM, Lee WS, Pazin GJ, et al. Adhesive tape: potential source of nosocomial bacteria. *Appl Microbiol*. 1974;28:651–654.
- Harris PN, Ashhurst-Smith C, Berenger SJ, et al. Adhesive tape in the health care setting: another high-risk fomite? *Med J Aust*. 2012;196:34.
- Gillman T, Penn J, Bronks D, et al. A re-examination of certain aspects of the histogenesis of the healing of cutaneous wounds; a preliminary report. *Br J Surg*. 1955;43:141–153.
- Elek SD, Conen PE. The virulence of *Staphylococcus pyogenes* for man; a study of the problems of wound infection. *Br J Exp Pathol*. 1957;38:573–586.
- Gillman T, Penn J, Bronks D, et al. Closure of wounds and incisions with adhesive tape. *Lancet*. 1955;269:945–946.
- Golden T. Non-irritating, multipurpose surgical adhesive tape. *Am J Surg*. 1960;100:789–796.
- Bonnar J, Low RA. Closure of surgical wounds of the lower abdomen by microporous tape. *Lancet*. 1968;1:1387–1389.
- Gibson EW, Poate WJ. The use of adhesive surgical tape in plastic surgery. *Br J Plast Surg*. 1964;17:265–270.
- Murray PJ. Closure of skin wounds with adhesive tape. preliminary report based on use of tape in 100 surgical cases. *Br Med J*. 1963;2:1030–1031.
- Rothnie NG, Taylor GW. Sutureless skin closure. a clinical trial. *Br Med J*. 1963;2:1027–1030.
- Skoog T. Porous tape in wound closure, skin grafting and wound dressing. *Acta Chir Scand*. 1963;126:383–387.
- Weisman PA. Microporous surgical tape in wound closure and skin grafting. *Br J Plast Surg*. 1963;16:379–386.
- Marples RR, Kligman AM. Growth of bacteria under adhesive tapes. *Arch Dermatol*. 1969;99:107–110.
- Rodeheaver GT, McLane M, West L, et al. Evaluation of surgical tapes for wound closure. *J Surg Res*. 1985;39:251–257.
- Conolly WB, Hunt TK, Zederfeldt B, et al. Clinical comparison of surgical wounds closed by suture and adhesive tapes. *Am J Surg*. 1969;117:318–322.
- Edlich RF, Tsung MS, Rogers W, et al. Studies in management of the contaminated wound. I. Technique of closure of such wounds together with a note on a reproducible experimental model. *J Surg Res*. 1968;8:585–592.
- Alexander JW, Kaplan JZ, Altemeier WA. Role of suture materials in the development of wound infection. *Ann Surg*. 1967;165:192–199.
- Gkegkes ID, Mavros MN, Alexiou VG, et al. Adhesive strips for the closure of surgical incisional sites: a systematic review and meta-analysis. *Surg Innov*. 2012;19:145–155.
- Kolt JD. Use of adhesive surgical tape with the absorbable continuous subcuticular suture. *ANZ J Surg*. 2003;73:626–629.
- Luckraz H, Rammohan KS, Phillips M, et al. Is adhesive paper-tape closure of video assisted thoracoscopic port-sites safe? *Eur J Cardiothorac Surg*. 2007;32:167–168.
- Taube M, Porter RJ, Lord PH. A combination of subcuticular suture and sterile Micropore tape compared with conventional interrupted sutures for skin closure. A controlled trial. *Ann R Coll Surg Engl*. 1983;65:164–167.
- Lord M. Day case surgery. *Proc R Soc Med*. 1974;67:998–1000.
- Bundy AT. Sterility in unsterilized surgical adhesive tape. *Plast Reconstr Surg*. 1989;83:880–883.
- Redelmeier DA, Livesley NJ. Adhesive tape and intravascular-catheter-associated infections. *J Gen Intern Med*. 1999;14:373–375.
- Krupp S. Sterility in unsterilized surgical adhesive tape. *Plast Reconstr Surg*. 1990;85:319.
- Shanahan D, Chester J, Southam JA, et al. Micropore tape dressing: a cheap, effective alternative dressing with subcuticular sutures. *Ann R Coll Surg Engl*. 1990;72:206.
- Hever P, Cavale N, Pasha T. A retrospective comparison of 3M Micropore with other common dressings in cosmetic breast surgery. *J Plast Reconstr Aesthet Surg*. 2019;72:424–426.
- Lipscombe S, Juma A. Bacterial growth on adhesive dressing tapes used for the closure of surgical wounds. *Eur J Plast Surg*. 2007;29:217–220.
- Everett ED, Pearson S, Rogers W. Rhizopus surgical wound infection with elasticized adhesive tape dressings. *Arch Surg*. 1979;114:738–739.
- Mead JH, Lupton GP, Dillavou CL, et al. Cutaneous Rhizopus infection. Occurrence as a postoperative complication associated with an elasticized adhesive dressing. *JAMA*. 1979;242:272–274.
- Wilcox MH, Fitzgerald P, Freeman J, et al. A five year outbreak of methicillin-susceptible *Staphylococcus aureus* phage type 53,85 in a regional neonatal unit. *Epidemiol Infect*. 2000;124:37–45.
- Lalayanni C, Baliakas P, Xochelli A, et al. Outbreak of cutaneous zygomycosis associated with the use of adhesive tape in haematology patients. *J Hosp Infect*. 2012;81:213–215.
- Lamasalle L, Hunt B, Schauf M, et al. Evaluating the clinical and economic burden of healthcare-associated infections during hospitalization for surgery in France. *Epidemiol Infect*. 2013;141:2473–2482.
- UCSF Clinical & Translational Science Institute. Sample size calculators for designing clinical research. <http://www.sample-size.net/sample-size-proportions/>.
- Childers CP, Maggard-Gibbons M. Understanding costs of care in the operating room. *JAMA Surg*. 2018;153:e176233.