

# The effect of injection therapy and operation of coccydynia on the schooling and physical activity of adolescent patients

Vilhjalmur Finsen,<sup>1,3</sup> Ante Kalstad,<sup>1,3</sup> Rainer G. Knobloch<sup>1</sup>

<sup>1</sup>Department of Orthopaedic Surgery, St. Olav's University Hospital, Trondheim; <sup>2</sup>Norwegian Armed Forces Joint Medical Services, Trondheim; <sup>3</sup>Faculty of Medicine, Norwegian University of Science and Technology, NTNU, Trondheim, Norway

## Abstract

Pain while sitting is the most common complaint among patients with Coccydynia. In young patients this may seriously affect their schooling which usually involves long periods of sitting. We studied if this improved after either injection therapy or surgery. During a seven-year period 32 adolescents with a mean age of 15 (range: 11-17) years were treated in our department because of coccydynia. They were followed up with mailed questionnaires at a minimum of 12 months after treatment and 28 (88%) responded. Three were no longer attending school and were excluded. Of the remainder, 12 received only injection therapy while 13 were operated upon. Mean follow-up time was 36 (14-66) months. Eight reported absence from school during the month before treatment, but only one during the week before review ( $p < 0.01$ ). There was significant improvement in sitting during class and physical exercise at school and when engaging in general sports ( $p < 0.01$ ). We can not exclude that improvements would have occurred spontaneously, but this seems unlikely as symptoms had persisted for more than two years before treatment. We conclude that in juveniles, an additional benefit of treating coccydynia with corticosteroid injection or operative resection is that their ability to attend school and take part in sports improves significantly.

## Introduction

Pain around the lower end of the spine, particularly when sitting, is termed coccydynia. There are probably multiple causes, but many patients report a previous trauma.<sup>1-3</sup>

Both corticosteroid injections and surgery can be beneficial when coccydynia does not respond to conservative treatment.<sup>1,4-7</sup> In spite of this, there are few reports in the literature of children or youths treated in this way.<sup>8-14</sup>

While coccydynia in adolescents, as in adults, has a seriously impact on daily social activities, it also interferes with sports and, most importantly, on their education which usually involves long periods of sitting. We have previously reported on the changes after treatment in typical coccydynia symptoms among our adolescent patients.<sup>15</sup> We now present the results on symptoms related to school activities and sports.

## Materials and Methods

Three-hundred and fifty-eight (358) patients with chronic coccydynia were referred to our department during a seven-years period. A total of 43 (12%) of these were adolescents with a mean age of 15 (range: 11-17) years. There were 36 girls and seven boys.

The patients were referred to us by general practitioners and other hospitals because non-invasive treatment had failed. The diagnosis was made by a senior spinal surgical consultant (RGK) based on a thorough medical history, clinical examination and imaging with either coccygeal radiographs, MRI, or both (Figures 1 and 2).

A total of 31 (72%) had experienced a trauma and one girl had coccydynia after giving birth at the age of 15. The remaining 11 did not know the cause of their pain. If patients had been symptomatic for more than two months, the condition was regarded as chronic.

All patients with severe symptoms were initially offered a targeted injection with a mixture of lidocaine and corticosteroid. Eleven patients with mild symptoms received no treatment and were excluded from further consideration. We used a standardized method of direct injection in the most painful level of the coccyx, usually the sacrococcygeal or Co1-Co2 level, under digital intrarectal control without fluoroscopic imaging as described by Kersey<sup>16</sup> and Finsen.<sup>17</sup> Injections were repeated if they had led to passing improvement. A total of 21 had one injection, four had two injections and two had three injections. Patients who were afraid of possible injection pain and refused treatment were offered injection during a short intravenous anaesthesia.

In cases of treatment failure with

Correspondence: Vilhjalmur. Finsen, Department of Orthopaedic Surgery, St. Olav's University Hospital, 7006 Trondheim, Norway. Tel.: +47 95906336. E-mail: vilh.finsen@ntnu.no

Key words: Coccydynia; adolescents; surgery; injection; school.

Contributions: VF planned the study, analysed the data, and wrote the paper; AK planned the study, collected the data, and reviewed the manuscript; RGK planned the study, collected the data, and reviewed the manuscript.

Conflict of interest: The authors declare that no conflicts of interest.

Funding: None.

Ethics approval and consent to participate: Regional committee for medical and health research ethics in Central Norway (2016/460).

Availability of data and materials: Data and materials available in the text.

Received for publication: 6 May 2020. Accepted for publication: 20 June 2020.

This work is licensed under a Creative Commons Attribution NonCommercial 4.0 License (CC BY-NC 4.0).

©Copyright: the Author(s), 2020  
Licensee PAGEPress, Italy  
Orthopedic Reviews 2020;12:8619  
doi:10.4081/or.2020.8619

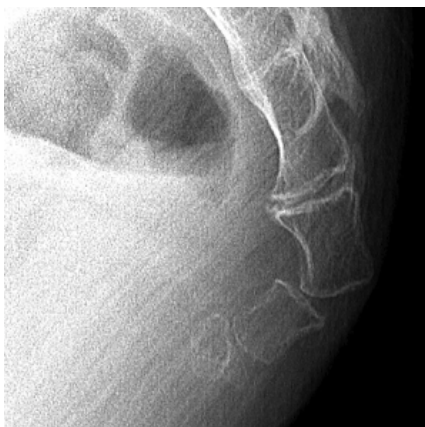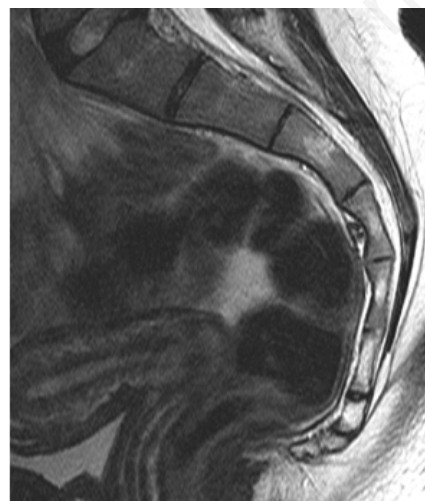
injection therapy, patients were offered surgery with a resection of the coccyx at the most proximal mobile segment, with the technique described by Key.<sup>18</sup> Surgery was performed in 12 such adolescents. In addition, there were five adolescents who were operated without previous injections.

All treated patients were followed up with mailed questionnaires at a minimum of 12 months after treatment. Patients who had not responded to the questionnaires were reminded by telephone after 6 weeks and received new questionnaires if they wished. We recorded the duration of symptoms before treatment, and the changes in pain while sitting down at school, absence from school, the frequency of having to rise from a sitting position, and pain during sports compared to before treatment. Changes in symptoms were at follow-up scored by the patients as "completely well", "much better", "somewhat better", "unchanged", or "worse".

Twenty-eight treated adolescents (88%) responded to our questionnaire. All respondents were attending school at the time of treatment, but three had left school

**Table 1. Patients' estimation at review of change from before treatment.**

	No.	No pain	Much better	Somewhat better	Unchanged	Worse
School classroom						
Only injection	10	3	1	3	3	0
Operated	11	3	3	3	1	1
All	21	6	4	6	4	1
School physical exercise						
Only injection	10	4	2	1	3	1
Operated	11	3	3	3	1	1
All	21	7	5	4	4	2
General sports						
Only injection	11	6	1	1	3	0
Operated	11	5	3	1	0	2
All	22	11	4	2	3	2

**Figure 1. Radiograph showing subluxation of Co2.****Figure 2. MRI study showing abnormal flexion of distal coccyx and fusion of Co2 to Co1.**

by the time of the review. These three patients (two injected and one operated) were excluded from the study. The remaining 25 patients constitute the index patients of the present report. They had had symptoms of coccydynia for a mean of 26 (range: 2-84) month before injection or operation.

Twelve of the index patients received only injection therapy, and had a mean follow up of 36 (18-66) months, while 13 were operated upon, with a mean follow-up of 36 (14-64) months.

The results were analysed with the chi-square test and the test for binomial distribution. The study was reviewed by the Regional committee for medical and health research ethics in Central Norway (2016/460) who found that it did not need their approval.

## Results

Eight of the 25 respondents reported that they had had days of absence from school during the month before treatment, but only one that this had been the case during the month before review ( $p < 0.01$ ). Eleven reported that they still had to rise from a sitting position one or more times during a typical 45-minute class. None had a modified chair at school.

The number of patients who felt that they were better than before treatment with regard to classroom activities and physical exercise at school and when engaging in general sports were statistically significantly greater than those who felt they were worse ( $p < 0.01$ ; Table 1).

## Discussion

We reported in our previous paper that the improvement when treating juveniles for coccydynia with injections or operation are similar to those obtained when treating adults.<sup>15</sup> The present study indicates that such treatment is also beneficial with regard to school activities and sports. We have been unable to find previous papers studying this question.

The main weakness of our study is that it is not randomized. This would be very difficult to achieve. The main strength of the study is the fairly high number of treated patients. We have found only one paper in the literature with more adolescent patients treated for coccydynia than in the present paper.<sup>19</sup> However, the authors operated on only three of them.

It may be that the improvements among our patients would have occurred spontaneously and not as a result of the treatment. This seems unlikely in our view, as symptoms had persisted for a mean of more than two years before treatment.

## Conclusions

We conclude that in juveniles, an additional benefit of treating coccydynia with corticosteroid injection or operative resection is that their ability to attend school and take part in sports improves significantly.

## References

1. Karadimas EJ, Trypsiannis G, Giannoudis PV. Surgical treatment of coccygodynia: an analytic review of the literature. *Eur Spine J* 2011;20:698–705.

2. Kwon H, Schrot R, Kerr E, Kim K. Coccygodynia and coccygectomy. *Korean J Spine* 2012;9:326–33.
3. Howard PD, Dolan AN, Falco AN, et al. A comparison of conservative interventions and their effectiveness for coccydynia: a systematic review. *J Man Manip Ther* 2013;21:213-9.
4. Fogel G, Cunningham P, Esses S. Coccygodynia: evaluation and management. *J Am Acad Orthop Surg* 2004;12:49–54.
5. Nathan ST, Fisher BE, Roberts CS. Coccydynia. *J Bone Joint Surg Br* 2010;92-B:1622-7.
6. Aarby NS, Trollegaard AM, Hellberg S. Coccygectomy can be a treatment option in chronic coccygodynia (In Danish). *Ugeskr Laeger* 2011;173:495-500.
7. Elkhatab Y, Ng, A. A Review of Current Treatment Options for Coccygodynia. *Curr Pain Headache Rep* 2018;22:28.
8. Margo E. The painful terminal spine. *South Med J* 1962;55:461-70.
9. Wray CC, Easom S, Hoskinson J. Coccydinia. *J Bone Joint Surg Br* 1991;73-B:335-8.
10. Postacchini F, Massobrio M. Idiopathic coccygodynia: analysis of fifty-one operative cases and a radiographic study of the normal coccyx. *J Bone Joint Surg Am* 1983;65:1116–24.
11. Pennekamp PH, Kraft CN, Stutz A, et al. Coccygectomy for coccygodynia: does pathogenesis matter? *J Trauma* 2005;59:1414-19.
12. Balain B, Eisenstein S, Alo GO, et al. Coccygectomy for coccygodynia: case series and review of literature. *Spine* 2006;31:414-20.
13. Sehirlioglu A, Ozturk C, Oguz E, et al. Coccygectomy in the surgical treatment of traumatic coccygodynia. *Injury* 2007;38:182–7.
14. Trollegaard AM, Aarby NS, Hellberg S. Coccygectomy: an effective treatment option for chronic coccydynia: retrospective results in 41 consecutive patients. *J Bone Joint Surg Br* 2010;92:242–5.
15. Kalstad AM, Knobloch RG, Finsen V. The treatment of coccydynia in adolescents. A case-control study. *Bone Joint Open* 2020;1-5:115–120.
16. Kersey PJ. Non-operative management of coccygodynia. *Lancet* 1980;1:318.
17. Finsen V. Corticosteroid injection for coccygodynia (In Norwegian). *Tidsskr Nor Legeforen* 2001;121:2832–3.
18. Key A. Operative treatment of coccygodynia. *J Bone Joint Surg* 1937; 19:759–64.
19. Maigne JY, Pigeau I, Aguer N, et al. Chronic coccydynia in adolescents. A series of 53 patients. *Eur J Phys Rehabil Med* 2011;47:245-51.