

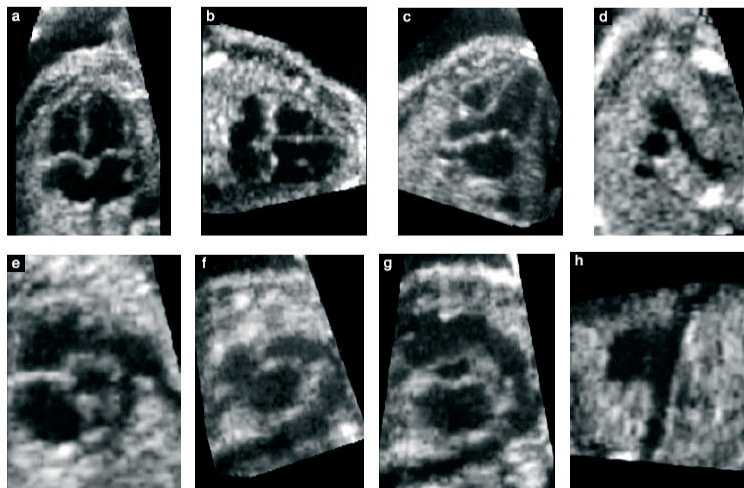
Eva Tegnander

# Detection of congenital heart defects in a non-selected population of 42,381 fetuses

Doctoral thesis  
for the degree of doctor philosophiae

Trondheim, June 2006

Norwegian University of Science and Technology  
Faculty of Medicine  
Department of Laboratory Medicine,  
Children's and Women's Health



**NTNU**

Norwegian University of Science and Technology

Doctoral thesis  
for the degree of doctor philosophiae

Faculty of Medicine  
Department of Laboratory Medicine, Children's and Women's Health

© Eva Tegnander

ISBN 82-471-7982-2 (printed version)  
ISBN 82-471-7981-4 (electronic version)  
ISSN 1503-8181

Doctoral theses at NTNU, 2006:112

Printed by NTNU-trykk

## CONTENT

ACKNOWLEDGMENTS	7
LIST OF PAPERS	9
ABBREVIATIONS	10
INTRODUCTION	11
Background	11
History of ultrasound	11
Early medical use of ultrasound	13
Ultrasound in cardiology	14
Ultrasound in obstetrics	15
Doppler ultrasound	18
Power Doppler ultrasound	20
Three- and four-dimensional ultrasound	21
Magnetic Resonance Imaging (MRI)	22
The fetal examination	23
Epidemiology of congenital heart defects	26
Incidence of CHDs	26
Fetal population versus postnatal population	27
Selected versus non-selected populations	27
Major and minor CHDs	28
The fetal heart examination	30
Teaching and training obstetric ultrasound	34
AIMS OF THE STUDIES	38
MATERIAL AND METHODS	40
Populations and study design	40
Methods	46
Classifications of congenital heart defects	46
Ultrasound equipment and computer software	47
3D imaging	47
Statistical analysis	49
RESULTS AND COMMENTS	50
Paper I	50

Paper II	53
Paper III	59
Paper IV	70
Paper V	79
SUMMARY	85
REFERENCES	89
CORRECTIONS	107
ORIGINAL PAPERS (I – V)	



## ACKNOWLEDGMENTS

This study has been carried out at the National Center for Fetal Medicine, Department of Obstetrics and Gynecology, St. Olavs Hospital, Trondheim University Hospital. I wish to express my sincere gratitude to all my colleagues and collaborators who have been involved in this project and made the thesis possible.

Many thanks to Professor Kåre Molne, for being a firm head of the Department of Gynecology from the very beginning of this study until his retirement just prior to the final part of this study.

There is no doubt that this thesis would not have been realizable without the support and necessary encouragement from the chief of the National Center for Fetal Medicine, my supervisor and friend, Professor Sturla H. Eik-Nes. His organizational and professional capability and his foresight have been beneficial for all of us working with him. As a nurse/midwife it has been encouraging to experience that my profession has been an obvious part of the research team since its beginning in 1985. Sturla's way of introducing me to the academic world and, without hesitation, giving me challenges I never thought I could meet, have been decisive for my academic involvement. Thank you, Sturla, for giving me the needed confidence that I could do this work.

My sincere thanks go to all the nurse/midwives at the National Center for Fetal Medicine. Without their persistent determination to increase their ultrasound skills and their thorough registration of data from more than 42,000 fetuses, the basis for this thesis would be absent. Their tolerance for my absent-mindedness during the most intensive writing periods is very much appreciated.

I also wish to express my thanks to my co-writers for instructive and valuable input: Dr. David T. Linker and Dr. Wendy Williams for introducing me to the complex, yet understandable, mystery of congenital heart defects; Dr. Ole Jakob Johansen for making the ascertainment of cases easier through his thorough neonatal examinations where he

detected the majority of the minor CHDs; Dr. Harm-Gerd K. Blaas, PhD, for his enthusiasm for prenatal diagnosis and his never ending search for small, important details; engineer Svein Brekke and Professor Dr. techn. Hans Torp for introducing me to the exciting technology of 3D ultrasound.

Our daily work and research could not be carried through without the valuable work of the secretaries at the National Center for Fetal Medicine. My gratitude goes to all secretaries in general, and to Christine Østerlie in particular. Christine's always positive attitude and amazing control of the data from our non-selected population have been a source of inspiration throughout the work.

My warm thanks go to Nancy Lea Eik-Nes for revising all manuscripts in such a professional and educational way that I always looked forward to learning from her corrections. Her insight into medical science has significantly improved my manuscripts. Her positive attitude and her friendship will always be greatly appreciated.

I also wish to express my gratitude to Pål Romundstad, MSc PhD, for his support when statistics needed to be discussed and checked.

Finally, my special thanks goes to my family and friends who supported and encouraged me. I am grateful for their thoughtful withdrawal during the last few years when I needed time to write – even while it made me miss them even more. My mothers phone calls “just checking if you are still alive” meant more to me than she may ever understand.

Trondheim, March 2006

Eva Tegnander

## LIST OF PAPERS

The present thesis is based on the following papers:

- I Tegnander E, Eik-Nes SH, Linker DT. Incorporating the four-chamber view of the fetal heart into the second-trimester routine fetal examination. *Ultrasound Obstet Gynecol* 1994; 4: 24–28.
- II Tegnander E, Eik-Nes SH, Johansen OJ, Linker DT. Prenatal detection of heart defects at the routine fetal examination at 18 weeks in a non-selected population. *Ultrasound Obstet Gynecol* 1995; 5: 372–380.
- III Tegnander E, Williams W, Johansen OJ, Blaas H-GK, Eik-Nes SH. Prenatal detection of heart defects in a non-selected population of 30 149 fetuses – detection rates and outcome. *Ultrasound Obstet Gynecol* 2006; 27: 252–265.
- IV Tegnander E, Eik-Nes SH. The examiner’s ultrasound experience has a significant impact on the detection rate of congenital heart defects at the second-trimester fetal examination. *Ultrasound Obstet Gynecol* (In press).
- V Brekke S, Tegnander E, Torp HG, Eik-Nes SH. Tissue Doppler (TDOG) dynamic three-dimensional ultrasound imaging of the fetal heart. *Ultrasound Obstet Gynecol* 2004; 24: 192–198.

## ABBREVIATIONS

2D	Two-dimensional
3D	Three-dimensional
A-mode	Display presentation of echo amplitude versus depth
ASD	Atrial septal defect
AVSD	Atrioventricular septal defect
BPD	Biparietal diameter
B-mode	Brightness mode (gray scale mode), display presentation of a spot brightening for each echo voltage delivered from the receiver
CHD	Congenital heart defect
CNS	Central nervous system
CRL	Crown-rump length
CW	Continuous wave
DIRV	Double inlet right ventricle
DORV	Double outlet right ventricle
HLHS	Hypoplastic left heart syndrome
IUFD	Intrauterine fetal death
IQ data	Complex demodulated radio frequency data
MHz	Megahertz
MRI	Magnetic resonance imaging
STIC	Spatio-temporal image correlation
TDOG	Tissue Doppler gated
TGA	Transposition of the great arteries
TOF	Tetralogy of Fallot
TOP	Termination of pregnancy
VSD	Ventricular septal defect

## INTRODUCTION

### Background

The aim of prenatal care has always been to prevent and alleviate maternal and fetal/newborn complications affecting the pregnancy, birth and the neonatal period. Traditionally, midwives and general practitioners have provided the basic prenatal care in Norway. Selection of high-risk pregnancies for referral to obstetric specialists has been an important part of the pregnancy care.

In 1982, a study analyzing stillbirths and neonatal deaths from five counties in Norway found that 30% of the deaths might have been avoided with provision of optimal care (Larssen *et al.* 1982). As a consequence, the Directorate of Health in Norway ordered guidelines to be developed in 1984 to ensure equal and complete prenatal care for all pregnant women in Norway (Norges offentlige utredninger, NOU 1984:17). The document outlined the organization of the pregnancy care in the future, but gave little attention to the potential of diagnostic ultrasound for future prenatal diagnosis and treatment. This laid the ground for an intense debate among obstetricians concerning the use of ultrasound in pregnancy in Norway in the following years. In 1986, a consensus conference concerning the use of ultrasound in pregnancy was organized. An implementation of one ultrasound examination at 17–18 weeks of gestation for all pregnant women in Norway was recommended (Backe and Buhaug 1986). Since then, the use of obstetric ultrasound has continuously expanded in Norway. It now represents the method of choice for diagnosis and treatment in pregnancy, and addresses the problems concerning the 30% deaths that might have been avoided with improved prenatal care (Larssen *et al.* 1982, Holt *et al.* 2000).

### History of ultrasound

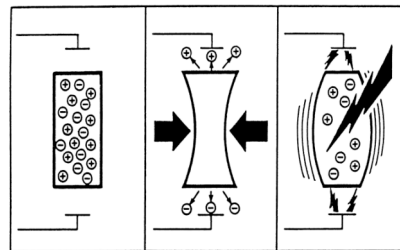
The Italian biologist Lazzaro Spallanzani demonstrated already in 1794 the ability of bats to navigate with the aid of echo reflections from high frequency inaudible sound. The scientific work towards defining the fundamental physics of sound vibrations,

transmission, propagation and refraction then followed in the centuries thereafter. This included the thesis by Lord Rayleigh from England in 1877, “The Theory of Sound”; this was the first description of a sound wave as a mathematical equation, and the foundation for future theoretical work in acoustics. For his work, Lord Rayleigh received the Nobel Prize in physics in 1904 (Woo 2005). Sir Francis Galton was able to generate high frequency sound waves in 1876 using the so-called “Galton Whistle” which he developed (Figure 1).



**Figure 1** A Galton Whistle from 1915. (<http://www.entlink.net/museum/gems2.cfm> [Accessed 18 February 2006]).


The real breakthrough for high frequency echo-sounding techniques came in 1880 when Pierre Curie and his brother Jacques Curie discovered the piezo-electric effect in certain crystals (Curie and Curie 1880) (Figure 2).



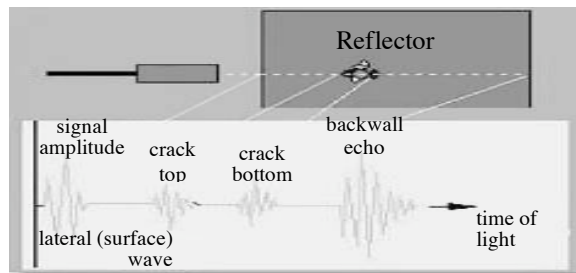
**Figure 2** The piezo-electric effect. An applied pressure converts electric voltage into ultrasound pulses and convert returning echoes back into voltages.

The Titanic tragedy in 1912 prompted research to detect underwater objects such as icebergs. The first working sonar system was designed in 1914, but was not particularly successful. World War I gave rise to new studies, as it became important to detect other underwater objects such as submarines. Among others, the French physicist Paul Langévin and the Russian scientist Constantin Chilowsky developed the hydrophone, a powerful high frequency ultrasonic echo sounding device involved in the sinking of a German submarine in the Atlantic in 1916 during World War I. Langévin’s hydrophones formed the basis of the future development of naval pulse-echo SONAR (Sound Navigation and Ranging) in the following years. Later the RADAR (Radio Detection and Ranging) system was developed, using electromagnetic waves rather than ultrasonic waves (Woo 2005).

The next important step was the development of pulse-echo ultrasonic metal flaw detectors in the 1930s (Figure 3). They were primarily constructed to check on the integrity of metal hulls of large ships and the armour plates of battle tanks (Figure 4). Together with the sonar and radar systems, the metal flaw detectors were precursors for the establishment of medical ultrasonic equipment (Woo 2005).



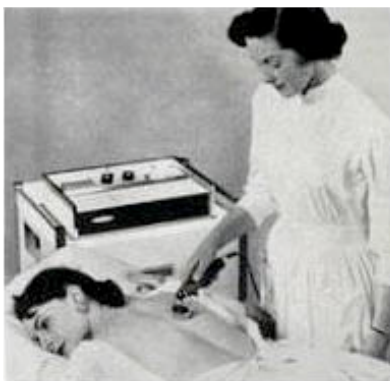**Figure 3** Metal flaw detector. Note, camera supported by a wooden log! (Edler 1961).



**Figure 4** Interruptions in the passage of sound waves are used to locate and measure flaws and cracks in solid metal (Woo 2005).

### Early medical use of ultrasound

Ultrasound is a relatively new modality within medicine and was initially used for therapy rather than diagnosis. In 1938, Raimar Pohlman, in Erlangen, Germany, demonstrated the therapeutic effects of ultrasonic waves in human tissue and introduced ultrasonic physiotherapy as a medical practice (Figures 5-7).



**Figure 5** Ultrasonic physiotherapy (Woo 2005).



**Figure 6** Ultrasonic therapy generator, the “Medi-Sonar” in the 1950s.

William Fry, University of Illinois, and Russell Meyers, University of Iowa, used ultrasound to destroy parts of the basal ganglia during craniotomies in patients with Parkinsonism. During the 1940s, ultrasound was regarded as a “cure-all” remedy, despite the lack of scientific evidence. The question of possible harmful tissue damaging started to be raised, and consequently curtailed the development of diagnostic ultrasound for a time (Woo 2005).



**Figure 7** Treatment of ulcer (Woo 2005).


Early pioneers within diagnostic ultrasound were the Austrian neurologist Karl Theodore Dussik and his brother Friederich who were the first to use ultrasound for diagnostic purposes. They studied sound attenuation in brain tissue in the early 1940s, but their method was later described as worthless. George Ludwig, a physician from USA, investigated the use of ultrasound for the detection of gallstones (outside the human body) in the late 1940s (Ludwig and Struthers 1950). John Wild and John M. Reid built the first handheld B-mode scanner for clinical use in 1951 (Baker 2005, Woo 2005).

#### Ultrasound in cardiology

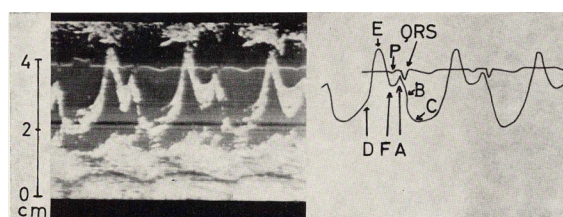
The development of ultrasound technology to be used in the field of cardiology started as a cooperation between cardiologist Inge Edler and physicist Carl Hellmuth Hertz in Lund, Sweden, in 1954 (Figure 8). In 2004 the 50<sup>th</sup> anniversary of this important scientific work in cardiology was celebrated (Olsson *et al.* 2004). This work has developed extensively and completely changed the diagnostic tools for adult cardiology. It is also the foundation for today’s fetal cardiology. Edler and Hertz utilized the metal flaw detectors as a basis for their research (Edler 1961). The need for improved diagnosis before heart surgery led Edler to look for non-invasive alternatives rather than cardiac catheterization and contrast x-rays of the heart that failed to give enough preoperative information, for example, about the mitral valve (Nilsson and Westling



2004). For the first time in October 29, 1953, Inge Edler and Carl Hellmuth Hertz managed to record pictures from the heart (Edler and Hertz 1954). With a single sound beam aimed in a fixed direction through the heart, the various echoes in this sound beam could be recorded as a function of time, the so-called M-mode (motion) registration. Later on, Edler and his colleagues realized that some of the echoes came from the anterior leaflet of the mitral valve and the characteristic motion pattern for this valve was soon established (Figure 9). Edler and Hertz's work made a decisive contribution to diagnostics in cardiology, neurosurgery and obstetrics and gynecology (Nilsson and Westling 2004).



**Figure 8** Inge Edler and Carl Hellmuth Hertz (Nilsson and Westling 2004).

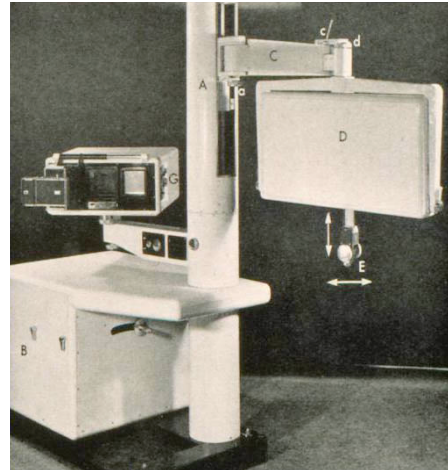


**Figure 9** Echo pattern records of the motion of the anterior leaflet of the mitral valve. Left: normal pattern, right: schematic representation in a normal case (Edler 1961).

### Ultrasound in obstetrics

Ian Donald from Scotland was the first to introduce diagnostic ultrasound to obstetrics and gynecology. His 1958 publication in the *Lancet*, "Investigation of abdominal masses by pulsed ultrasound", was the most important paper published on medical diagnostic ultrasound at that time and boosted the later clinical development (Donald *et al.* 1958). Ian Donald and his engineering group developed the Dasonograph produced by Nuclear Enterprise (Figure 10). He was the first to perform fetal head measurements and related them to age and weight (Willocks *et al.* 1964, Willocks *et al.* 1967), and the first to report sonographic evidence of a gestational sac (MacVicar and Donald 1963). Ian Donald also utilized ultrasound to study ovarian cysts, polyhydramnios and molar pregnancy (Donald *et al.* 1958, Donald 1962).

Inspired by Ian Donald, Bertil Sundén, at the University of Lund, took an early interest in obstetric and gynecological ultrasound and safety. Upon the publication of Ian Donald's work on the echoscope generating a two-dimensional display, Sundén was sent to visit and work in Donald's department in Glasgow for three weeks. As a consequence, Nuclear Enterprise sold their very first Diasonograph to the department of Obstetrics and Gynecology in Lund. Bertil Sundén's book titled "On the diagnostic value of ultrasound in obstetrics and gynecology" from 1964 was the first thesis addressing the use of ultrasonography in obstetrics and gynecology (Sundén 1964). His thesis represented pioneer work with numerous first-time observations including an anencephalic fetus diagnosed at 31 weeks of gestation.



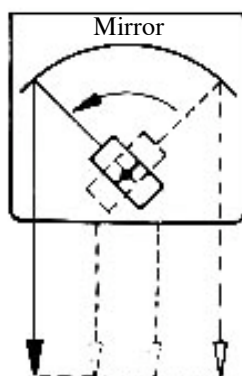
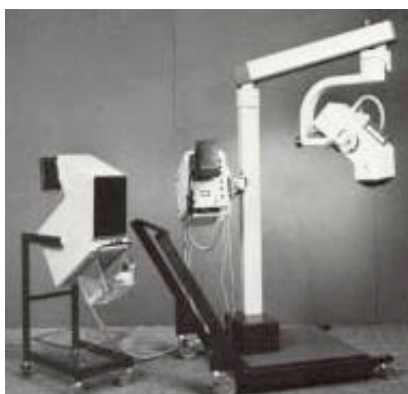**Figure 10** Disonograph – Nuclear Enterprise (Sundén 1964).

The pioneers in the development of transvaginal transducers were Hisaya Takeuchi from Japan and Alfred Kratochwil from Austria. Already in the late 1960s they reported on fetal heart pulsation in the early first trimester (Kratochwil and Eisenhut 1967, Takeuchi *et al.* 1968). Working with KretzTehnik AG in Austria, Kratochwil soon became an active user of the technique and from 1968 developed training courses in ultrasound (Woo 2005).

Until the mid-1970s, A- and B-mode scanners were used. In 1968, Stuart Campbell, in London, published his now classical paper "An improved method of fetal cephalometry by ultrasound" which immediately became a highly recognized work in which both A- and B-mode scans were used to measure the fetal biparietal diameter, today a standard measurement in fetal biometry (Campbell 1968). Utilizing a static B-scan, Campbell was the first to report on prenatal detection of an anencephalic fetus (Campbell *et al.*

1972) and a fetus with spina bifida (Campbell 1977), resulting in a termination of pregnancy. In 1975, Hugh Robinson, in Glasgow, reported on the measurement of the fetal crown-rump length; his measurement curves are still in use today (Robinson 1973). By combining A- and B-mode ultrasound, Robinson successfully demonstrated fetal cardiac action from 7 weeks onwards (Robinson and Shaw-Dunn 1973). The advent of the analog scan converter in the early 1970s and the digital scan converter in the later 1970s were among the most important innovations in ultrasound imaging (Woo 2005).

The first mechanical real-time scanner was developed in Germany by Walter Krause and Richard Soldner in the 1960s. They used a rotating transducer and a parabolic mirror, sending the sound waves parallel into the tissue (Figure 11). A wide picture in real-time sequences of more than 10 frames per second could be obtained. This technique completely changed the practice of ultrasound scanning.



**Figure 11** Videuson Siemens Medical Systems 1965, and its working mechanism.

Years of further development ensued. In 1973, one of the earliest commercial models of a linear-array real-time scanner was designed and produced by Martin H. Wilcox, the founder and engineer at the Advanced Diagnostic Research Corporation (Figure 12). In 1986, these electronic real-time scanners started to replace the static scanners.



**Figure 12** The ADR real-time scanner.

## Doppler ultrasound

The Doppler effect was first described by the Austrian physicist Christian Johann Doppler (1803–1853) in 1842. Echoes returned from moving objects have frequencies different from the frequencies sent into the body. This is called the Doppler effect. The change in frequency is called the Doppler shift, which might be used to detect and measure tissue motion, the presence or absence of blood flow and its direction, speed and character.

Figure 13 Satomura 1959.

### 超音波による末梢循環の検査法<sup>1,2)</sup>

里村茂夫 (大阪大学産業科学研究所)

(昭和34年6月29日受理)

#### Study of the Flow Patterns in Peripheral Arteries by Ultrasonics

Shigeo SATOMURA

(Institute of Scientific and Industrial Research, Osaka University)

(Received June 29, 1959)

When an ultrasonic beam is radiated into the bloodvessel by a transducer placed on the surface of the skin, the reflected waves are produced from the blood-flow.

Hence they can be detected as a kind of tone by means of a sensitive receiver.

Because the intensity and the frequency character of this tone is proportional to the velocity of the bloodflow, it is possible to investigate the behavior of the blood-flow through this method.

Tones are consisted of two kinds, one of them being produced by the carotid arterial system while the other produced by the limbs arterial system.

The author suggests to make a diagnosis of Arterial sclerosis utilizing this method.

#### §1. 緒言

血管の血流状態を検査する方法としては、古くよりマイクロフォンによって、血管から生じる音を分析する方法<sup>3-5)</sup>がある。しかし、この音に関してはあまり詳しい報告はない。その理由としてマイクロフォンによる血流音は良い S/N 比が得られないことが挙げられる。

著者の考案した方法によれば、超音波を血管内に入射することにより、血流を示す情報として、血流の速度に比例してその強さが変化し、かつその含有周波数が変化する特有の音を得ることができ、しかもその S/N 比は非常に良好である。

ゆえに動脈流についてはもちろん、末梢の静脈流についても特有の音が明瞭に検出できる。

本篇では、この装置および実施方法についてのべ、人血管についての実験および、診断学的应用について記述する。

#### §2. 実験装置および実施方法

装置のダイヤグラムを Fig. 1 に示す。主要部は高周波発振器、同受信器、超音波振動子、受話

器、記録装置よりなる。

超音波の周波数は 5 Mc とし、発振器は約 1~2 W の自励発振器、受信器は、高周波一段増幅、2 極管検波、低周波三段増幅のものを用いる。

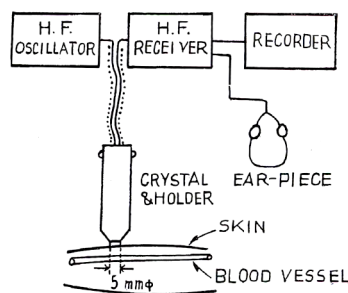



Fig. 1 Diagram of the apparatus

超音波振動子は直径 5mm のチタン酸バリウムを用い、その正電極を 2 分割して、各々を送受電極とする。

反射波検出に際しては、皮膚の上から血管に向けて超音波を入射し、低周波増幅器の出力を受話器にて聴取しながら記録器にその波形を画かせ

Of importance for the use of ultrasound technology in the diagnosis of heart defects was the development of Doppler ultrasound technology (Satomura 1957, Satomura 1959 (Figure 13), Baker *et al.* 1964, Peronneau *et al.* 1969).

In Trondheim, research on the Doppler technique started in 1973. One instrument, PEDOF, Vingmed, (Figure 14) combined the use of continuous wave ultrasound for the measurement of high velocities, such as in a stenosis, with the pulsed wave ultrasound for blood flow measurements at a pre-selected depth. This laid the foundation for the future development of ultrasound in cardiology (Brubakk *et al.* 1977, Hatle *et al.* 1978). Later, the imaging ultrasound technique and Doppler ultrasound technique were combined in the same instrument, thereby making color-flow mapping and detailed registration of velocities in selected vessels possible (Hatle *et al.* 1980, Hatle *et al.* 1981).



**Figure 14** Daisy and Pedof, Doppler unit and spectrum analyzer, Vingmed (Hatle and Angelsen 1982)

In 1977, FitzGerald and Drumm managed to register crude Doppler ultrasound signals from the human fetus in utero (Fitzgerald and Drumm 1977). A year later McCallum *et al.* (1978) presented various types of waveforms from the umbilical cord in utero. In 1979, Gill and Kossoff managed to quantify the blood flow in the umbilical vein (Gill and Kossoff 1979). Their system, however, did not allow measurements of the high velocities present in fetal arteries. In 1978, Eik-Nes *et al.* started the work that culminated in the first prototype of a Duplex transducer combining a linear array transducer and a pulsed Doppler transducer for the qualitative and quantitative measurement blood flow in fetal arteries as well as veins (Eik-Nes *et al.* 1980, Eik-Nes *et al.* 1982, Kirkinen *et al.* 1983, Eik-Nes *et al.* 1984b, Maršál *et al.* 1984).

The use of Doppler ultrasound in obstetrics emerged late in the 1970s. Further development led to 2D color flow imaging (Angelsen *et al.* 1989). With rapid interfacing of 2D and Doppler ultrasound, color-coded presentations of Doppler information superimposed on gray-scale anatomic images were possible. Appropriate colors were assigned to the display pixels depending on whether the motion was toward or away from the transducer.

Color Doppler ultrasound is considered to be a second-line investigation for cardiac evaluation and completes the evaluation of the gray-scale information (Chaoui 2001). It allows for ascertainment of homogenous flow within the heart in the great vessels to rule out heart defects and a more detailed diagnosis once heart disease is suspected. Color Doppler may also highlight areas of turbulence or of important atrioventricular valve regurgitation and for assessment of valve opening and of symmetry in ventricular filling in cases where visualization using the gray scale alone is difficult (Chaoui 2001, Gardiner 2001).

### Power Doppler ultrasound

Power Doppler displays present two-dimensional Doppler information by color-encoding the strength of the Doppler shift. This method is free of aliasing, is not angle dependent, and is more sensitive than pulsed Doppler ultrasound to slow flow and flow in small or deep vessels (Kremkau 2006). On the other hand, power Doppler does not give information about direction, speed and flow character such as turbulence.

Power Doppler ultrasound was introduced in the early 1990s and has opened up the possibility of displaying flow independently of its velocity or direction. The technique is useful when applied to fetal cardiology; it facilitates the detection of small VSDs and enables spatial orientation of the great arteries (Chaoui 2001).

## Three- and four-dimensional ultrasound

Three-dimensional ultrasound is a logical development of 2D imaging because the anatomy in reality is three-dimensional. Already in 1977, Brinkley *et al.* described a technique to generate a three-dimensional reconstruction of an organ, later applied to fetuses for weight estimation (Brinkley *et al.* 1982, Eik-Nes and Brinkley 1983). The technique described by Brinkley made possible crude 3D still-images of the fetal heart.

The heart is a moving object. In adult cardiology it is possible to synchronize (gate) the imaging of the heart movements in relation to the echocardiogram. Since this is not possible, or very difficult, in the fetus, other methods to cope with the temporal information had to be found. These methods are called “gating”. In 1996, Nelson *et al.* reported on possibilities examining the fetal heart by 3D and 4D ultrasound using a fast Fourier transform method, similar to what we today know as STIC. The same year, Deng *et al.* (1996) used real-time directed M-mode to gate the fetal heart rate and acquire and display 4D volume data sets of the fetal heart. The fetal heart rate acquired by Doppler ultrasonography (Deng *et al.* 2000, Meyer-Wittkopf *et al.* 2001, Herberg *et al.* 2005) or by cardiotocography (Herberg *et al.* 2003) has also been used to gate the spatial and temporal information. These described methods use a post processing technique. It would be of interest to find a technique that makes it possible to gate the images during the acquisition of data. In the future, it will be possible to obtain this by tissue Doppler gated technique and a 2D-array system.

The reported advantages of 3D over conventional 2D imaging are reduced scanning time, and reduced operator dependency and window dependency since the volumetric data are acquired within a few seconds from a single window. Another advantage is that access to volume data may provide information not obtainable with 2D ultrasound. In 3D ultrasound a volume of ultrasonographic data is acquired and stored, allowing the subsequent extraction of an infinite number of scan planes (Budorick and Millman 2000, Downey *et al.* 2000).

4D visualization of the fetal heart became a reality with the incorporation of STIC (spatio-temporal imaging correlation) algorithms into commercially available equipment (Gonçalves *et al.* 2005). The processing using STIC is done retrospectively.

## Magnetic Resonance Imaging (MRI)

MRI has developed to become a powerful approach to imaging CHD in infants and children (Chung 2000). The potential of MR for imaging the fetus was described in 1983 by Smith *et al.* (1983). MRI has proven to be a valuable complement to ultrasonography when additional information is needed about fetal anatomy (Levine *et al.* 1999a). Traditionally, MRI has been used to evaluate the maternal pelvic anatomy, but the fetal anatomy has been difficult to image because of fetal motion during the relatively long acquisition times (Weinreb *et al.* 1985, Powell *et al.* 1988). The development of fast MRI techniques has revolutionized the ability to image both the pregnant woman and the fetus (Levine *et al.* 1996).

Ultrasound evaluation of fetal anatomy may be limited by the nonspecific appearance of some anomalies, by artifacts that reduce the image resolution and by advanced gestational age. MRI uses no ionizing radiation, provides excellent soft tissue contrast and has multiple planes for reconstruction and a large field of view. Thus, it is the method of choice when additional information is needed following ultrasound diagnosis (Levine 2001). In such cases MRI may give valuable information to add for the counseling process (Levine *et al.* 1999a, Knox *et al.* 2005). MRI has proven to be particularly beneficial in the evaluation of the fetal CNS system (Blaicher *et al.* 2005), especially in ventriculomegaly and imaging of the corpus callosum (Levine *et al.* 1999b) and when therapeutic consequences might be expected, such as diaphragmatic hernia, tumors (Knox *et al.* 2005) and fetal abdominal masses (Angtuaco *et al.* 1992). Because of signal-to-noise limitations, small fetal structures may be difficult to image by MRI (Blaicher *et al.* 2005), thus the fetal heart may be difficult to visualize and the interventricular septum and the atrioventricular valves may only occasionally be seen (Trop and Levine 2001). The claustrophobic factor for those inside the magnet and the vena cava syndrome often occurring in the third trimester of the pregnancy may be



factors that need to be addressed when imaging the fetus (Levine *et al.* 1999a). Increased experience with fast MRI techniques and 'real-time' cardiac MRI will most likely identify more conditions where this technique may add to the prenatal diagnosis (Fogel *et al.* 2005).

## **The fetal examination**

Ultrasound technique made it possible to get information directly from the fetus in a non-invasive manner. As the development of this technique and equipment continued, the use of ultrasound in pregnancy rapidly expanded. It became obvious that ultrasound technology could reveal conditions not detectable by traditional ways of collecting information from the pregnant woman and the fetus.

The first screening program for systematic use of ultrasound in pregnancy was initiated in Malmö, Sweden, in 1974, starting with one ultrasound examination at 28 weeks of gestation. The primary intention was to detect twins. In the following years, the examination was successively moved to 17 weeks. From 1976 a second routine examination was included at 32 gestational weeks (Grennert *et al.* 1978). In 1980, Germany was the first country to officially introduce the two-stage screening program, adopted from Malmö, to their total pregnant population (Mutterschafts-Richtlinien 1980). In Norway, a consensus conference concerning the use of ultrasound in pregnancy was held in Oslo in 1986. The consensus panel recommended the offer of one ultrasound examination at approximately 18 weeks to all pregnant women (Backe and Buhaug 1986). The recommendation was based on the reported decrease in post-term pregnancies following introduction of routine ultrasound (Eik-Nes *et al.* 1984a) and the need to organize the already extensive use of ultrasound in pregnancy (Eik-Nes 1986), later confirmed by Backe (1994). In the years that followed, routine ultrasound scanning was officially introduced by the health authorities in a number of European countries. Iceland followed the Norwegian one-stage model in 1987 (Geirsson 1987), and Austria followed the German two-stage model in 1988. In 1995, Germany expanded their official offer with an early scan at 10 weeks (Änderung der

Mutterschafts-Richtlinien 1995), and in 1996, Switzerland introduced an early scan at 10 weeks followed by an 18 week scan. Although not all countries have introduced the practice officially, most countries offer ultrasound examinations to their pregnant population today (SBU-rapport nr. 139, 1998).

Randomized controlled trials were carried out during the 1980s with the purpose of showing any benefit of using ultrasound in every pregnancy (Bennet *et al.* 1982, Eik-Nes *et al.* 1984a, Bakketeig *et al.* 1984, Neilson *et al.* 1984, Waldenström *et al.* 1988, Saari-Kemppainen *et al.* 1990, Eik-Nes *et al.* 2000). One problem with such studies is that the window for carrying them out is narrow. A study evaluating a new technique too early, before it is fully developed, may not show the full benefit of the technique studied. If it is done too late, the technique may already be in use and the information needed for comparison is no longer available (Eik-Nes 1993a, Salvesen and Eik-Nes 1994). The early findings in the controlled trials included a more precise estimate of the gestational age, resulting in a 70% reduced frequency of induction for overdue pregnancies (Eik-Nes *et al.* 1984a, Waldenström *et al.* 1988, Neilson 2004) and a reduction in perinatal mortality mainly due to improved early detection of major anomalies (Saari-Kemppainen *et al.* 1990).

Other studies evaluated the effectiveness of the routine examination to detect fetal developmental disorders (Chitty *et al.* 1991, Crane *et al.* 1994, Papp *et al.* 1995, Grandjean *et al.* 1999, Vial *et al.* 2001, Garne *et al.* 2005, Dolk 2005). Due to differences in use of ultrasound in pregnancy and in experience of the operators, the results varied between 35–74%. Once detected, various conditions could be followed and information derived from prenatal observations and follow-up through delivery and into the neonatal period. With such information, follow-up of the fetus and child has been optimized to improve perinatal mortality and morbidity (Bonnet *et al.* 1999, Brantberg *et al.* 2004).

Traditionally, pregnant women at increased risk of having a fetus with congenital heart defect have been referred to specialist for an additional ultrasound examination (Allan

*et al.* 1986a). In the 1980s, pediatric cardiologists clearly saw the potential of ultrasound techniques such as M-mode, two-dimensional and Doppler echocardiography, techniques utilized for the fetal heart examination in high-risk pregnancies (Kleinman *et al.* 1980, Huhta 1986). In 1985, a French study first initiated the idea of prenatal cardiac screening (Fermont *et al.* abstract 1985), closely followed by Allan *et al.* (1986b). They suggested that 2/1000 major CHDs could be detected by including the four-chamber view into the second trimester fetal examination. It was soon realized that fetal heart defects were more difficult to detect than major defects in other fetal organs, particularly in non-selected populations (Brocks and Bang 1991, Crane *et al.* 1994, Rustico *et al.* 1995, Tegnander *et al.* 1995, Buskens *et al.* 1996, Bull 1999, Wong *et al.* 2003).

With the improvement in ultrasound technology, more and more details of the fetal heart could be imaged at an earlier gestation (Achiron *et al.* 1994, Allan *et al.* 1997). Data also showed that in the group of fetuses at increased risk for CHD, only a small percentage of the total CHD-population was found (Allan *et al.* 1994, Maher *et al.* 1994, Carvalho *et al.* 2002, Åmark *et al.* 2004). Most fetuses with CHD were born from mothers at no increased risk at all, thus the second trimester fetal examination became important for the prenatal detection of CHDs.

The poor detection rates of major CHDs from non-selected populations needed to be addressed. The equipment used, the gestational age at the time of the fetal examination and details obtained from the fetal heart were factors that had to be evaluated. The ultrasound machines used for second trimester screening purposes were often of poorer quality than the equipment used at referral centers. This was a paradox, since in order to make a referral for second opinion, the CHD had to be suspected when the routine scan was made; thus, good quality machines should be available in routine ultrasound settings. But, even with an ultrasound with poor quality, it is necessary to be able to use the potential of the machine to create optimized ultrasound images in order to detect developmental disorders in general. In addition, the gestational age seems important in imaging anatomical structures. Several studies have shown that examination of the fetal

heart prior to 18 gestational weeks is too early to obtain details from the heart; thus, the fetal heart examination should be done after 18 weeks, preferably after 20 weeks (Schwärzler *et al.* 1999b, Allan 2003). The various ways of organizing the use of ultrasound in pregnancy and the upper limit for termination of the pregnancy are decisive factors for setting the optimal time for the second trimester fetal examination. During the last years, the 11–13+6 week ultrasound examination has been introduced (Nicolaidis *et al.* 1992). Increased nuchal translucency has proven to be a marker for chromosome aberrations, congenital heart defects and other defects such as diaphragmatic hernia and genetic syndromes (Nicolaidis *et al.* 1992, Hyett *et al.* 1997, Hafner *et al.* 1998a, Schwärzler *et al.* 1999a, Souka *et al.* 2001, Haak *et al.* 2002, Hyett 2002). Due to the fact that the fetal heart is tiny at that time of gestation, that an increased nuchal translucency may not be present in all CHDs, and because of the progression of CHDs during the time of the pregnancy, some heart defects may not be detected at such an early gestation (Maeno *et al.* 1999, Gardiner 2001, Mavrides *et al.* 2001, Trines and Hornberger 2004).

## **Epidemiology of congenital heart defects**

Congenital heart defect is one of the most common serious congenital anomalies found in live births with a reported incidence of 8/1000 live births (Mitchell *et al.* 1971). The use of ultrasound in non-selected populations has resulted in new information about the incidence, range and natural history of congenital heart defects seen prenatally (Allan 1989).

### **Incidence of CHDs**

Traditionally, the incidence of CHDs in large non-selected populations has been reported to be 8/1000 live births, of these, 4/1000 as major CHDs and 4/1000 as minor CHDs. A large variety of incidences are found from published data, between 3–12/1000 live births (Carlgren 1969, Mitchell *et al.* 1971, Hoffman and Christianson 1978, Dickinson *et al.* 1981, Ferencz *et al.* 1985, Meberg *et al.* 1990). The lower incidences

were reported before there were well-trained pediatric cardiologists and before cardiac surgery required a detailed preoperative diagnosis (Hoffman 1995a). The introduction of the ultrasound technique, including Doppler ultrasound and Color Flow Mapping, has made it possible to diagnose minor CHDs and even asymptomatic CHDs postnatally (Martin *et al.* 1989, Meberg *et al.* 1994), and has thus resulted in an increase in the reported incidence of CHDs.

### Fetal population versus postnatal population

Most studies from large populations evaluating the incidence of CHD have been based on postnatal populations (Mitchell *et al.* 1971, Dickinson *et al.* 1981, Ferencz *et al.* 1985, Samánek *et al.* 1989). In postnatal populations, the ascertainment of cases might be biased due to asymptomatic CHDs that are missed at the ordinary clinical exam (mild pulmonary stenosis, small ASDs or VSDs), incorrectly diagnosed cause of death, deaths prior to recognized CHD and intrauterine deaths and postnatal deaths without autopsy (Abu-Harb *et al.* 1994, Hoffman 1995a).

With the introduction of prenatal ultrasound, the natural history of CHDs could be studied. Some forms of CHD were seen more frequently prenatally than postnatally; some conditions, like HLHS, AVSD and critical aortic stenosis, were often presented with intrauterine heart failure, and a particularly high rate of chromosome aberrations was found among fetuses with CHD resulting in a high rate of intrauterine fetal deaths (Allan 1989). A high incidence of CHD and chromosome aberrations among spontaneously aborted fetuses has also been found (Gerlis 1985, Chinn *et al.* 1989). This suggests that the true incidence of CHD in early fetal life may be higher than what our knowledge from born populations would lead us to believe.

### Selected versus non-selected populations

It has been a well-established routine to offer one extra ultrasound examination at 20–24 weeks of gestation when there is an increased risk for CHD (Callan *et al.* 1991, Allan *et al.* 1994, Oberhänsli *et al.* 2000). Maternal factors that might increase the risk are

family history of CHD; previous child affected; parental CHD; maternal diabetes; exposure to known cardiac teratogens (such as alcohol, amphetamine, anticonvulsants), intrauterine infections (rubella, parvovirus, coxsackievirus, cytomegalovirus) or high doses of ionizing radiation. Fetal factors are findings of nonimmune fetal hydrops, extra cardiac anomalies or arrhythmia (Allan 1989, Allan *et al.* 1994, Gembruch and Geipel 2003). Because of the increased risk of CHD among these fetuses, the ultrasound examinations have been done by obstetric ultrasound specialists or pediatric cardiologists utilizing advanced ultrasound equipment. The detection rates of CHDs from selected populations have thus been reported as high as 92% (Copel *et al.* 1987, Stewart *et al.* 1987). Despite the high detection rates, the CHDs detected constituted only a small percentage of the total CHD population, as most fetuses with CHD are found in non-selected populations (Allan *et al.* 1994, Maher *et al.* 1994, Carvalho *et al.* 2002, Åmark *et al.* 2004).

As routine ultrasound became an integrated part of prenatal care, an increasing number of women at no risk for disease were being referred to tertiary centers because of abnormal fetal hearts seen at ultrasound examinations (Allan *et al.* 1994, Sharland 2004). With new knowledge about where to find the CHDs, the focus changed towards fetal routine ultrasound in non-selected populations. The ultrasound operators were not as skilled, and the ultrasound machines not as advanced among those working with non-selected populations as among those working with selected populations at tertiary centers. In addition, the low incidence of malformations in non-selected populations made defects harder to find. CHDs seemed particularly difficult to detect, as the reported detection rates were lower than expected, and lower than the results from selected populations (Crane *et al.* 1994, Buskens *et al.* 1996, Bull 1999). Thus, investigating ways to increase the detection rate of CHDs in non-selected populations became important.

## Major and minor CHDs

There does not seem to be a universally accepted definition of major CHD (Allan *et al.* 2001). As a result, studies define major CHDs in various ways depending on the study

design, the population defined and the experience of the authors (Ferencz *et al.* 1990, Wren *et al.* 2000, Allan *et al.* 2001). These differences are reflected in the reported incidences of CHDs. Most investigators define major CHDs as defined by Mitchell *et al.* (1971) as a gross structural abnormality of the heart that is actually or potentially of functional significance (Hoffman 1995b, Allan *et al.* 2001).

For many years, an incidence of CHD of 8/1000 live births has been accepted in non-selected populations (Achiron *et al.* 1992, Boldt *et al.* 2002, Wong *et al.* 2003), whereas 4/1000 as major CHDs. New data show that the incidence of major CHDs has remained unchanged (Carvalho *et al.* 2002). One may conclude that the majority of the major CHDs have always been recognized, thus an incidence of approximately 4/1000 reflects proper ascertainment of the major CHD cases.

The incidence of minor CHDs, on the other hand, has steadily increased during the last years (Martin *et al.* 1989, Meberg *et al.* 1994, Roguin *et al.* 1995). Better postnatal clinical diagnosis and technique utilizing diagnostic ultrasound have resulted in an increased detection of minor CHDs previously not diagnosed. These are defects with little long-term consequences for the child and a vast majority close spontaneously within the first year after birth (Evans *et al.* 1960, Du *et al.* 1998, Helgason 1999, Meberg *et al.* 2000). There is reason to believe that the closure of these small defects towards the end of the pregnancy and during the first months of life may be a delay of a normal process, thus it might be questioned whether these defects are true congenital heart defects (Ben-Shachar *et al.* 1985, Hiraishi *et al.* 1992). As long as they are defined as CHDs, however, they will affect the incidence of CHDs in the population.

Obviously we have to reconsider the incidence of CHDs and the spectrum of CHDs as new data emerge.

## **The fetal heart examination**

Real-time 2D ultrasound still is the best ultrasound technique for structural evaluation of the fetal heart. The technical development has resulted in ultrasound machines with advanced features such as high image resolution and high frame rate, making it possible to obtain a detailed image of the tiny structures in the moving fetal heart (Chaoui 2001). For routine use in the second trimester, the ultrasound examinations are most often performed transabdominally. As the attenuation factor some times limits imaging depth (Kremkau 2006), especially in obese women, alternative routes for examination may be preferred. Kratochwil and Eisenhut (1967), Takeuchi *et al.* (1968) and Jouppila (1971) were the first to propose the transvaginal route to identify fetal heart pulsations. With real-time transvaginal transducers, the fetal heart could be imaged in detail, resulting in the first publication, in 1990, of a CHD detected at 11 weeks of gestation (Gembruch *et al.* 1990).


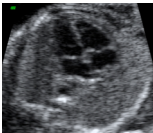


The first studies based on real-time images of the fetal heart were published in 1980 by Lindsey Allan *et al.* (1980), Kleinman *et al.* (1980) and Lange *et al.* (1980). Lindsey Allan's work from the early 1980s laid the basis for subsequent studies showing that fetal cardiac anomalies could be detected by real-time ultrasound in the second trimester of the pregnancy (Allan *et al.* 1986).

The fetal heart appears somewhat different than an adult heart. As a consequence of the normal large liver in fetal life, the heart is positioned more horizontally and the apex is displaced more cranially than in the adult. This results in a slightly different orientation of the heart with the right side positioned anteriorly in the fetal chest and the left side posteriorly. The two ventricles are equal in size in the fetus, and there is normally a patent foramen ovale between the two atria and a patent ductus arteriosus between the main pulmonary artery and the aortic isthmus. Fetal lungs are filled with water, which makes the heart visualized in planes not obtainable after birth (Allan *et al.* 1980, Allan 1986).



Since most fetuses with CHD are found in non-selected populations, the ultrasound examination for screening purposes is the only opportunity to detect the majority of CHDs. For this reason, an easy way of examining the fetal heart during the routine examination was introduced in the mid 1980s (Fermont *et al.* 1985, Allan *et al.* 1986b). Among the eight scan planes Allan *et al.* (1980) investigated, the four-chamber view was one of the easiest views to obtain, thus the four-chamber view was the plane chosen to be obtained in every fetus at the routine scan.

**Table 1** Sonographic details from the four-chamber view.

	Details obtained
<p>Transverse abdomen</p>  <p>Abdominal aorta and inferior vena cava</p>	<ul style="list-style-type: none"> <li>• Stomach is on the left side of the abdomen</li> <li>• Aorta is on the left side of the spine</li> <li>• Inferior vena cava is on the right side of the spine, ventral to the aorta</li> </ul>
<p>The atrio-ventricular junction (The four-chamber view)</p>  <p>Position</p>  <p>Apical view</p>  <p>Subcostal view</p>	<ul style="list-style-type: none"> <li>• The heart occupies 1/3 of the thoracic area</li> <li>• The position is in the middle of the thorax with the apex pointing towards left</li> <li>• The rhythm is regular between 120–160 beats/minute. Short periods of bradycardia are normal in the second trimester of the pregnancy.</li> <li>• There is equal contractility on the left and the right side of the heart</li> <li>• There are two atria of equal size</li> <li>• There are two ventricles of equal size</li> <li>• The left ventricle forms the apex</li> <li>• The moderator band is found in the right ventricle</li> <li>• There are two atrioventricular valves</li> <li>• The tricuspid valve is closer to the apex than the mitral valve is</li> <li>• The two septa and the atrioventricular valves form an “offset cross” in the middle of the heart</li> <li>• There is an intact ventricle septum</li> <li>• There is a patent foramen ovale in the atrial septum</li> <li>• Two pulmonary veins connect to the left atrium</li> </ul>

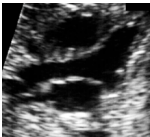
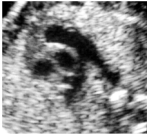

The four-chamber view seemed to be an easy view to obtain, as the reported success rates in viewing the four chambers in all fetuses were more than 95% (Copel *et al.* 1987, Achiron *et al.* 1992, Todros *et al.* 1997). Despite the easy access to this view, it

seemed to increase the detection rate of major CHDs to only a small degree (Achiron *et al.* 1992, Ott 1995, Tegnander *et al.* 1995, Todros *et al.* 1997).

The importance of evaluating all the details in the four-chamber view, as shown in Table 1, has been emphasized by several authors (Allan 1986, Chaoui 2003, Sharland 2004).



To be able to detect CHDs with a normal four-chamber view the great arteries need to be included into the fetal heart examination. Educational sites and organizations recommend examination of both the four-chamber view and the great arteries when the fetal heart is evaluated. Details to evaluate when the great arteries are obtained are shown in Table 2. In 1997, Yoo *et al.* introduced the three-vessel view as an easy way to examine the great arteries (Table 2). The three-vessel view has proven to be an important view for detection of defects affecting the outflow tracts and the great arteries (Yoo *et al.* 1999, Gardiner 2001).

**Table 2** Sonographic details from the great arteries.

	Details obtained
<p>The ventriculo-arterial junction</p>  <p>Ascending aorta</p>  <p>Pulmonary artery</p>  <p>Three-vessel view</p>	<ul style="list-style-type: none"> <li>• The ascending aorta arises from the left ventricle</li> <li>• There is continuity between the anterior wall of the ascending aorta and between the ventricle septum and the posterior wall and the mitral valve</li> <li>• The main pulmonary artery arises from the right ventricle and branches into the right pulmonary artery and the ductus arteriosus</li> <li>• The main pulmonary artery crosses over with the ascending aorta</li> <li>• The two arteries are approximately equal in diameter (the main pulmonary artery slightly larger)</li> </ul> <p>Three-vessel view</p> <ul style="list-style-type: none"> <li>• The main pulmonary artery is seen in a longitudinal view from the right ventricle to the ductus arteriosus</li> <li>• The ascending aorta is seen in a transverse view on the right side of the main pulmonary artery</li> <li>• The superior vena cava is seen in a transverse view on the right side of the ascending aorta</li> <li>• The vessels are arranged in a straight line and sized in decreasing order</li> </ul>

When the great arteries were introduced, the heart examination also included the aortic arch and the ductal arch (Bromley *et al.* 1992). Details of importance to notice when the arches are examined are shown in Table 3. Later, a five-step approach to the examinations of the fetal heart was introduced including only transverse views from the fetus (Yagel *et al.* 2001). The authors concluded that a proper evaluation of all the five views, also shown in Tables 1 and 2, make the view of the arches unnecessary. As the arches might be difficult to obtain due to the fetal position, the three-vessel view has been recommended as an optional view (Chaoui 2003a). Prenatal detection of ductal dependent CHDs may also improve from the effort of obtaining the three-vessel view (Viñals *et al.* 2002).

**Table 3** Sonographic detail of the aortic arch and ductal arch.

	Details obtained
The arches  Aortic arch	<ul style="list-style-type: none"> <li>• The aortic arch is seen as a tight hook (“candy cane shape”) tucking into the center of the heart</li> <li>• The aortic arch gives rise to the head and neck vessels</li> <li>• The ductal arch arises from the right ventricle close to the anterior chest wall, is directed straight backwards (“hockey stick shape”) and connects to the descending aorta</li> <li>• The ductal arch have no head and neck vessels</li> </ul>
 Ductal arch	

In a screening situation, the time allocated for the complete scan is limited. With an awkward fetal position or fetal movements, planes expected to be identified during the scan may not be obtainable. A higher detection rate of cardiac structures may be achieved if unlimited time is given for the examination (Allan *et al.* 1980) or if a repeat scan is offered when the fetal heart examination at the routine scan is difficult (Allan *et al.* 1980, Rustico *et al.* 1995, Kirk *et al.* 1997). For other fetal anatomical structures, the specific focus and standardization of the examination procedure, for instance nuchal translucency measurement at an early gestation, has resulted in an increased detection of certain developmental disorders (Nicolaidis *et al.* 1992, Hafner *et al.* 1998a, Nicolaidis 1999, Schwärzler *et al.* 1999a, Souka *et al.* 2001, Hyett 2002). Had the same high quality standard used in the nuchal translucency measurements been applied to the

evaluation of the four-chamber view and the great arteries, our detection rate of CHDs most likely would have been improved.

Fetal echocardiography is defined as a specific fetal heart examination where the four-chamber view, the great arteries and the venous return to the heart are evaluated (Huhta and Rotondo 1991, Stümpflen *et al.* 1996). To optimize the image of the heart, additional techniques such as spectral Doppler, color Doppler (Chaoui 2001) and even 3D ultrasound (Budorick and Millman 2000, DeVore *et al.* 2003) may be used.

Advanced techniques may well be of diagnostic value for the selected group of fetuses where a heart defect is suspected. For routine use in a screening situation, the use of advanced techniques is time consuming and requires skilled personnel. Until the views of the four chambers and the great arteries are properly learned and interpreted among the personnel performing routine fetal examinations, the advanced technology belongs in a fetal echocardiography setting.

## **Teaching and training obstetric ultrasound**

In the early days of diagnostic ultrasound development, the static scanners were huge, bulky machines and required extremely skilful operators. As a consequence the average physician did not give much attention to the ultrasound technique (Eik-Nes 1993, Woo 2005). The obstetrician and gynecologist Alfred Kratochwil, an enthusiast in obstetric ultrasound development, saw the need for training and offered courses in ultrasound in Vienna, starting in 1968. This was after the introduction of the articulated-arm design, which made the ultrasound machines easier to manipulate (Woo 2005). The same year Kratochwil published his first book “Ultraschalldiagnostik in Geburtshilfe und Gynäkologie”, one of the earliest textbooks in ultrasonography in this field (Kratochwil 1968). Kratochwil has followed up his teaching tradition and, after his retirement in 1992, started regular courses for 3D ultrasound.

In the mid-1970s, the machines became easier to use with improved image quality. Since then, the ultrasound technique has gone through extensive improvement, both

when it comes to quality, size and cost of the machines. Ultrasound equipment is now available to all physicians. However, because modern ultrasound machines are highly developed technology with detailed resolution of the images and applications for different examination procedures, an understanding of the basic principles of ultrasound physics is a prerequisite for a proper and safe use of the equipment and an optimal ultrasound examination.

The educational and training aspect regarding the use of obstetric ultrasound has become increasingly more important with the improvement in ultrasound technology. Still, the requirements regarding ultrasound education and training vary greatly. With the introduction of routinely performed ultrasound scans in pregnancy, the need for ultrasound operators suddenly increased. It was emphasized that the ultrasound operators needed ultrasound training and experience, but there were no requirements for such training and thus no quality control of the examinations was carried out (Backe and Buhaug 1986).

The need for professions other than physicians to perform ultrasound examinations soon became obvious as the indications for the use of ultrasound in obstetrics increased. Already in the mid-1960s, nurses and radiographers assisted physicians in performing ultrasound examinations (Baker 2005). Approved by the American Institute of Ultrasound in Medicine, the American Society of Ultrasound Technical Specialists was established in 1970. After 10 years of discussions and struggling to survive as a profession, the first accreditation of educational programs occurred in 1982 (Baker 2005). The term 'sonographer' came to be used for this profession. Today, postgraduate ultrasound programs for sonographers are well established in several countries, such as the USA, Canada, Australia and the United Kingdom.

In the department of Obstetrics and Gynecology in Malmö, Sweden, where the routine scans were originally introduced in 1976, the scans were performed by nurse/midwives (Grennert *et al.* 1978). In the Scandinavian system, nurse/midwives have a strong tradition in pregnancy care, and it was therefore natural to base the scanning on this

profession. This was immediately adopted in Norway. In Ålesund, a number of midwives were systematically trained in obstetric ultrasound by Eik-Nes in the early 1980s. In Denmark, registered nurses initially took an interest in obstetric ultrasound, while nurse/midwives became involved at a later stage. For many years, obstetric ultrasound has been performed by personnel with varied ultrasound experience. In 1997, postgraduate education in obstetric ultrasound for nurse/midwives was established at the National Center for Fetal Medicine in Trondheim and is now part of the general offer of education at the Norwegian University of Science and Technology in Trondheim. This one-year part-time education includes both academic and clinical education and is at present the only education of this kind in Scandinavia.

Ultrasound imaging is not a passive activity but rather an interactive process involving the sonographer, patient, transducer and the ultrasound instrument (Kremkau 2006). The ultrasound operator has to interpret the images while the examination is being performed, placing strong demands on the ultrasound operator's knowledge and experience in ultrasound technique and interpretation of ultrasound images. The importance of experience has clearly been demonstrated in the RADIUS study where the poor detection rate of developmental disorders most likely was a result of poor training and not a result of the diagnostic limitations of the ultrasound technique (Ewigman *et al.* 1993, Gonçalves and Romero 1993, Crane *et al.* 1994). Studies also show that tertiary centers have higher detection rates of fetal malformations than do non-tertiary centers. This is most likely due to the academic environment and a higher number of examinations resulting in increased ultrasound skills (Saari-Kemppainen *et al.* 1990, Crane *et al.* 1994, Wong *et al.* 2003). Other studies show the success in implementing teaching programs for the detection of fetal malformations (Sharland and Allan 1992, Hunter *et al.* 2000, Carvalho *et al.* 2002, Cuneo *et al.* 2004), emphasizing that the basic training has not been sufficient. Ultrasound societies and educational sites have guidelines for the proper way of examining the fetus (Meyer *et al.* 1990, ISUOG education committee 1996, Burr and Johanson 1998, Abuhamad *et al.* 2004, Allan *et al.* 2004, ISUOG guidelines 2006). These are of great value for the harmonization of the

examinations between countries, but may not reach their expectations as long as the basic ultrasound education is insufficient.

With the rapid development of ultrasound technology, new techniques and examination procedures have been introduced in obstetric ultrasound. This implies that the appropriate way of performing ultrasound examinations a few years ago has changed and may be different and improved today. Regular updates are necessary to keep up with the development, and each ultrasound operator carries this responsibility. Interest and motivation have been reported as important factors when it comes to applying new ultrasound techniques (Roberts *et al.* 1995, Nicolaides 2004).

As long as governments and professional societies do not understand the necessity of ultrasound education, we have to accept that the quality of the examinations will vary, resulting in a variable quality of the scan offered to the pregnant population. Thus, the intention stated 20 years ago in the Consensus Statement from 1986 (Backe and Buhaug 1986) about improvement of the quality of the examinations conducted, has not yet been fulfilled for the total pregnant population in Norway.

## AIMS OF THE STUDIES

One of the purposes of the second trimester routine ultrasound examination is to detect fetal developmental disorders that will benefit from prenatal diagnosis. Already in the late 80s it was clear that CHDs were detected far less frequently than defects in other fetal organs (Lys *et al.* 1989, Rosendahl and Kivinen 1989, Brocks and Bang 1991). To increase the prenatal detection rate of congenital heart defects, the present study has evaluated different methods to examine the fetal heart during the second trimester routine examination. An important factor was to find easy ways to examine the heart, as the fetal heart examination is only a small part of the complete routine scan. At the same time, the aim was to get as much information as possible from the heart to correctly differentiate normality from pathology. In addition to evaluating the sonographic appearance of the fetal heart, this study also addressed the sonographer/midwives' scanning skills to see if their amount of experience affected their ability to obtain fetal heart structures, and thus affected their ability to detect heart defects. It was also of interest to follow the outcome of the CHDs, detected and not detected prenatally, to measure the impact of prenatal diagnosis of CHDs.

The aims of the five studies were:

- I To assess if incorporation of the four-chamber view of the fetal heart was achievable within the 30 minutes allocated to the second trimester routine examination at 18 weeks of gestation, and to evaluate any fetal, maternal or technical reasons for not being able to obtain this view.
  
- II To evaluate prospectively whether the implementation of the four-chamber view to the second trimester routine examination in a large non-selected population would improve the detection rate of congenital heart defects compared to a period when the heart was not systematically evaluated, and to evaluate the CHDs detected and not detected to find ways to further improve the prenatal detection rate.



- III To evaluate the detection rate of congenital heart defects in a non-selected population following the introduction of the four-chamber view and the great arteries to the second trimester routine scan, to understand the pattern of prenatal recognition of heart defects to further improve the detection rate, and to follow the fetuses/children with CHDs into the postnatal period to get a better understanding of the outcome, in order to improve the accuracy of counseling.
  
- IV To compare the experienced and the less experienced sonographer/midwives' ability to obtain fetal heart structures leading to detection of CHDs at the second trimester routine scan in a large non-selected population with the purpose of evaluating whether basic education and experience, as opposed to advanced examination procedures, was of importance in detecting CHDs, and to suggest improvements to the current ultrasound training program.
  
- V To introduce a new three-dimensional technique based on tissue Doppler gating (TDOG) to create reconstructed, dynamic 3D ultrasound images of the fetal heart and to evaluate the accuracy of the signals and the reconstruction of the most common two-dimensional views used during a fetal heart examination.

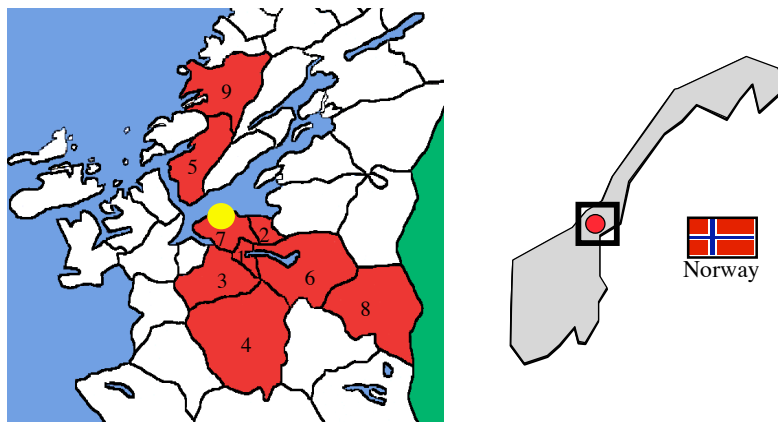
## MATERIAL AND METHODS

### Populations and study design

The non-selected population came from a geographically well-defined area including the city of Trondheim and eight surrounding communities with approximately 200,000 inhabitants (Figure 15).

**Figure 15** Communities included in the study:

- 1 Klæbu
- 2 Malvik
- 3 Melhus
- 4 Midtre Gauldal
- 5 Rissa
- 6 Selbu
- 7 Trondheim
- 8 Tydal
- 9 Åfjord



This area is served solely by Trondheim University Hospital for all health care services. To ensure a true non-selected population, a community was included only when more than 97% of the pregnant women residing in the selected community received a prenatal ultrasound at the National Center for Fetal Medicine and more than 97% delivered at the University Hospital. The University Hospital also includes the only Neonatal Intensive Care Unit and the only Pediatric Cardiology Unit for the same population.

During the study period from August 1986 to December 2001, this non-selected population constituted the *total* population of 42,381 fetuses, all scheduled to be born at Trondheim University Hospital. Of those, 41,354 (98%) had an ultrasound examination performed at the National Center for Fetal Medicine, and thus formed the *study population* (screened population).

The second trimester routine ultrasound examinations were scheduled at 18 completed weeks based on the last menstrual period and/or early clinical assessment. The examinations were performed mainly by nurse/midwives with basic training in obstetric ultrasound. Following the official university-based education in obstetric ultrasound they are referred to as sonographer/midwives. Ultrasound examinations prior to the routine scan were done by physicians with ultrasound experience, while normal follow-up ultrasound examinations after the routine scan were mainly performed by sonographer/midwives. Except for the routine scan, the ultrasound examinations were performed on clinical indications, only.

The routine fetal examinations were scheduled at 30-minute intervals, and included a basic obstetric history as well as general information to the parents. The ultrasound examination comprised assessment of the number of fetuses, regular biometric measurements, placental location, a detailed survey of the fetal anatomy and an overview of the adnexae uteri. The final gestational age was based on the fetal BPD between 16+1 and 22+5 weeks (BPD outer-outer 38–60 mm) or the BPD and/or CRL for those detected prior to the routine examination. All data from the ultrasound examinations were prospectively registered in a computer database.

When a heart defect was diagnosed or suspected, a physician at the center carried out a detailed survey of the heart and the fetal anatomy, in most cases in the presence of a pediatric cardiologist.

A perinatal team consisting of an obstetrician, a sonographer/midwife, a pediatric cardiologist and a social worker supported the parents and the fetus/newborn from the time of diagnosis until after the delivery. If the pregnancy was continued, a specialist pediatric cardiac nurse became a part of the perinatal team. When immediate intervention after birth was expected, the planned delivery took place at the National Hospital in Oslo where neonatal cardiac surgery service is centralized in Norway. If a pregnancy was terminated, the parents were supported during that process and during

the time thereafter. In Norway, termination of the pregnancy may be approved until approximately 22 weeks.

Within the first 24 hours after birth, all newborns had a general clinical examination by a pediatrician. If a heart defect was suspected, the child was referred to a pediatric cardiologist for an echocardiogram. CHDs detected after discharge from the hospital were referred to the Pediatric Cardiology Unit. The health care program in Norway ensures all children regular physical examinations at child health care centers until school age. For the first part of the study these examinations took place at 3, 6 and 12 months, and at 2, 4 and 7 years of age (Paper II), the examinations were later changed to 6 weeks, 6 and 12 months, and at 2, 4 and 6 years of age (Paper III).

## **Paper I**

### **Incorporating the four-chamber view into the second trimester routine examination**

The prospective study included 7,322 consecutive fetuses at the second trimester routine examination and was divided into two periods: Period I, from June 1988 to May 1989, included 2,993 fetuses; Period II, from June 1989 to September 1990, included 4,329 fetuses. The criteria for a proper four-chamber view were: two ventricles of equal size; two atria of equal size; the heart occupying one-third of the thorax area; the heart located in the middle of the thorax with the apex pointing to the left anterior chest wall.

The five sonographer/midwives' ability to include the four-chamber view into the second trimester routine protocol was assessed during Period II. Every fetus for which a four-chamber view could not be obtained was registered on a separate form with a comment about any reason why a proper image of this view failed.

## **Paper II**

### **Prenatal detection of CHDs at the second trimester routine examination including the four-chamber view of the fetal heart**

The prospective study included a *total* population of 12,232 fetuses, of which 11,894 (97%) fetuses had a second trimester routine ultrasound examination and constituted the study population (screened population). The study was divided into two phases: Phase I, from August 1986 to May 1988, included 4,435 fetuses; Phase II, from June 1988 to January 1991, included 7,459 fetuses. The criteria for a proper four-chamber view were: two ventricles of equal size; two atria of equal size; the heart occupying one-third of the thorax area; the heart located in the middle of the thorax with the apex pointing to the left anterior chest wall.

The detection rate of CHDs at the second trimester routine examination and a total prenatal detection rate was compared between Phase I, when no specific attention was paid to the fetal heart, and Phase II, when the four-chamber view was obtained in every fetus. The longest and shortest postnatal follow-up times for Phase I were 77 months and 58 months, for Phase II, 57 and 26 months, respectively.

## **Paper III**

### **Prenatal detection of CHDs including the four-chamber view and the great arteries of the fetal heart – detection rates and outcome**

The prospective study included a *total* population of 30,149 fetuses, of which 29,460 (98%) fetuses had prenatal ultrasound and constituted the study population (screened population). The study period lasted from February 1991 to December 2001. The criteria for obtaining the four-chamber view and the great arteries properly were: two atria of equal size; two ventricles of equal size; moderator band in the anterior right ventricle; tricuspid valve closer to apex than the mitral valve; intact ventricle septum; crossing of the ascending aorta with main pulmonary artery; aortic arch; ductal arch. From January 1995, a new scan was offered at approximately 20 weeks of gestation if a proper four-chamber view had not been seen at the routine scan. The examination at

20 weeks included the four-chamber view, the great arteries and the venous return to the fetal heart.

The postnatal follow-up of the children born with CHD included a description of their clinical condition. A classification system has been developed to critically evaluate the use of diagnostic procedures and therapies in the management of prevention of disease states (American Heart Association, 1994). The functional capacity is based on subjective symptoms as well as objective assessment (Bennett *et al.* 2002). According to the New York Heart Association classification system, “healthy” was defined as a person with cardiac disease without limitations of physical activity or objective evidence of cardiovascular disease (Class I).

The detection rate of CHDs was assessed after the four-chamber view and the great arteries of the fetal heart were included in the fetal examination protocol; the pattern of prenatal recognition was sought to further improve the detection rate, and CHDs were followed-up into the postnatal period to improve the accuracy of counseling. The children were followed for a minimum of two years and a maximum of 13 years.

#### **Paper IV**

##### **Comparison between experienced and less experienced sonographer/midwives in obtaining fetal heart structures and detecting CHDs prenatally**

All sonographer/midwives assessed during the study period were specially trained in obstetric ultrasound. The basic training included a minimum of 200 routine examinations supervised by experienced sonographer/midwives in addition to a Level I ultrasound course. For this study, “experienced” was defined as a sonographer/midwife who had performed more than 2000 routine examinations after completing the basic ultrasound training. “Less experienced” was defined as a sonographer/midwife who had performed between 200 and 2000 routine ultrasound examinations after completing the basic ultrasound training. The ultrasound experience following the basic training varied from 3 months to 17 years.

The prospective study included a population of 29,460 fetuses, of which 29,035 (99%) had had a second trimester routine examination performed by a sonographer/midwife. Those who did not receive a second trimester routine scan and those who were scanned by a physician were excluded. During the study period from February 1991 to December 2001, the four-chamber view and the great arteries were obtained from the fetal heart. During the first five years of the study period, heart structures obtained from every fetus were registered in detail on a separate form: four chambers; intact ventricular septum; tricuspid valve closer to the apex than mitral valve; ascending aorta; main pulmonary artery; aortic arch; ductal arch. From January 1995, a new scan was offered at approximately 20 weeks if a proper four-chamber view had not been seen at the routine scan. The examination at 20 weeks included the four-chamber view, the great arteries and the venous return to the fetal heart. Minor CHDs were excluded from this study.

A comparison between the experienced and the less experienced sonographer/midwives was carried out regarding their success rate in obtaining the fetal heart structures and prenatal detection of major CHDs.

## **Paper V**

### **Introduction of three-dimensional ultrasound imaging of the fetal heart (TDOG)**

The study included 8 selected pregnant women who were scheduled for a regular cardiac scan between 20–24 gestational weeks following a second trimester routine examination. The scanning time was 30 minutes for each fetus. Tissue Doppler data from the fetal heart were used to calculate a gating signal to create dynamic 3D reconstruction of the heart. The classical 2D views for reconstruction were: four-chamber view; ascending aorta; main pulmonary artery; three-vessel view; short-axis view of the great arteries; aortic arch; ductal arch; long-axis view of inferior and superior venae cavae.

A new method to image the fetal heart was introduced. Tissue Doppler gated (TDOG) dynamic 3D ultrasound images of the fetal heart were created, the accuracy of the

TDOG signals and the reconstruction of the most common views through the fetal heart were evaluated.

## Methods

### Classifications of congenital heart defects

In Paper II the heart defects were classified as critical or non-critical, in Papers III and IV as major or minor, which were synonymous to critical and non-critical. The difference in terminology was due to improved postnatal treatment over time, leading to survival of children with critical CHDs that in the early study period had had no treatment options. The classification was done retrospectively after a final diagnosis was achieved either by postnatal echocardiogram or by autopsy. The majority of the spontaneous losses after 22 weeks were autopsied. A perinatal pathologist at the National Center for Fetal Medicine performed the postmortem examinations (Isaksen *et al.* 1999). When postnatal echocardiogram or autopsy was not available, the prenatal video recordings and hard copies were scrutinized to ensure the correct heart diagnosis.

The defects were classified as *major* when surgical repair was most likely to be required because of gross structural complexity having functional significance (Mitchell *et al.* 1971), e.g. TGA, HLHS, AVSD, coarctation of aorta, large VSD (Papers II–IV). Heart defects were classified as *minor* when no intervention was likely to be required, e.g. mild pulmonary stenosis, mild aortic stenosis, small VSD, small ASD (Papers II and III). If there was doubt as to whether a heart defect was major or minor, the defect was classified as major if intervention was actually needed during the first month of life. Excluded from this study were arrhythmias with a structurally normal heart, patent ductus arteriosus, atrial septal defects < 3 mm (Radzik *et al.* 1993) and absent inferior vena cava with azygos continuation. Rhabdomyomas were categorized as tumors and thus excluded as heart defects.

Fetal karyotyping was offered in all prenatally detected cases. During the first 10 years of the study it was mainly performed by fetal blood sampling; later, by amniocentesis



and fluorescence in situ hybridization analysis (FISH) (Wakui *et al.* 1999). The 22q11 microdeletion was not routinely checked during this study. When a karyotype was not obtained, it was considered as probably normal.

The major CHDs were grouped as *isolated* in fetuses with a normal karyotype and absence of extra-cardiac malformations; as *abnormal karyotype* in fetuses with a chromosome aberration with or without extra-cardiac malformations; as *associated malformations* in fetuses with extra-cardiac malformations but a normal karyotype (Papers III and IV). The most common major CHDs (AVSD, TGA, HLHS, coarctation of aorta) were grouped as *simple* when additional cardiac defects were absent, e.g. TGA or AVSD; as *complex* when additional heart defects were present, e.g. TGA with associated single ventricle, HLHS with additional coarctation of aorta (Paper III).

### Ultrasound equipment and computer software

The ultrasound scanners used during the total study period were replaced over time. For Papers I and II, a Hitachi EUB 40 ultrasound scanner with 3.5 or 5 MHz transducers and a Hitachi EUB 410 with a 5 MHz transducer (Hitachi, Tokyo, Japan) were used. For Papers III and IV the ultrasound scanners used were Hitachi EUB 415 and EUB 6000 with 5 MHz and 3.5 MHz transducers (Hitachi, Tokyo, Japan), VingMed CFM 800 with a 5 MHz mechanical sector transducer and VingMed System Five with a 3.5 MHz curvilinear transducer (Vingmed Sound, Horten, Norway). For Paper V, a Vivid 7 scanner (GE Medical Systems) with a 1.5D probe with a frequency range of 2–5 MHz (Vingmed Sound, Horten, Norway) was used and the reconstruction was performed with the EchoPAC-3D software product (GE Medical Systems).

### 3D imaging

#### Data acquisition

3D data were acquired by collecting several datasets in one sweep covering the complete heart for each fetus. Using a free-hand technique, the transabdominal scan plane was slowly tilted manually over a period of 8–20 seconds (20–50 cardiac cycles).

The total angle of the sweep was estimated by recording a separate loop through the center of the heart, in the elevation direction of the sweep. Each dataset consisted of a duplex sector scan with a visible B-mode image and 2D tissue Doppler not visible during acquisition. Based on subjective evaluation of the clinical data, a second harmonic setup with a transmitting frequency of 2.5 MHz and a receiving frequency of 5.1 MHz, an inter-beam distance of  $0.3^\circ$  and a data rate of 96 frames/second was chosen as an adequate trade-off between frame-rate and image quality. The tissue Doppler settings were adjusted to provide a small bandwidth, but the frame size and frame rate were the same, with transmitting and receiving frequencies of 2.4 MHz and an inter-beam distance of  $3.8^\circ$ . There were three pulse firings in each beam direction of the tissue Doppler.

The gating signal was derived from clutter-filtered IQ data. Following calculation of autocorrelation of lag 1, the imaginary part of this was averaged over each frame, and then the local minima were extracted.

#### Reconstruction

The EchoPAC-3D software program converted the B-mode scan-lines into a sequence of voxel datasets, yielding a 4D dataset with temporal resolution equal to the B-mode frame rate and duration of one cardiac cycle. The 4D data were then visualized by two standard examination techniques for 3D medical imaging: 2D slicing and volume projection.

#### Gating signal accuracy

CW spectral Doppler from the umbilical artery was used to evaluate the accuracy of the TDOG signal, and was recorded simultaneously with the B-mode and tissue Doppler IQ data, but with a separate ultrasound system. The recordings were synchronized for offline analysis by simultaneously recording an independent signal on both ultrasound systems. The cycle lengths from the two methods were then compared and the variation in time delay between upstroke readings from the spectrum and the TDOG signal was examined.

The use of the tissue Doppler signal for synchronization was evaluated visually by running side-by-side consecutive cine-loops.

### Statistical analysis

The observed frequencies were tested for significance using the  $\chi^2$  (Chi-square) statistical test (Papers I and II). Groups were compared in 2x2 contingency tables using Pearson Chi-Square or Fisher's exact test (Papers III and IV). The level of significance was set at  $p < 0.05$ .

## RESULTS AND COMMENTS

### Paper I

#### Incorporating the four-chamber view into the second trimester routine examination

In period I, a four-chamber view could not be obtained in 220 (7%) of the 2993 fetuses scanned using a Hitachi EUB 40 ultrasound scanner. A significant difference was found in the number of four-chamber views not obtained when the 3.5 MHz and the 5 MHz transducers were compared, 35/131 (26.7%) and 185/2862 (6.5%), respectively ( $p < 0.001$ ).

In period II, there was no difference in the number of four-chamber views not obtained with a 5 MHz transducer when the Hitachi EUB 40 ultrasound scanner used through period I was compared with a new Hitachi EUB 410 ultrasound scanner, 3.8% versus 4.3%, respectively. When the results for the Hitachi EUB 40 scanner with a 5 MHz transducer were compared between Period I (6.5%) and Period II (3.8%), significant improvement was found ( $p < 0.001$ ).

The reasons why a four-chamber view could not be obtained were; unfavorable position of the fetus, poor imaging and maternal obesity. The main reason for not obtaining a four-chamber view utilizing the 3.5 MHz transducer was poor imaging (52%); for the 5 MHz transducer, the main reason was unfavorable fetal position (64%).

**Figure 16** Four-chamber views not obtained for each gestational week at the second trimester routine scan.

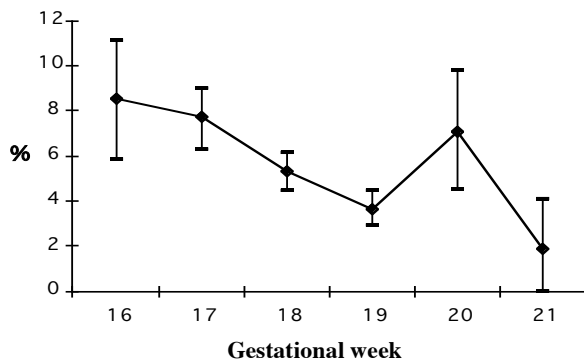


Figure 16 shows the percentage of four-chamber views not obtained for each gestational week between 16 and 21 weeks.

The five sonographer/midwives active in both periods significantly improved their ability to obtain a four-chamber view from period I to period II when a 5 MHz transducer was used. The individual results for not obtaining a four-chamber view varied from 3-10% in period I to 2-6% in period II ( $p < 0.001$ ).

Comments:

The four-chamber view was introduced in the mid-1980s (Fermont *et al.* 1985, Allan *et al.* 1986b) with the purpose of increasing the prenatal detection rate of CHDs. At that time, most studies concerning the fetal heart came from selected populations. In one such study (Copel *et al.* 1987), it was suggested that a four-chamber view of the fetal heart should be obtained in more than 95% of the fetuses between 18 and 40 weeks. As these results were based on ultrasound examinations throughout the pregnancy in a selected population it was not obvious that the same results would be reached in a non-selected population at an earlier gestational age. At our center, 98% of the pregnant population received a second trimester routine scan between 16 and 22 gestational weeks and the 30 minutes allocated to the complete consultation were already exhausted to serve other tasks.

Our study showed that a four-chamber view could easily be incorporated into the second trimester routine scan at approximately 18 weeks, as this view was successfully obtained in 96% of the fetuses. The result was similar to findings published from other non-selected populations at that time (Achiron *et al.* 1992, Vergani *et al.* 1992) and could also be compared with results from selected populations (Copel *et al.* 1987). It is assumed that 50% of the major CHDs can be detected by evaluating the four-chamber view (Allan *et al.* 1986b, Cullen *et al.* 1992), thus, an incorporation of this view may increase the prenatal detection rate of heart defects. During this study period, 87% of the pregnant women in the total country of Norway accepted the second trimester scan, 97% in the region served by Trondheim University Hospital (Nafstad and Backe 1989).

Incorporation of the four-chamber view to the routine scan protocol would thus cover most of the pregnant population with the possibility to detect 2/1000 major CHDs.

During the two periods, there were significant improvements in obtaining the four-chamber view. In Period I, the 5 MHz transducer was superior to the 3.5 MHz transducer in obtaining this view. This could be explained by the improvement in resolution when a higher frequency was chosen. The different reasons why a four-chamber view could not be obtained may support this explanation. The main reason for not obtaining this view utilizing the 3.5 MHz transducer was poor imaging, which most likely was caused by poor resolution. In both Periods I and II, the main reason for not being able to obtain the four-chamber view with the 5 MHz transducer was fetal position. Thus, the reason was not dependent on the quality of the transducer. Obviously, the awareness of the ultrasound equipment and the choice of transducer are of significant importance when small fetal structures are to be imaged. As a consequence of the obvious difference between the transducers, the 5 MHz transducer was preferred for the total second trimester routine scan, as better resolution due to an increase in frequency was expected to affect the image of the fetal anatomy in general, and thus improve the overall quality of the routine scan (DeVore 1985, Kremkau 2006).

A four-chamber view could not be obtained in 7% of the fetuses in Period I when a Hitachi EUB 40 ultrasound scanner with a 5 MHz transducer was utilized. With a new Hitachi EUB 410 scanner with the same transducer in Period II, 4% could not be obtained, an improvement that could be explained by a new and better ultrasound machine. Interestingly, the results for the Hitachi EUB 40 improved from 7% in Period I to 4% in Period II. Although the same machine and transducer were used, the results improved significantly. Also when evaluating the results for the 5 sonographer/midwives active in both periods, significant improvements were found. The improvements may thus also be explained by a learning effect. When particular focus was set on the four-chamber view, the technique to obtain this view and the familiarity of the details in the four-chamber view would most likely improve over time (Sharland and Allan 1992). The relatively long learning curve to obtain the four-chamber view,

also found by Sharland and Allan (1992), may suggest that the examination of the fetal heart is difficult to learn in a second trimester routine setting.

The gestational age seemed to be of significant importance for the success in obtaining the four-chamber view. Prior to 18 weeks, the number of four-chamber views not obtained were higher than at 18–21 weeks. Sharland and Allan (1992) also found that four-chamber views were obtained less frequently prior to 18 weeks than after 18 weeks of gestation. Several authors have shown a high ability to obtain the four-chamber view after 18 weeks, and some report the results up to 40 gestational weeks, but without specification for each week (Copel *et al.* 1987, Achiron *et al.* 1992). As the routine fetal examination preferably is done in the second trimester, an ultrasound scan at 18–20 weeks performed with a 5 MHz transducer seems to be the optimal choices for the best results according to our data. The examiner's ultrasound experience also needs to be considered when evaluating the success in obtaining the four-chamber view.

## **Paper II**

### **Prenatal detection of CHDs at the second trimester routine examination including the four-chamber view of the fetal heart**

#### Detection of CHDs

In Phase I, when no particular attention was paid to the fetal heart, 49 fetuses in the population of the 4435 scanned had a CHD. Of the 17 major CHDs, three (18%) were detected at 18 weeks of gestation. None of the 32 minor CHDs were prenatally detected.

In Phase II, when the four-chamber view of the fetal heart was obtained, 90 within the population of the 7459 fetuses scanned had a CHD. Nine (39%) of the 23 major CHDs were detected prenatally: 6/23 (26%) at the second trimester routine scan and 3/23 (13%) at later scans.

Table 4 shows the major CHDs missed at the 18-week routine scan with respect to the expected four-chamber view presentation, including the three detected later in the

pregnancy. In three of the 17 cases missed at 18 weeks (VSD, overriding aorta; TOF; double aortic arch), an adequate four-chamber view could not be obtained due to poor imaging or unfavorable position of the fetus. In 7/17 (41%) cases, the routine scan was performed prior to 18 weeks of gestation.

**Table 4** Major CHDs not detected prenatally (including three detected later in the pregnancy) at the 18 week examination with four-chamber view presentation in Phase II.

<i>CHD diagnosis</i>	<i>n</i>	<i>Normal four-chamber view expected</i>
AVSD (twin, trisomy 21)	1	no
Coarctation of the aorta	2	yes
Coarctation of the aorta, ASD	1	yes
Common arterial trunk, large VSD*	1	no
Coarctation of the aorta, DIRV, VSD, mitral stenosis*	1	no
Double aortic arch	1	yes
TOF	2	yes
TGA	3	yes
Pulmonary atresia, tricuspid atresia, VSD*	1	no
Tricuspid atresia, pulmonary stenosis, VSD	1	no
VSD, large	2	no
VSD, overriding aorta (trisomy 18)	1	yes
Total	17	

\*CHD detected in the third trimester

Among the 4% in which a four-chamber view could not be obtained at the second trimester routine examination, 3 fetuses with major CHDs were found (incidence 10/1000 fetuses).

### Epidemiology

To ensure complete epidemiological data for the *total* population, 2 newborns with minor CHDs from Phase I (muscular VSD; secundum ASD) and 2 from Phase II (muscular VSD; pulmonary artery stenosis), where the mothers had not attended the ultrasound program at all, were included. The incidences of congenital heart defects for the *total* population from Phases I and II were: 11/1000 fetuses and 12/1000 fetuses, respectively; for major CHDs 4/1000 and 3/1000 fetuses; for minor CHDs 7/1000 and 9/1000 fetuses, respectively.



Isolated VSDs constituted 18/34 (53%) of the minor CHDs in the *total* population in Phase I, 50/69 (73%) in Phase II. The same numbers for the isolated secundum ASDs were 5/34 (14%) and 7/69 (10%), respectively. Within the first year of life, 50% of the isolated VSDs from Phase I and 70% from Phase II closed spontaneously.

#### Chromosome aberrations and associated malformations

Chromosome aberrations were found in 7/40 (18%) of the major CHDs in the *total* population from Phase I and II, in 6/103 (6%) among the minor CHDs. The corresponding numbers for CHDs with associated malformations and normal karyotype were 6/40 (15%) and 11/103 (11%), respectively. Chromosome aberrations and/or associated malformations were present in 7/12 (58%) of the major CHDs prenatally detected, and in 6/28 (21%) of those not detected ( $p = 0.03$ ).

#### Outcome

Of the 12 fetuses with a major CHD detected prenatally during Phases I and II, 9 (75%) were born alive and 5 (42%) were alive after 2 years. Nine CHDs were detected prior to 22 weeks when TOP was an option, and 3/9 (33%) chose to terminate the pregnancy (Trisomy 18, VSD, overriding aorta; Trisomy 21, AVSD; pulmonary atresia, single ventricle complete situs inversus). Of the 28 fetuses with CHD detected postnatally, 26 (93%) were born alive, and 22 (79%) were alive after 2 years. One (4%) of the major CHDs from Phase II not detected prenatally was terminated due to prenatal findings of Trisomy 18. The heart defect, VSD and overriding aorta, was found during autopsy. One intrauterine death was due to associated malformations (hydrocephaly, bilateral pes equino varus, single umbilical artery) and the postductal coarctation of aorta was found during autopsy.

#### Comments:

Detailed structures from the fetal heart imaged by real-time two-dimensional ultrasound were reported as early as in 1980 (Allan *et al.* 1980, Kleinman *et al.* 1980). At that time, pregnancies at increased risk for CHD were offered fetal echocardiography (Callan *et al.* 1991, Allan *et al.* 1994). Since then we have learned that most fetuses and children

with CHD are born to mothers at no increased risk at all (Davis *et al.* 1990, Sharland *et al.* 1990, Callan *et al.* 1991, Allan *et al.* 1994). The second trimester routine examination, offered to most pregnant women, therefore seems like the best opportunity to detect most of the CHDs in the population. Subsequent studies have shown that the four-chamber view of the fetal heart can easily be obtained at this routine scan (Achiron *et al.* 1992, Vergani *et al.* 1992, Sharland and Allan 1992).

Our study showed that the prenatal detection rate of major CHDs at the second trimester examination improved from 18 to 26% when the four-chamber view was obtained in nearly every fetus. Among the 4% where a four-chamber view could not be obtained due to poor imaging or unfavorable position of the fetus (Paper I), three major CHDs were found. At that time a rescan was not a part of the protocol when a four-chamber view was not obtained, unless there was a suspicion of a heart defect. Retrospectively we may conclude that these fetuses represented a high-risk group, as the incidence of major CHD among those 4% was 10/1000 fetuses compared to 4/1000 in the general population. Those CHDs would most likely have been detected with a follow-up, detailed scan; this would have increased the detection rate at the routine scan from 26% to 39%.

In the early nineties, few studies reported detection rates of CHDs from non-selected populations. In two studies from low-risk populations (Achiron *et al.* 1992, Vergani *et al.* 1992) the prenatal detection rates of CHDs after implementation of the four-chamber view varied from 48–81%. Those studies differed with the present study in population selection, gestational age and duration of the routine scan, a rescan if the first failed and shorter postnatal observation time affecting the ascertainment of cases. These differences make the results difficult to compare. One study from a selected population reported a 92% sensitivity of the four-chamber view (Copel *et al.* 1987). However, one should be cautious comparing results from selected populations to non-selected populations, since results from selected populations are influenced by the high incidence of the disease. Despite the differences, a common finding for all the studies was the increase in prenatal detection of CHDs after the four-chamber view was

implemented to the fetal heart examination – which was the desired effect. One may conclude that a detailed evaluation of the four-chamber view is necessary to detect CHDs prenatally.

Of the major CHDs missed at the routine scan (including the three CHDs detected later), 35% would be expected to have an abnormal four-chamber view at that time in the pregnancy (Table 4), thus a four-chamber view was interpreted to be normal when it obviously was not. Several studies have documented that the four-chamber view is difficult to obtain prior to 18 weeks in the pregnancy (Sharland and Allan 1992). In the present study, 41% of those missed had a routine scan at a gestation prior to 18 weeks, which might have affected the ability to interpret the four-chamber view correctly. Two of those scanned prior to 18 weeks (tricuspid atresia; coarctation of the aorta, DIRV) were detected at a later third trimester scan, which supports the experience that the four-chamber view is easier to examine at a later gestation (Copel *et al.* 1987, Achiron *et al.* 1992, Tegnander *et al.* 1994). As the routine fetal examination is a compromise accommodating the various reasons for performing such a scan we rather need to look at ways of improving the scan qualities than at changing the time of its performance. Also, the 22 week upper limit for termination of a pregnancy in Norway requires an anomaly scan prior to 20 gestational weeks.

Evaluation of the four-chamber view can possibly only detect heart defects with an abnormal four-chamber view. CHDs such as TGA, TOF, DORV, mild pulmonary stenosis, mild aortic stenosis, and small VSDs will most likely appear with a normal four-chamber view and thus be missed. For this reason, the four-chamber view is expected to detect 50% of the major CHDs (Allan *et al.* 1986b, Cullen *et al.* 1992). Sharland and Allan (1992) excluded the CHDs with a normal four-chamber view and evaluated the detection rate of CHDs with an abnormal four-chamber view, only. They implemented a teaching program where ultrasonographers from ten obstetric ultrasound units were taught to obtain the four-chamber view. As a result of the teaching program, 77% of the CHDs with an abnormal four-chamber view were prenatally detected. The percentage of four-chamber views not obtained decreased dramatically from 15-20%

and ended with less than 5% in most units. Finally, an increase was found in the number of CHDs detected prenatally because of suspected abnormal four-chamber views at the routine scan. Obviously, the teaching program had an impact on the way the four-chamber view was evaluated. Still, 23% of the CHDs with an abnormal four-chamber view were not detected, emphasizing the difficulties in prenatal evaluation of this view.

Our criteria for a proper four-chamber view were two ventricles of equal size; two atria of equal size; the heart occupying one-third of the thorax area and located in the middle of the thorax with the apex pointing toward the left anterior chest wall. In addition to those criteria, for their teaching program, Sharland and Allan (1992) also evaluated the two atrioventricular valves which meet the atrial and ventricular septa at the crux of the heart in an offset cross-appearance, the presence of the foramen ovale defect in the atrial septum and the appearance of an intact ventricle septum. As the present study reported the detection rate among all major CHDs in the population and Sharland and Allan (1992) among major CHDs with an abnormal four-chamber view, these results are difficult to compare. Still, one may speculate that requiring more details from the four-chamber view forces the examiner to obtain a better image and thus makes it easier to detect CHDs.

Chromosome aberrations and/or associated malformations were found in 32% of the major and in 16% of the minor CHDs. A high percentage of extra-cardiac malformations in CHDs has been reported by others (Berg *et al.* 1988, Copel *et al.* 1988), and the importance of cytogenetic evaluation when a CHD is detected has been emphasized. The presence or absence of extra-cardiac malformations is important for the outcome and thus the counseling process.

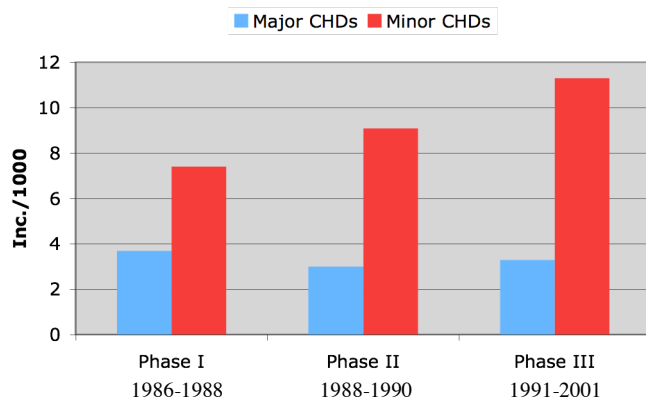
## Paper III

### Prenatal detection of CHDs including the four-chamber view and the great arteries of the fetal heart – detection rates and outcome

#### Detection of CHDs

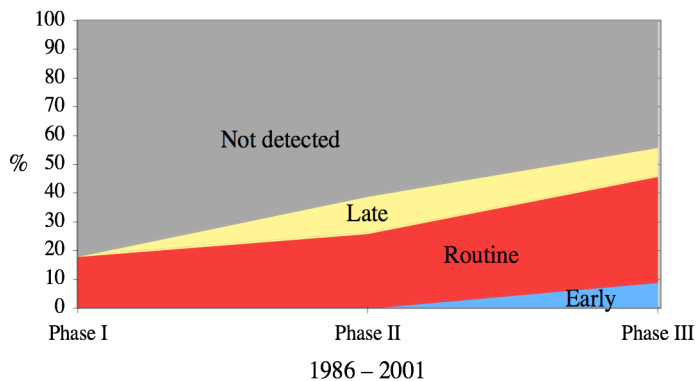
Of the 29,460 fetuses scanned, 97 were found to have a major CHD, 333 a minor CHD. The incidences of major and minor CHDs were 3.3 and 11.3/1000, respectively, making an incidence of 14.6/1000 fetuses in the study population. Figure 17 shows the incidences of major and minor CHDs in the *total* population for the Phases I, II and III.

**Figure 17** Incidences of major and minor CHDs for each phase in the *total* population of 42,381 fetuses.



Of the major CHDs, 55/97 (57%) were detected prenatally: 9/55 (16%) prior to, 36/55 (66%) at, and 10/55 (18%) after the routine scan, respectively. Of all major CHDs in the study population, 45/97 (46%) were detected prior to 22 weeks.

**Figure 18** Major CHDs in a non-selected population of 41,354 fetuses, detection rates and time of detection.



Of the major CHDs classified as complex, 11/14 (79%) were detected prenatally compared to 22/40 (55%) of those classified as simple ( $p = 0.12$ ). Figure 18 shows the percentages of major CHDs prenatally detected for the Phases I, II and III and the time of detection.

Of the 9 fetuses with major CHD detected prior to the routine scan, 5 (56%) had an increased nuchal translucency or cystic hygroma.

Six of the 10 major CHDs detected late in the pregnancy were missed at the routine scan, while four had a first scan at our institution after 29 weeks. Four (67%) of the 6 missed would have had a normal four-chamber view at the 18-weeks scan (2 TOF; TGA; pulmonary valve stenosis).

Isolated CHDs constituted 43/97 (44%) of all major CHDs in the study population, and 19/43 (44%) were detected prenatally. Of the isolated CHDs, 23/43 (54%) were ductal dependent and 11/23 (48%) of those were detected. Of the 24 isolated CHDs missed prenatally, 14 (58%) would be expected to have an abnormal four-chamber view at the second trimester routine scan.

Major heart defects with associated malformations or abnormal karyotype totaled 54/97 (56%). Thirty-six (67%) of them were detected prenatally, a significantly better result compared to the number of major isolated CHDs detected prenatally ( $p = 0.03$ ).

**Table 5** Incidences of isolated VSDs and isolated secundum ASDs per 1000 fetuses for each phase in the *total* population.

Study phase	Population N	Isolated VSDs		Secundum ASD	
		n	Incidence	n	Incidence
I	4,615	18	0.6	5	0.2
II	7,617	51	1.6	7	0.2
III	30,149	192	6.3	39	1.3
Total	42,381	261	6.2	51	1.2

Twelve (4%) of the 333 minor CHDs in the study population were detected prenatally. Of all minor CHDs, 188 (57%) were isolated VSDs and 38 (11%) were isolated

secundum ASDs. Table 5 shows the incidences of isolated VSDs and ASDs in the *total* population for Phases I, II and III.

#### Abnormal karyotype and associated malformations

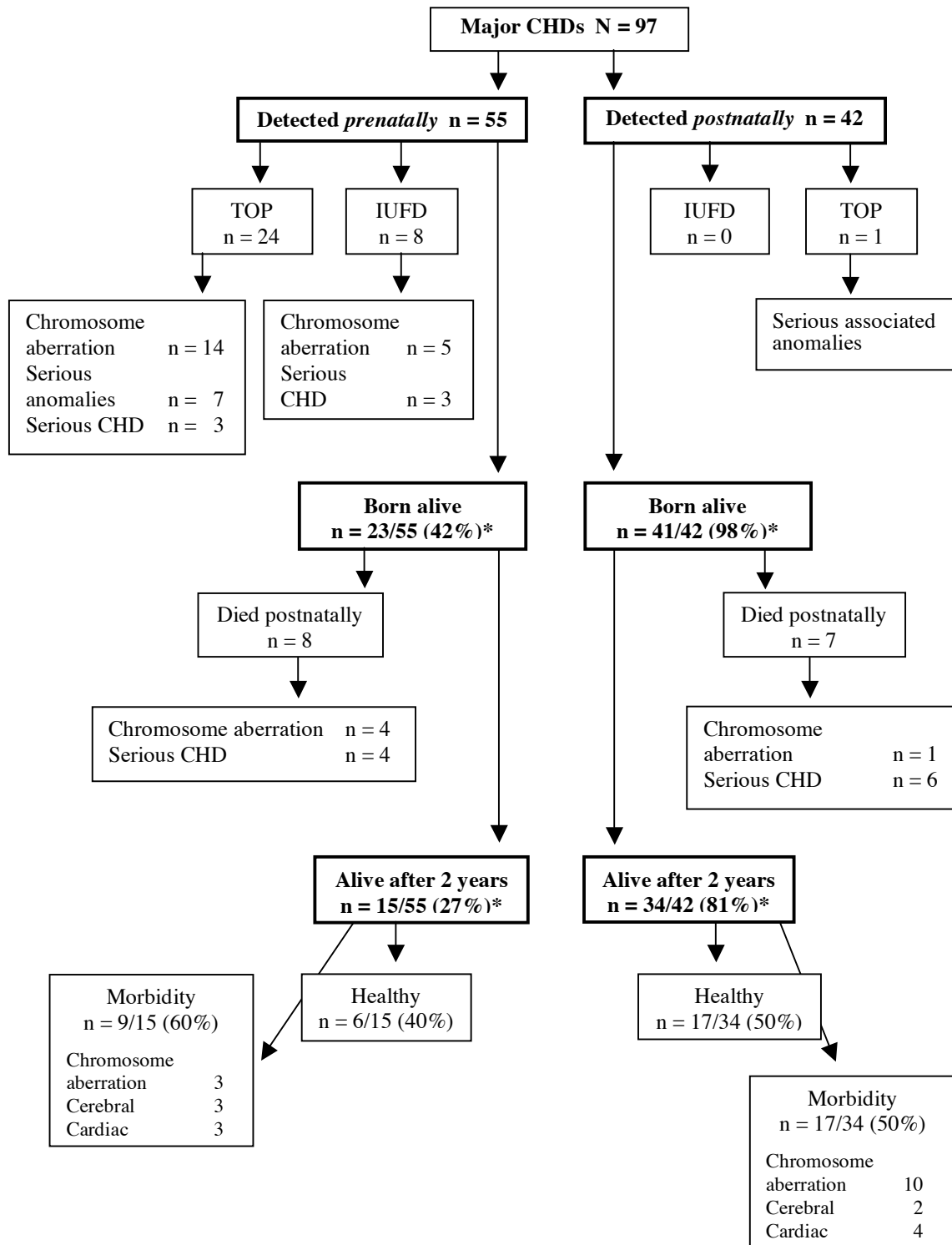
Abnormal karyotype was found in 37 (38%) of the 97 major CHDs. Of the CHDs grouped as complex and simple, 2/14 (14%) and 21/40 (53%) had abnormal karyotype, respectively ( $p = 0.02$ ). Among the 55 CHDs detected, 26 (47%) had an abnormal karyotype and 10 (18%) had associated malformations and normal karyotype. The corresponding numbers for the 42 major CHDs not detected prenatally were 11 (26%) and 7 (17%), respectively. A significant difference was found between the prenatally and postnatally detected major CHDs with associated malformations including abnormal karyotype ( $p = 0.03$ ). Forty-five (82%) major CHDs were detected prior to 22 weeks when termination of the pregnancy was an option. Among the 24/45 (53%) who opted for a termination, 21 (84%) had associated anomalies including abnormal karyotype, compared to 10/21 (48%) of those who continued their pregnancy ( $p = 0.01$ ). Five (63%) of the 8 intrauterine fetal deaths had abnormal karyotype.

Of the 333 minor CHDs, 27 (8%) had abnormal karyotype and 32 (10%) associated malformations. Of the 12 detected prenatally, all had abnormal karyotype or associated malformations.

#### Outcome

The outcomes of the major CHDs detected and not detected prenatally are shown in Figure 19. Intrauterine fetal death occurred in 8/55 (15%) of the fetuses with a major defect detected, but in none of the 42 fetuses with a major defect that was not detected ( $p = 0.01$ ). When the terminated pregnancies were excluded, 23/31 (74%) of the fetuses with a major CHD detected prenatally were born alive compared to 41/41 (100%) of those not detected prenatally ( $p = 0.001$ ). Of the children who survived until two years of age, all were still alive at a median follow-up of six (range 2-13) years.

**Figure 19** Outcome of major CHDs in a non-selected population of 29,460 fetuses.



\*p < 0.001



One of the 12 fetuses with a minor CHD detected prenatally was born alive with a possible genetic defect and a syndrome.

Isolated ventricular septal defects without extra-cardiac malformations totaled 57% (188/333) of the minor heart defects. Of those, 162 (86%) were muscular and 26 (14%) were perimembranous. During the first year of life, 77/162 (48%) of the isolated muscular and 3/26 (12%) of the isolated perimembranous VSDs closed spontaneously.

Comments:

This study showed that inclusion of the great arteries to the fetal heart examination, in addition to the four-chamber view, increased the detection rate of major CHDs at the second trimester routine scan from 26% (Paper II) to 37%, and the total prenatal detection rate from 39% to 57%.

The classification of CHDs seems arbitrary when comparing papers evaluating the prenatal detection of CHDs, making both detection rates and outcome difficult to compare (Cullen *et al.* 1992, Fernandez *et al.* 1998, Bull 1999, Jaeggi *et al.* 2001, Carvalho *et al.* 2002, Wong *et al.* 2003). Even among experts the definition of major CHDs seems to differ, although the majority seem to classify major CHDs as those that will require surgical or interventional treatment during the first year of life (Allan *et al.* 2001). In addition, the evaluation of the severity of major CHDs has changed over time and should be seen in relation to the improvement in postnatal treatment and surgery. In the late-1980s, HLHS was considered a critical and lethal diagnosis and most parents chose to terminate the pregnancy after being counseled about treatment options (Allan *et al.* 1991). With improved surgical techniques (Jacobs *et al.* 1994) HLHS is no longer a CHD without option of postnatal treatment and is thus not considered lethal or critical (Andrews *et al.* 2001, Tworetzky *et al.* 2001, Wilkins-Haug *et al.* 2005). In line with the therapeutic improvements we renamed the two groups of CHDs from critical and non-critical to major and minor, although the definition of the CHDs remained the same through the complete study period.

The study period extended over 11 years. During that time, advanced imaging techniques and diagnostic tools were introduced, making it easier to detect fetal developmental disorders at an early gestation (Blaas *et al.* 1999, Devine and Malone 1999, Schwärzler *et al.* 1999a). Thus, the different use of prenatal tests makes studies evaluating the second trimester routine examination difficult to compare. The 11–13+6 week nuchal translucency screening (Nicolaidis *et al.* 1992) and the development of OSCAR-clinics (One-Stop Clinic for Assessment of Risk) (Nicolaidis *et al.* 2002) result in early detection of major CHDs and consequently a lower incidence of CHDs at the time of the second trimester examination. In one study from a non-selected population, a fetal heart training program was carried out, resulting in a 38% detection rate of major CHDs at the second trimester routine scan (Carvalho *et al.* 2002). Although the result seems similar to ours, 80% of the women in their population had an early scan detecting 20% of the major CHDs which would affect the number of CHDs present at the second trimester scan. Our data also show the same trend. Although nuchal translucency screening is not an offer to the pregnant population in Norway, 9% of the major CHDs were detected prior to the routine scan, changing our previous pattern of prenatal detection of CHDs (Figure 18).

The introduction of the four-chamber view to the fetal heart examination raised high expectations for the detection rate of major CHDs (Copel *et al.* 1987). As the detection rate from second trimester routine scans started to emerge, the results clearly did not meet the expectation of 50% detection (Allan *et al.* 1986b, Sharland *et al.* 1992) but rather between 4.5–48% from non-selected populations (Achiron *et al.* 1992, Ott 1995, Buskens *et al.* 1996, Todros *et al.* 1997). When these studies revealed that the four-chamber view provided poorer results than anticipated, more details of the heart were included rather than question the methods of four-chamber view acquisition. Retrospectively, one may wonder if the potential of this view had been fully utilized (Chaoui 2003b).

With both the four-chamber view and the great arteries included into the fetal heart examination, studies showed that total prenatal detection rates of major CHDs increased

to 40–83% (Achiron *et al.* 1992, Bromley *et al.* 1992, Hafner *et al.* 1998b, Carvalho *et al.* 2002, Wong *et al.* 2003). Our total detection rate of 57% was in accordance with the published data, but the detection rate at the second trimester routine scan, 37%, was still low. The details of the fetal heart are better imaged after 20 weeks (Schwärzler *et al.* 1999b, Allan 2003), thus a scan after 20 weeks would probably make it easier to detect CHDs. With an early scan for nuchal translucency measurements, including dating of the pregnancy, an anomaly scan can be performed at a later gestation (Carvalho *et al.* 2002). Since the 18-week routine scan still is the only ultrasound examination offered to all pregnant women in Norway, efforts have to be made to increase the detection rate of major CHDs at this scan. Also, the upper limit for termination of the pregnancy is 22 weeks in Norway, thus CHDs need to be detected prior to 22 weeks to give the parents this option.

Figure 18 shows data from a period ranging more than 15 years from our large non-selected screened population of 41,354 fetuses and summarizes the prenatal detection of major CHDs through all the three Phases. Since 1986, all pregnant women in Norway have been offered one routine ultrasound examination in the second trimester (Backe and Buhaug 1986), and since then every second trimester scan at our center has been prospectively registered in our database. The data from this database clearly showed that the detection of major CHDs through 1986 and 1987 was poor, only 18% (Paper II). This was the time that the four-chamber view of the fetal heart was introduced, and during Phase II our target was to obtain a four-chamber view in all fetuses scanned. As we started to pay more attention to the fetal heart, the results improved and, as Figure 18 shows, CHDs were even detected in the third trimester when ultrasound scans were done on indications only. An increase in the detection rate to 26% at the routine scan (Phase II) still left most of the major CHDs undetected. Encouraged by the improvement after implementation of the four-chamber view, we added the great arteries to the fetal heart examination to further increase the detection rate. In Figure 18, the improved detection rate as more details of the fetal heart were added to the ultrasound examination is clearly shown. The impact of the second trimester scan is emphasized here, since this is the time that most of the major CHDs were detected, and

the changing pattern in prenatal detection of the defects was observed. The focus on the early scan has resulted in detection of CHDs prior to the second trimester scan, a change that now has to be addressed. Although the focus on the fetal heart examination through many years clearly has resulted in increased detection rates, Figure 18 shows that too many CHDs still are left undetected, clearly challenging our skill to organize and perform the fetal heart examination by ultrasound.

To help in further improving the skills in fetal heart scanning, characteristic findings of the defects detected as opposed to those not detected were sought. When looking at our data, we found that we detected significantly more of the CHDs with abnormal karyotype and/or associated malformations than we detected isolated CHDs. This shows that extra-cardiac malformations seem easier to detect than defects in the heart itself. This has also been found by other investigators (Stoll *et al.* 2002). Only 44% of all isolated CHDs and 48% of the isolated ductal dependent CHDs were detected prenatally, leaving more than one half of the cases undetected. Since the heart is the only affected organ in those cases, we can conclude that the examination of the fetal heart most likely has not been sufficient. Of all the isolated CHDs, we detected 47% with a normal four-chamber view, but, 58% of those we missed were expected to have an abnormal four-chamber view. Thus, a true abnormal four-chamber view was obviously not always recognized. When detection of the complex and the simple CHDs were compared, we detected more of the complex CHDs where the defect was severe than the simple CHDs. This pattern seemed to favor the detection of the more serious defects. Convincing data today show that the outcome seems better for isolated CHDs compared to those with extra-cardiac malformations, especially when prenatally detected (Bonnet *et al.* 1999), thus, efforts have to be made to increase the detection of isolated CHDs. Overall, we may conclude that the fetal heart examination in general is not sufficiently mastered, and more focus has to be put on both the examination of the four-chamber view and the great arteries.

Minor CHDs have been difficult to detect prenatally, especially as isolated defects (Allan *et al.* 1989). In our series, we did not detect minor CHDs in Phase I or II (Paper

II), but 12 (4%) minor CHDs were detected in the present study (Phase III). One may speculate whether improved ultrasound skills and knowledge over time have resulted in detection of those minor defects, or if it was the extra-cardiac malformations rather than the heart itself that was the reason for the detection (Hafner *et al.* 1998b). The real importance of detecting those minor CHDs may be questioned, unless they are associated with a chromosome aberration.

Published data show a strong association between CHDs and extra-cardiac malformations (Copel *et al.* 1988, Schwanitz *et al.* 1990, Allan *et al.* 1994, Carvalho *et al.* 2002, Stoll *et al.* 2002), emphasizing the importance of cytogenetic evaluation when CHDs are prenatally detected (Berg *et al.* 1988, Paladini *et al.* 1993). In the present study, as much as 38% of the major CHDs had abnormal karyotype and 17% associated malformations and normal karyotype. One large population-based study, the Baltimore-Washington Infant Study, found only 12% chromosome aberrations among live born infants (Ferencz *et al.* 1989). As we know that fetal populations include stillbirths and terminations of pregnancies where the incidence of CHDs associated with extra-cardiac malformations is high (Chinn *et al.* 1989, Tennstedt *et al.* 1999), a comparison between a fetal and an infant population will not be correct (Allan *et al.* 1994). When the results from the Baltimore-Washington Infant Study were adjusted for the effect of intrauterine lethality, the risk of aneuploidy for a fetus detected with CHD at the routine scan was found to be close to 40% (Berg *et al.* 1988), which is in accordance with the findings from the present study. Our data also showed a significantly higher association of chromosome aberrations among simple CHDs compared to complex CHDs, emphasizing the importance of detecting those simple CHDs. The results challenge our ultrasound skills as we detected significantly more of the complex than the simple CHDs.

The tendency to detect the most severe CHDs prenatally also reflects the outcome (Montaña *et al.* 1996, Boldt *et al.* 2002). As shown in Figure 19, the outcome was significantly better for the children where the heart defect was detected after birth, which supports previous findings (Allan *et al.* 1994, Bull 1999). The significantly

higher number of associated malformations and/or abnormal karyotype among the prenatally detected CHDs emphasizes the seriousness of those defects. The risk for spontaneous intrauterine death has been shown to increase in chromosomally abnormal fetuses (Hoffman 1995b). The fact that intrauterine fetal death occurred in 15% of the fetuses with a CHD detected prenatally (of which 63% had a chromosome abnormality), compared to zero fetal deaths among the postnatally detected, underlines the difference in seriousness between these two groups also in the present study. The same tendency was found among the terminated pregnancies where 58% of the fetuses had associated lethal chromosome aberrations or had developed a life-threatening condition at an early gestational age, and the rest, except for the Trisomy 21 cases, were severe anomalies requiring major surgery.

During recent years the prenatal detection of CHDs has improved and a trend towards more survivors has been found (Copel *et al.* 1997, Bonnet *et al.* 1999, Tworetzky *et al.* 2001, Brick and Allan 2002, Franklin *et al.* 2002). Those findings are encouraging in our effort to further increase the number of prenatally detected CHDs. With new surgical options and results, the long-term follow up will be of importance to give the best possible counseling when a major CHD is detected at the routine scan (Allan and Huggon 2004).

Despite years of persistent attempts to increase the prenatal detection rate at the second trimester routine examination, the fetal heart remains the most difficult organ to examine. Once prenatally diagnosed, the chance to survive until 2 years of age was only 27%, compared to 81% for those who were not detected prior to birth. The difficulties in showing improved outcome in prenatally detected CHDs may reflect the nature of the fetal cardiac disease that often is severe and with associated malformations (Yates 2004), as demonstrated in our study. Prenatal studies also tend to include those heart defects that have not been included in postnatal series because of death prior to surgery and a post-mortem diagnosis, influencing the outcome data (Abu-Harb *et al.* 1994, Yates 2004). In our effort to detect more of the major CHDs prenatally, we also need to focus on detecting these serious defects as early in the pregnancy as possible to allow

parents the choice of termination of the pregnancy (Allan and Huggon 2004). Also, when the pregnancy is continued, prenatal diagnosis will ensure optimal perinatal management and may influence the long-term morbidity (Eapen *et al.* 1998, Mahle *et al.* 2000, Yates 2004).

The largest studies reporting on the incidence of CHDs from the 1970s and 1980s reported incidences between 8–9/1000 live births (Mitchell *et al.* 1971, Hoffman and Christianson 1978, Ferencz *et al.* 1985, Carlgren *et al.* 1987, Šamánek *et al.* 1989). Congenital heart disease is by definition cardiovascular disease present at birth, but the true postnatal incidence may be difficult to assess due to several factors, for instance unrecognized CHD in early infant deaths (Abu-Harb *et al.* 1994, Hoffman 1995a). With prenatal diagnosis of CHDs, termination of pregnancies will also affect the incidence in a live born population (Saari-Kemppainen *et al.* 1990, Allan *et al.* 1991).

In fetal populations, the incidence of CHD is found to be higher than in live born populations (Rosendahl and Kivinen 1989, Hafner *et al.* 1998b). This may be due to the higher incidence of malformations in general in spontaneous abortions and stillbirths (Mitchell *et al.* 1971, Chinn *et al.* 1989). Figure 17 shows the increase in the overall incidence of CHDs in the present study from 11.1/1000 in Phase I to 14.7/1000 in Phase III. Interestingly, the incidences of major CHDs, 3–4/1000, were consistent and in accordance with the reported incidence of major CHDs (Ferencz *et al.* 1985). This emphasizes that the overall high incidences are not due to selection biases. The development of advanced ultrasound techniques has made it possible to detect minor CHDs today not detectable some years ago, either prenatally or postnatally. This is clearly demonstrated in Table 5 as both the incidence of isolated VSDs and ASDs have increased over time and are probably responsible for the increase in the incidence of minor CHDs during the last few years (Meberg *et al.* 1994, Roguin *et al.* 1995, Wren *et al.* 2000). It may be questioned whether these minor defects are true heart defects and not just a delay of a normal closure process towards the end of the pregnancy (Ben-Shachar *et al.* 1985, Hiraishi *et al.* 1992). The fact that none of these children needed treatment and that approximately 50% of the isolated VSDs closed spontaneously after

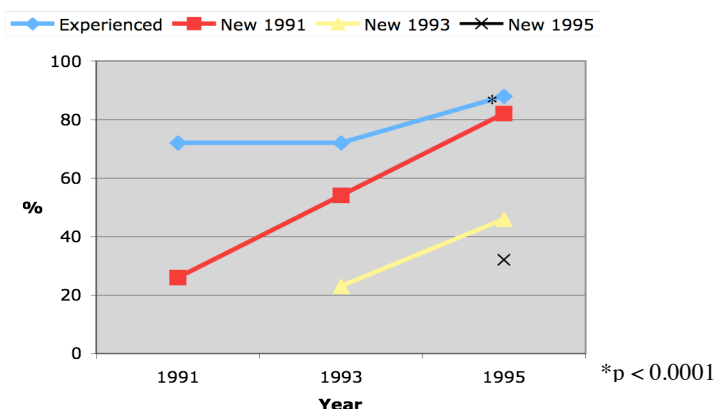
birth, indicate that we are observing a physiological process rather than pathology (Radzik *et al.* 1993, Meberg *et al.* 1994, Roguin *et al.* 1995, Helgason and Jonsdottir 1999).

## Paper IV

### Comparison between experienced and less experienced sonographer/midwives in obtaining fetal heart structures and detecting CHDs prenatally

During the study period, 29,035 fetuses had a second trimester routine examination performed by a sonographer/midwife. There was no difference in the experienced and less experienced midwives' ability to obtain the four-chamber view at the routine scan (97%). Significant differences were found when the ability to obtain the ascending aorta (85% and 66%, respectively), the pulmonary artery (78% and 36%, respectively) or both arteries (75% and 36%, respectively) was evaluated ( $p < 0.001$ ). Figure 20 shows the ability to obtain both the four-chamber view and the great arteries over time for the five experienced sonographer/midwives and the four less experienced sonographer/midwives who were new in this work in 1991, 1993 and 1995. A significant increase in the ability to obtain both views were found among the new, less experienced sonographer/midwives during the period from 1991 – 1995.

**Figure 20** The ability to obtain the four-chamber view and the great arteries in 2994 fetuses, over time, for the experienced sonographer/midwives and the less experienced sonographer/midwives who started in 1991, 1993 and 1995, respectively.





Of the 82 major CHDs in the study population, 35 (43%) were detected at the routine examination. The experienced sonographer/midwives detected 22/42 (52%) and the less experienced 13/40 (33%) ( $p = 0.07$ ). Of the CHDs grouped as isolated, the detection rates were 8/18 (44%) and 6/22 (27%), respectively ( $p = 0.26$ ), and for the CHDs with associated malformations 14/24 (58%) and 7/18 (39%), respectively ( $p = 0.21$ ).

Of the 82 fetuses with a major CHD, 36 (44%) had a routine scan prior to 18 weeks. Of those, the experienced sonographer/midwives detected 11/22 (50%) of the CHDs prenatally, the less experienced 6/14 (43%). Of the 46 fetuses with a major CHD scanned after 18 completed weeks, the corresponding numbers were 11/20 (55%) and 7/26 (27%), respectively ( $p = 0.05$ ).

Fifty-eight (71%) of the 82 major CHDs would be expected to have an abnormal four-chamber view at the time of the routine scan. Of these, 34/58 fetuses were examined by experienced sonographer/midwives and 28 (88%) of the abnormal views were recognized. The corresponding number for the less experienced sonographer/midwives was 13/26 (50%) ( $p = 0.002$ ).

Of the isolated CHDs missed at the routine scan, 16/26 (62%) would be expected to have an abnormal four-chamber view: the experienced sonographer/midwives missed 5/10 (50%) and the less experienced 11/16 (69%). In 3/47 (6%) of the major CHDs missed, the sonographer/midwives had suspected a malformation at the routine scan, but the finding was not interpreted as pathology by the consulted physician. Nineteen (40%) of the 47 CHDs missed had a routine scan prior to 18 completed weeks.

Among the 19,237 fetuses scanned between 1995 and 2001, the percentage of fetuses with a four-chamber view not obtained at the second trimester routine examination decreased per year from 2.4% in 1995 to 1% in 2001. Unfavorable fetal position (41%) and poor imaging (40%) were the main reasons why the four-chamber view could not be obtained.

#### Comments:

The recent advances in ultrasound technology have placed great responsibility on the ultrasound operator. The different ultrasound techniques allow the operator to examine the fetus in more detail and to survey the fetus in better ways than only a few years ago (Eik-Nes *et al.* 1982, Eik-Nes 1993b, Blaas 1999, Hofstaetter *et al.* 2002, Brantberg *et al.* 2004). Proper training is necessary to utilize the potential of the ultrasound machine and to keep up with the new information, techniques and the development in the field of obstetric ultrasound.

Post-graduate ultrasound education and ultrasound courses are available in many countries, but are not mandatory for those who work with diagnostic ultrasound. With no requirements of education, it is the ultrasound operators' responsibility to realize their own need for training. This has resulted in a large variation of background knowledge and experience among those working with obstetric ultrasound. Each sonographer/midwife in the present study received three months of basic ultrasound training, including a one-week basic theoretical course in addition to a minimum of 200 ultrasound scans supervised by an experienced sonographer/midwife.

The analysis of our results showed that 62% of the isolated major CHDs missed prenatally were expected to have an abnormal four-chamber view. Other studies also show that too many CHDs with an abnormal four-chamber view were missed (Wong *et al.* 2003). Although the detection rates increased when the great arteries were obtained, the detection rates did not reach the expected numbers for the four-chamber view alone (Stoll *et al.* 1998, Hunter *et al.* 2000). The lack of increase in the detection rate when more views were included into the fetal heart examination may indicate that other factors ought to be addressed.

Our study showed that experience played a significant role when it came to obtaining the fetal heart structures. In the mid-eighties, when the four-chamber view was introduced (Fermont *et al.* 1985, Allan *et al.* 1986b), studies demonstrated that this view could easily be incorporated into the fetal heart examination at the routine scan as it was

obtained in more than 95% of the fetuses (Copel *et al.* 1987, Achiron *et al.* 1992, Vergani *et al.* 1992, Tegnander *et al.* 1994, Todros *et al.* 1997). The same tendency was found in the present study where the four-chamber view was obtained in 97% of the fetuses. No difference was observed between the experienced and the less experienced sonographer/midwives, thus the four-chamber view seemed like an easy view to obtain no matter the degree of experience.

On the other hand, when we look at the isolated CHDs missed prenatally, 62% were expected to have an abnormal four-chamber view at the time of the routine scan. One may speculate if the four-chamber view had actually been properly obtained, and if so, whether it then had been correctly interpreted. Both the technique to obtain a correct four-chamber view and the way it is interpreted are a consequence of basic learning and experience. Ultrasound experience did seem to be of importance when it came to interpreting the view, as the experienced sonographer/midwives recognized significantly more of the expected abnormal four-chamber views than did the less experienced sonographer/midwives. But, the experienced sonographer/midwives also missed CHDs with abnormal four-chamber views, emphasizing the need for extra focus on this basic view (Chaoui 2003b).

The success in obtaining the sonographic views of the great arteries seemed to be more dependent on experience than on the ability to obtain the four-chamber view. The differences between the experienced and the less experienced sonographer/midwives were significant, and the main pulmonary artery seemed like the most difficult vessel to obtain. Since this registration was carried out, the three-vessel view has been introduced as an easy view to obtain the great arteries (Yoo *et al.* 1997), which may affect the way the great arteries are imaged today. Still, the significant difference between the sonographer/midwives clearly demonstrated the importance of experience. Even the experienced sonographer/midwives showed improvement of their results, most likely due to the extra focus on the four-chamber view and the great arteries (Figure 20). Thus, intensive focus and training on the examination of the fetal heart seem to be needed for all categories of ultrasound personnel. The poor detection rates of CHDs reported from

non-selected populations (Crane *et al.* 1994, Buskens *et al.* 1996, Bull 1999, Garne *et al.* 2001) may indicate that the basic training has not paid enough attention to the teaching of the four-chamber view and the great arteries of the fetal heart, and that there is potential for improvement.

Statistically, the differences found between the experienced and the less experienced sonographer/midwives were not all significant, but the consistent trend between them does suggest a difference. A comparison of the experienced sonographer/midwives' ability to detect major CHDs to the less experienced sonographer/midwives' results showed that the experienced personnel did better. When breaking the CHDs down to isolated CHDs, ductal dependent CHDs and CHDs with associated malformations including abnormal karyotype, we found the same tendency, i.e. that the experienced sonographer/midwives did better than the less experienced sonographer/midwives. Because heart defects are low in number, a background population of three times the size of our population, approximately 100,000 fetuses, would be needed to reach a level of significance given the same detection rates. However, the experienced sonographer/midwives did significantly better in obtaining both the four-chamber view and the great arteries – details necessary for the detection of CHDs. In addition, the experienced sonographer/midwives' ability to recognize an abnormal four-chamber view was significantly better than that of the less experienced sonographer/midwives. The significant improvement in the ability to obtain fetal heart structures over time also emphasizes the difference between the experienced and less experienced sonographer/midwives.

The gestational age may be of importance for the detection of CHDs. Several studies have shown that the fetal heart structures are more difficult to image prior to 18 weeks than after 18 weeks (Schwartzler *et al.* 1999b). As much as 40% of the fetuses with a major CHD missed prenatally in the present study had a routine scan performed prior to 18 completed weeks. According to published data, some of these might have been detected if the ultrasound examination had been carried out at a later gestation (Allan 2003). The results from Paper I demonstrating a higher success in obtaining the four-

chamber view after 18 weeks, still seem to be valid. Despite the advances in technology, it is interesting to notice that those offering both an early and second trimester ultrasound examination prefer to do the second trimester anomaly scan between 20-24 weeks (Gembruch *et al.* 1993, Zosmer *et al.* 1999, Rustico *et al.* 2000). It is worth noting, though, that the gestational age most likely is only one of several factors involved in the poor detection of CHDs. There were no differences between the experienced and the less experienced sonographer/midwives when it came to detecting CHDs prior to 18 weeks of gestation, but the difference was significantly better for the experienced sonographer/midwives after 18 completed weeks. It may be that the less experienced sonographer/midwives had problems detecting the CHDs no matter what the gestation, and that experience still is important even at later gestations.

To further improve the results, it has been suggested that additional views of the fetal heart and new modalities be incorporated to the fetal heart examination (Yoo *et al.* 1997, Chaoui and McEwing 2003). Adding the great arteries to the four-chamber view clearly increased the detection rate in the present study. The present study also showed that the ability to obtain the four-chamber view at the routine scan increased to 99%, but still too many CHDs with an abnormal four-chamber view were missed. Clearly, the four-chamber view was evaluated as normal when it was not. Also, too many CHDs with a normal four-chamber view were missed, underscoring that the examination of the great arteries was not sufficiently mastered. It may be that the potential of including the great arteries can not be fully exhausted as long as the four-chamber view is not properly mastered. The stepwise introduction to the fetal heart examination, suggested by Allan in 1986, still seems to be fundamental to the success in fetal heart scanning. The first step, the four-chamber view, should be mastered before the next step is considered (Allan 1986, Sharland 2004). Adding even more views to the fetal heart examination may not give the expected results as long as the basic views have not been properly learned.

The present study emphasizes the importance of dedicated personnel performing the obstetric ultrasound examinations, as experience seems crucial for the detection of

defects, specifically of the fetal heart. In most non-selected populations, sonographers with basic ultrasound training are performing the routine examinations. After years working with ultrasound, sonographers develop an awareness to pathology gained from intensive experience (Cullen *et al.* 1992). This was also shown in the present study as three true CHDs were suspected by the sonographer/midwives, but later evaluated as normal by the consultant physician. It takes years to develop this experience; thus, fetal ultrasound examinations should be performed by personnel specifically trained in obstetric ultrasound (Cullen *et al.* 1992). Non-dedicated personnel will probably not get enough experience and will, over time, remain less experienced ultrasound personnel.

The long learning curve to become experienced in fetal heart scanning may be shortened by a more focused education on the four-chamber view and the great arteries. The educational and training systems today expect the sonographers to build up their experience through a high number of ultrasound examinations following their training. The busy schedule most sonographers are faced with does not give much room for developing scanning skills; this is demonstrated by the long learning curve. Since studies have shown that the fetal heart is more difficult to examine than other fetal organs (Stoll *et al.* 2002a, Levi *et al.* 2003), the educational sites have to accept that the heart needs more focus during the time of education. With a better basic learning process, the learning curve may increase faster.

What have we learned during the 20 years since the sonographic appearance of the fetal heart and the subsequent demand for increasing the detection rates of CHDs? During all these years the ultrasound equipment has improved significantly, making it easier to obtain the details of the fetal heart, but also requiring more technological knowledge from the ultrasound operator. Already in the late eighties (Paper II, Phase II) we demonstrated the importance of utilizing the correct equipment when examining the fetal heart: using a 5 MHz transducer gave a significantly better image of the four-chamber view than the 3.5 MHz transducer. Although most modern ultrasound machines are equipped with multifrequency transducers, a proper image of the fetal heart still requires the ultrasound operator's knowledge and awareness of correct use

and adjustments of the ultrasound machine; these need to be optimized for the imaging of the fetal heart.

In continuation of the discussion on equipment, the poor detection rates of CHDs may also be a result of old and poor ultrasound equipment. The fact that most of the fetuses with CHD are found in non-selected populations (Allan *et al.* 1994, Maher *et al.* 1994, Carvalho *et al.* 2002, Åmark *et al.* 2004) means that the detection of fetuses with CHD needs to be done in the routine setting. This scan is often the only opportunity to detect CHDs prenatally, as ultrasound examinations later in the pregnancy often are done on indications only. If the ultrasound machines used during the routine scan are of poor quality, this may affect the detection rate of defects. This is an organizational issue that should be addressed by each ultrasound department.

Experience is of importance for the detection of CHD (Cullen *et al.* 1992, Hunter *et al.* 2000, Carvalho *et al.* 2002, Wong *et al.* 2003). When the four-chamber view was introduced and evaluated (Paper II, Phase II), a significant improvement in the ability to obtain this view was observed over time. The same results were found in the present study with the introduction of the great arteries. For both periods, the learning curve was relatively long, despite better ultrasound equipment during the present study. Thus, good equipment is not the only answer to better imaging of the heart; experience must also be considered. The experienced sonographer/midwives were superior to the less experienced sonographer/midwives in obtaining details and detecting defects of the fetal heart. Thus, if only experienced sonographer/midwives performed the routine examinations, one would expect a further increase in the prenatal detection rate of major CHDs. The opposite situation is often the reality in ultrasound departments. Experienced sonographer/midwives tend to end up with administrative work while less experienced sonographer/midwives are left on their own to do the majority of the scans to gain experience. Since there always will be a need for recruitment of new personnel, the basic education must focus on the need for more experience in fetal heart scanning.

To provide the best possible fetal heart scans, we must apply quality assurance to the work we do. This has already been addressed by the Fetal Medicine Foundation in London. The Fetal Medicine Foundation requires minimum standard for the ultrasound examination, and has shown the potential of nuchal translucency measurement in detecting developmental disorders when this measurement is performed with a high degree of accuracy and quality assessment (Nicolaidis *et al.* 1999). The importance of complying with a detailed procedure when measuring the nuchal translucency has been encouraged in numerous courses around the world to ensure that this accurate and standardized method is followed. Multiple series have shown that focusing on nuchal translucency measurements as taught by the Fetal Medicine Foundation has good results (Hafner *et al.* 1998, Hyett *et al.* 1997, Schwärzler *et al.* 1999). This way of standardization and assessment of nuchal translucency measurements probably also applies to other aspects of the fetal examination. Based on results from the present study there is reason to believe that a standardized procedure for the fetal heart examination should be given increased focus. Images of the nuchal translucency that do not follow the standardized method are not accepted by the Fetal Medicine Foundation quality assessment system. There is no such quality check when it comes to images from the fetal heart. If the examination of the four-chamber view with all its details described 20 years ago (Allan 1986) had been followed up by the same rules and quality assessment as for the nuchal translucency measurement, this would most likely have made a great impact on the examination of the fetal heart and thus the detection of CHDs.

Experience shows that it takes time to learn the ultrasound technique in general. As a consequence, most post-graduate ultrasound educational programs last for a minimum of one year. During that year, the basic ultrasound technique has to be learned and the ultrasound images must be understood and correctly interpreted. Obtaining correct images is dependent on the operator's understanding and mastering of the ultrasound technique. The poor detection rates reported on CHDs may suggest that the basic technique has not been properly understood and learned. The educational sites' future focus should be on each ultrasound operator's skills to obtain and interpret sections through the fetal heart; time must be allowed for necessary maturation of these



ultrasound skills. The technique to obtain the correct four-chamber view and the interpretation of all the details from this view have to be mastered before the great arteries are added. As the basic ultrasound education includes a range of different subjects to be learned, the great arteries may be introduced through additional ultrasound courses following the first year of training, perhaps as an obligatory extension of the basic education.

## **Paper V**

### **Introduction of three-dimensional ultrasound imaging of the fetal heart (TDOG)**

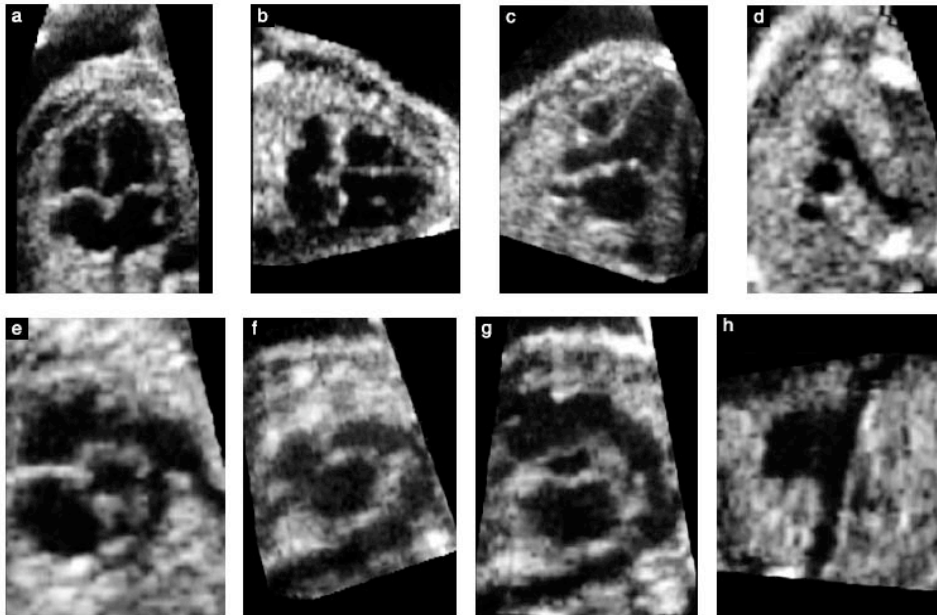
A new 3D technique utilizing tissue Doppler as a gating signal was introduced. The purpose of this technique was to see if structures in the fetal heart could be more easily obtained and imaged than was possible with the conventional 2D ultrasound technique. The images were of adequate quality for four of the eight fetuses examined. Two fetuses showed several motion artifacts and for two fetuses there was no adequate access to the four-chamber view during the scanning time. To cover the fetal heart with maximal diameter of 2 cm at a depth of 5–7 cm, a scanning angle of approximately 25° showed good agreement between the B-mode and a planar slice.

The best image quality of the 3D reconstruction was achieved by a compromise between high B-mode quality and high frame rate. Second harmonic imaging gave the highest lateral resolution and was used on all recordings. As for the gating signal, cardiac motion could positively be used, even when the motion was not visible within the B-mode image. The basic signal used for the tissue Doppler synchronization emphasized strong echoes and massive motion of tissue in the ultrasound beam direction.

The variation in the quality of the reconstructions between different recordings were mainly due to fetal position not suitable for high-quality B-mode imaging of the fetal heart, fetal movements during the sweep and uneven probe motion during the sweep.

Figure 21 demonstrates reconstructed volume projections of the heart from a 24-week fetus. All images were retrospectively produced from one cine loop of 3D data, derived by apical insonation.

**Figure 21** Volume projection of the heart of a 24 weeks fetus. a) Apical four-chamber view. b) Subcostal four-chamber view. c) Ascending aorta. d) Three-vessel view. e) Short-axis view of the great arteries. f) Aortic arch. g) Ductal arch. h) Long-axis view of inferior and superior venae cavae.



Comments:

Dynamic 3D imaging of the fetus has received increasing interest during the past few years (Hata *et al.* 1998, Pöhls and Rempen 1998). This may be a natural result of the rapid development of technology and imaging modalities to meet the demand of increased image quality and thus the information derived from those images. The interest for dynamic 3D imaging of the fetal heart may also be a result of poor detection rates of major CHDs and the recognition of the fetal heart as a difficult organ to examine with 2D ultrasound imaging (Chaoui 2003b, Sharland 2004).

The acquisition techniques with 3D ultrasound imaging have been difficult, and different approaches have been investigated, such as using both gated and non-gated B-mode reconstruction techniques (Merz *et al.* 1995, Sklansky *et al.* 1998) or real-time 3D acquisition using a 2D array transducer (Deng *et al.* 2002a). Different gating techniques

have also been studied, including operator input based on an M-mode display (Deng *et al.* 1996), temporal Fourier transforms of the volume data itself (Sklansky *et al.* 1998) and Doppler spectrum acquisition and analysis performed by an independent ultrasound system (Deng *et al.* 2000, Deng *et al.* 2002b). The spatio-temporal image correlation (STIC) technique has been used to produce 3D gray scale images with the gating signal automatically detected from the underlying B-mode sequence (Devore *et al.* 2003, Viñals *et al.* 2003), and to reconstruct 3D color Doppler images (Chaoui *et al.* 2004, Gonçalves *et al.* 2004). 3D images of the fetal heart have also been obtained by free-hand scanning gated with cardiotocography (CTG) (Herberg *et al.* 2003).

The current study looked into another approach, using 2D tissue Doppler from the fetal heart to generate the gating signal (TDOG). Tissue Doppler has been used for clinical application since 1989, first described by Isaz *et al.* (1989) to measure the low velocity motion of the left ventricular posterior wall. The higher velocity in blood than in other tissue during normal circumstances results in a lower Doppler shift from the myocardial wall than in blood. The tissue signal will have a stronger amplitude because of more scatter returning from tissue than from blood. Thus, the tissue Doppler signal can be recorded either by low pass filtering or gain damping, or with a combination of both (Brodin 2004). For the TDOG method, those strong tissue Doppler signals could positively contribute to the gating signal.

Spatial and temporal tracking, or gating, is usually preferred when 3D images are to be acquired *in-utero*, during which fetal movements, maternal respiration or probe-induced movements often occur (Deng 2003). Nongated cardiac imaging generates a single volume that mixes together several parts of the cardiac cycle, resulting in suboptimal accuracy and resolution; the gated techniques have shown to improve the resolution of image planes generated from volumetric data (Sklansky *et al.* 1998). Electrocardiogram used for gating in 3D echocardiography in infants, children and adults has been difficult to achieve in fetuses, although gating by cardiotocography in the fetus has been attempted (Herberg *et al.* 2003).

The disadvantages of using two different systems are the inconvenience of two devices, in addition to possible artifacts caused by acoustic interference between the transducers (Deng *et al.* 2000, Downey *et al.* 2005). Such acquisition artifacts were noted during the present study when Doppler CW data were recorded simultaneously with the tissue Doppler for quality assessment. To ease the use for clinical setting, the gating signals should be easy to obtain, accurate and technically reliable. With the TDOG-method, tissue Doppler data can be acquired simultaneously and with the same transducer as the B-mode data, allowing the recording of tissue Doppler data as part of a gated 3D scan.

Handheld sweeps allow the sonographer to make fine adjustments during the sweep to minimize acoustic shadowing, but the image quality depends largely on how smoothly and steadily the transducer is moved (Downey *et al.* 2000, Sklansky 2004). A long sweep yields a high scan plane density as a high number of consecutive cine-loops become neighboring planes in the 3D dataset. However, too long a sweep makes it difficult to perform the sweep with constant tilt velocity. A method in which the transducer is kept stationary and electronic scanning with a 2D array processes the echoes to generate 3D information may be an alternative to freehand systems (Downey *et al.* 2000), used for the STIC technique (DeVore *et al.* 2003, Viñals *et al.* 2003). However, the STIC-technique is a post-processing technique and does not allow 3D in real-time scanning, i.e. 4D scanning.

Acquiring volumetric data within a few seconds from a single window, with the possibility of a retrospective visualization of the heart in a multiplanar display is of interest. Such a procedure reduces the scanning time, is independent of the experience of the ultrasound operator, allows reconstruction of standardized fetal echocardiographic views without the pregnant woman present, and allows 2D reconstruction of views from the fetal heart not accessible by regular 2D B-mode imaging (Budorick and Millman 2000, Sklansky 2004). On the other hand, there are also limitations to 3D ultrasound. The present study showed that important factors for an optimal and useful recording were: no bone shadows or other disturbances in front of the fetal heart, the heart positioned within a certain distance from the ultrasound

transducer (ideally less than 6 cm), and no fetal or respiratory motion during the sweep time. These limitations well known from 2D ultrasound (DeVore *et al.* 1993, Hendler *et al.* 2005), also recognized from 3D imaging (Budorick and Millman 2000, Hull *et al.* 2000, Abuhamad 2005), should be expected, as long as the 3D reconstructions are based on 2D recordings.

Performance of the 3D scan by less experienced ultrasound personnel may be questioned. Difficult fetal position, which can affect the acquisition of the data, can be dealt with by using an alternative insonation angle gained through experience. Data from Paper IV show that it takes time and experience to obtain adequate images of the fetal heart needed for 3D reconstruction. In addition, the acquisition, display and manipulation of 3D volumes require experience (Abuhamad 2005). Thus, as the utilization of the multiplanar review may be time-consuming, the timesaving factor may not be obvious (Budorick and Millman 2000). Standardization in the acquisition and display of 3D volumes may ease the training process (Abuhamad 2005).

There are advantages and disadvantages with both 2D imaging systems and 3D imaging systems. Some will remain the same for both imaging modalities as long as 2D images are acquired to reconstruct 3D images. The present paper demonstrated the weakness of the ultrasound system due to poor resolution when the perimembranous part of the ventricle septum was to be imaged from an apical view of the heart. The nature of ultrasound physics cannot be overruled, thus one single 3D ultrasound insonation angle will not give an optimal image quality of all structures, regardless of resolution. A typical example would be the imaging of the ventricular septum. In the apical view using 3D ultrasound, it still would appear very thin (Figure 21), whereas in the long-axis view, true imaging of the texture and thickness would be appropriate.

Today most 3D ultrasound images represent a compromise between the optimal diagnostic perspective (large data set, higher-resolution 3D images) and what the computers actually are capable of processing (Downey *et al.* 2000). With the increased

clinical use of 3D ultrasound and further advances in computer technology, 3D ultrasound may play an important role in obstetric ultrasound.

## **SUMMARY**

### **Background**

The second trimester fetal ultrasound examination has become an integrated and important part of prenatal care. One of the aims of this scan is to detect developmental disorders which might have consequences for the management of the pregnancy and the neonatal period. The fetal heart has received particular attention, as heart defects seem difficult to detect prenatally and data show when CHDs are prenatally detected, that the outcome improved. As a teaching institution, our focus has been on improvement in the fetal heart examination. The knowledge about what kind of CHDs we do and do not detect is of importance in order to understand why we fail to detect CHDs and to learn about the next steps needed to improve the results.

### **Purpose**

The objectives of the studies were to implement and prospectively evaluate new examination procedures of the fetal heart at the second trimester routine examination, in order to increase the prenatal detection rate of CHDs (Papers I, II, III and V). The training and experience of the ultrasound personnel were evaluated to see if educational aspects were factors that would have influence on the prenatal detection of CHDs and to evaluate current ultrasound-training programs (Paper IV). Finally, the CHD cases were followed into the postnatal period to get a better understanding of the outcome, in order to improve the basis and the accuracy for our counseling once the defects are detected (Papers II and III).

### **Material and methods**

A well-defined non-selected population of 42,381 fetuses was prospectively studied from August 1986–December 2001. Of those, 41,354 (98%) received an ultrasound examination at our hospital and formed the study population (Papers I, II, III and V). The second trimester routine ultrasound examinations were scheduled at 18 completed weeks and were mainly performed by specially trained sonographer/midwives. In Paper

IV, these sonographer/midwives were grouped as experienced or less experienced and constituted the study population.

During the regular second trimester routine scan, the four-chamber view was incorporated into the fetal heart examination (Papers I and II), and later the views of the great arteries were added (Paper III). Starting in 1995, a new scan was offered at approximately 20 weeks of gestation if a proper four-chamber view had not been seen at the routine examination (Papers III and IV). In 8 of these fetuses, a new method to image the fetal heart, Tissue Doppler gated (TDOG) 3D ultrasound, was evaluated (Paper V).

A heart defect was retrospectively classified as major or minor after a final diagnosis was achieved. The major CHDs were grouped as isolated; abnormal karyotype; associated malformations (Papers III and IV). Fetal karyotyping was offered in all prenatally detected cases. Every fetus/child was followed-up to ensure outcome data. The longest period of follow-up for the live-born children was 13 years (Paper III).

## Results

A four-chamber view of the fetal heart could be obtained in 96% of the fetuses at 18–21 weeks of gestation, the time of the second trimester routine scan. Prior to 18 weeks, the results were poorer. The results with a 5 MHz transducer were significantly better than with a 3.5 MHz transducer. A significant improvement in the ability to obtain the four-chamber view was noticed over time for the sonographer/midwives performing the ultrasound examinations (Paper I).

Introducing the four-chamber view into the routine examination increased the detection rate of major CHDs at that scan from 18 to 26% (Paper II). By adding the views of the great arteries, the detection rate further increased to 39% (Paper III). During this last period (Paper III), 9% of the major CHDs in the study population were detected prior to the routine scan.



An abnormal karyotype was found in 38% of the 97 major CHDs, and 18% had associated malformations with normal karyotype (Paper III). Major CHDs with associated malformations including abnormal karyotype were significantly more often detected than were isolated major CHDs. Of the isolated ductal dependent major CHDs, 48% were detected prenatally. Of the isolated major CHDs missed prenatally, 58% would be expected to have an abnormal four-chamber view.

The incidence of major CHDs was constant between 3.0–3.7/1000 through the complete study period. The incidence of minor CHDs increased from 7.4–11.3/1000 through the same period (Papers II and III).

There were significant differences in the outcomes between the fetuses with a CHD detected prenatally compared to postnatally (Paper III). Of the prenatally detected cases, 44% of the pregnancies were terminated. Of those, 58% had associated lethal chromosome aberrations, and the rest, except for the trisomy 21 cases, were severe anomalies. Intrauterine fetal death occurred in 15% of the fetuses with a detected CHD, but in none of those not detected prenatally. Of the prenatally detected cases, 42% were born alive. At the age of 2 years, only 27% of the children with prenatally detected CHDs were alive. The corresponding numbers for those detected postnatally were 98% and 81%, respectively.

Compared to the less experienced sonographer/midwives, the experienced sonographer/midwives showed significantly better results in obtaining a view of the great arteries and in recognizing an abnormal four-chamber view (Paper IV). The experienced sonographer/midwives did better in the overall detection of major CHDs, as well as in the detection of isolated CHDs and CHDs with associated malformations. The less experienced sonographer/midwives showed a significant improvement over time in their ability to obtain the heart structures and reach the level of the experienced sonographer/midwives. CHDs with an abnormal four-chamber view were missed in both groups.

With the new 3D technique utilizing tissue Doppler as a gating signal, it was possible to obtain images of adequate quality in four out of eight fetuses and reconstructed volume projections of the heart from one cine loop of 3D data could be demonstrated (Paper V). Two fetuses showed several motion artifacts; in two fetuses, a four-chamber view could not be obtained due to awkward fetal position.

## Conclusions

The fetal heart examination, and thus the prenatal detection of CHDs, is still a challenge in non-selected populations. Incorporation of the four-chamber view and the great arteries increases the detection rate to some extent, but not as much as expected. The fetuses with the most severe CHDs and associated malformations seem easier to detect than fetuses with isolated CHDs.

Education and training seem crucial for the ability to obtain fetal heart structures. Obtaining and interpreting basic views of the fetal heart failed for all sonographer/midwives, emphasizing that the basic education on the fetal heart examination needs to be strengthened. Both the views of the four chambers and the great arteries must be mastered before new views and advanced technology are added.

## Future aspects

Recent data show that results for newborns with a heart defect detected prenatally are improving. To detect the major CHDs, the sonographer/midwife must master the 2D ultrasound technique as well as the evaluation of the four-chamber view and the great arteries. Thus, the fetal heart examination must be given special attention in the education and training of sonographer/midwives. With a thorough basic understanding and experience, advanced ultrasound techniques may be more easily adopted.

Recent studies also indicate that the 11–13+6 week scan might be of importance for the overall detection of heart defects during pregnancy.

## REFERENCES

- Abuhamad, A.Z., Benacerraf, B.R., Woletz, P., Burke, B.L. 2004 The accreditation of ultrasound practices: Impact on compliance with minimum performance guidelines. *J Ultrasound Med* **23**: 1023–1029.
- Abuhamad, A.Z. 2005 Standardization of 3-dimensional volumes in obstetric sonography. A required step for training and automation. *J Ultrasound Med* **24**: 397–401.
- Abu-Harb, M., Hey, E., Wren, C. 1994 Death in infancy from unrecognised congenital heart disease. *Arch Dis Child* **71**: 3–7.
- Achiron, R., Glaser, J., Gelernter, I., Hegesh, J., Yagel, S. 1992 Extended fetal echocardiographic examination for detecting cardiac malformations in low risk pregnancies. *Br Med J* **304**: 671–674.
- Achiron, R., Weissman, A., Rotstein, Z., Lipitz, S., Mashiach, S., Hegesh, J. 1994 Transvaginal echocardiographic examination of the fetal heart between 13 and 15 weeks' gestation in a low-risk population. *J Ultrasound Med* **13**: 783–789.
- Allan, L.D., Tynan, M.J., Campbell, S., Wilkinson, J., Anderson, R.H. 1980 Echocardiographic and anatomical correlates in the fetus. *Br Heart J* **44**: 444–451.
- Allan, L.D. 1986 Manual of fetal echocardiography. MPT Press Limited: Lancaster, England, pp. 11–47.
- Allan, L.D., Crawford, D.C., Chita, S.K., Anderson, R.H., Tynan, M.J. 1986a Familial recurrence of congenital heart disease in a prospective series of mothers referred for fetal echocardiography. *Am J Cardiol* **58**: 334–337.
- Allan, L.D., Crawford, D.C., Sunder, K.C., Tynan, M.J. 1986b Prenatal screening for congenital heart disease. *Br Med J* **292**: 1717–1719.
- Allan, L.D. 1989 Diagnosis of fetal cardiac abnormalities. *Arch Dis Child* **64**: 964–968.
- Allan, L.D., Chita, S.K., Sharland, G.K., Fagg, N.L.K., Anderson, R.H., Crawford, D.C. 1989 The accuracy of fetal echocardiography in the diagnosis of congenital heart disease. *Int J Cardiol* **25**: 279–288.
- Allan, L.D., Cook, A., Sullivan, I., Sharland G.K. 1991 Hypoplastic left heart syndrome: effects of fetal echocardiography on birth prevalence. *Lancet* **337**: 959–961.
- Allan, L.D., Sharland, G.K., Milburn, A., Lockhart, S.M., Groves, A.M.M., Anderson, R.H., Cook, A.C., Fagg, N.L.K. 1994 Prospective diagnosis of 1,006 consecutive cases of congenital heart disease in the fetus. *J Am Coll Cardiol* **23**: 1452–1458.
- Allan, L.D., Santos, R., Pexieder, T. 1997 Anatomical and echocardiographic correlates of normal cardiac morphology in the late first trimester fetus. *Heart* **77**: 68–72.

- Allan, L., Benacerraf, B., Copel, J.A., Carvalho, J.S., Chaoui, R., Eik-Nes, S.H., Tegnander, E., Gembruch, U., Huhta, J.C., Pilu, G., Wladimiroff, J., Yagel, S. 2001 Isolated major congenital heart disease. *Ultrasound Obstet Gynecol* **17**: 370–379.
- Allan, L.D. 2003 Cardiac anatomy screening: what is the best time for screening in pregnancy? *Curr Opin Obstet Gynecol* **15**: 143–146.
- Allan, L.D. 2004 Technique of fetal echocardiography. *Pediatr Cardiol* **25**: 223–233.
- Allan, L.D., Huggon, I.C. 2004 Counselling following a diagnosis of congenital heart disease. *Prenat Diagn* **24**: 1136–1142.
- Allan, L., Dangel, J., Fesslova, V., Marek, J., Mellander, M., Oberhänsli, I., Oberhoffer, R., Sharland, G., Simpson, J., Sonesson, S.-E. 2004 Recommendations for the practice of fetal cardiology in Europe. *Cardiol Young* **14**: 109–114.
- American Heart Association: 1994 Revisions to classification of functional capacity and objective assessment of patients with disease of the heart.  
<http://www.americanheart.org/presenter.jhtml?identifier=1712> [Accessed 11 February 2005].
- Änderung der Mutterschafts-Richtlinien. *Deutsches Ärzteblatt*, **92**, Heft 5, 3. Februar 1995, [Changes in guidelines for maternity care], pp. B-233–B-235.
- Andrews, R., Tulloh, R., Sharland, G., Simpson, J., Rollings, S., Baker, E., Qureshi, S., Rosenthal, E., Austin, C., Anderson, D. 2001 Outcome of staged reconstructive surgery for hypoplastic left heart syndrome following antenatal diagnosis. *Arch Dis Child* **85**: 474–477.
- Angelsen, B.A.J., Kristoffersen, K., Torp, H.G., Linker, D.T., Skjærpe, T. 1989 Color flow mapping with an annular array. In: Nanda, N.C. Textbook of color Doppler echocardiography, Lea & Febiger: Philadelphia, pp. 56–63.
- Angtuaco, T.L., Shah, H.R., Mattison, D.R., Quirk Jr, J.G. 1992 MR imaging in high-risk obstetric patients: A valuable complement to US. *RadioGraphics* **12**: 91–109.
- Backe, B., Buhaug, H. 1986 Bruk av ultralyd i svangerskapet. Konsensuskonferansen (Use of ultrasound in pregnancy. The consensus statement). NIS-rapport 8/86, pp. 119–134. (Trondheim: Norwegian Institute for Hospital Research).
- Backe, B. 1994 Routine use of ultrasound in obstetrics in Norway, 1994. *Tidsskr Nor Lægeforen* **117**: 2314–2315.
- Baker, J.P. 2005 The history of sonographers. *J Ultrasound Med* **24**: 1–14.
- Bakketeig, L.S., Eik-Nes, S.H., Jacobsen, G., Ulstein, M.K., Brodtkorb, C.J., Balstad, P., Eriksen, B.C., Jörgensen, N.P. 1984 Randomised controlled trial of ultrasonographic screening in pregnancy. *Lancet* **2**: 207–211.
- Bennett, J.A., Riegel, B., Bittner, V., Nichols, J. 2002 Validity and reliability of the NYHA classes for measuring research outcomes in patients with cardiac disease. *Heart Lung* **31**: 262–270.

- Bennett, M.J., Little, G., Dewhurst, Sir J., Chamberlain, G. 1982 Predictive value of ultrasound measurement in early pregnancy: a randomized controlled trial. *Br J Obstet Gynaecol* **89**: 338–341.
- Ben-Shachar, G., Arcilla, R.A., Lucas, R.V., Manasek, F.J. 1985 Ventricular trabeculations in the chick embryo heart and their contribution to ventricular and muscular septal development. *Circ Res* **57**: 759–766.
- Berg, K.A., Clark, E.B., Astemborski, J.A., Boughman, J.A. 1988 Prenatal detection of cardiovascular malformations by echocardiography: An indication for cytogenetic evaluation. *Am J Obstet Gynecol* **159**: 477–481.
- Blaas, H.-G.K. 1999 The examination of the embryo and the early fetus: how and by whom? *Ultrasound Obstet Gynecol* **14**: 153–158.
- Blaicher, W., Prayer, D., Mittermayer, C., Weninger, M., Birnbacher, R., Deutinger, J., Bernaschek, G. 2005 The clinical impact of magnetic resonance imaging in fetuses with central nervous system anomalies on ultrasound scan. *Ultraschall Med* **26**: 29–35.
- Boldt, T., Andersson, S., Eronen, M. 2002 Outcome of structural heart disease *in utero*. *Scand Cardiovasc J* **36**: 73–79.
- Bonnet, D., Coltri, A., Butera, G., Fermont, L., Le Bidois, J., Kachaner, J., Sidi, D. 1999 Detection of transposition of the great arteries in fetuses reduces neonatal morbidity and mortality. *Circulation* **99**: 916–918.
- Brantberg, A., Blaas, H.-G.K., Salvesen, K.Å., Haugen, S.E., Eik-Nes, S.H. 2004 Surveillance and outcome of fetuses with gastroschisis. *Ultrasound Obstet Gynecol* **23**: 4–13.
- Brick, D.H., Allan, L.D. 2002 Outcome of prenatally diagnosed congenital heart disease: An update. *Pediatr Cardiol* **23**: 449–453.
- Brinkley, J.F., Moritz, W.E., Baker, D.W. 1978 Ultrasonic three-dimensional imaging and volume from a series of arbitrary sector scans. *Ultrasound Med Biol* **4**: 317–327.
- Brinkley, J.F., McCallum, W.D., Muramatsu, S.K., Liu, D.Y. 1982 Fetal weight estimation from ultrasonic three-dimensional head and trunk reconstructions: evaluation in vitro. *Am J Obstet Gynecol* **144**: 715–721.
- Brocks, V., Bang, J. 1991 Routine examination by ultrasound for the detection of fetal malformations in a low risk population. *Fetal Diagn Ther* **6**: 37–45.
- Brodin, L.-Å. 2004 Tissue Doppler, a fundamental tool for parametric imaging. *Clin Physiol Funct Imaging* **24**: 147–155.
- Bromley, B., Estroff, J.A., Sanders, S.P., Parad, R., Roberts, D., Frigoletto Jr., F.D., Benacerraf, B.R. 1992 Fetal echocardiography: Accuracy and limitations in a population at high and low risk for heart defects. *Am J Obstet Gynecol* **166**: 1473–1481.
- Brubakk, A.O., Angelsen, B.A.J., Hatle, F. 1977 Diagnosis of valvular heart disease using transcutaneous Doppler ultrasound. *Cardiovasc Res* **11**: 461–469.

- Budorick, N.E., Millman, S.L. 2000 New modalities for imaging the fetal heart. *Semin Perinatol* **24**: 352–359.
- Bull, C. 1999 Current and potential impact of fetal diagnosis on prevalence and spectrum of serious congenital heart disease at term in the UK. *Lancet* **354**: 1242–1247.
- Burr, R., Johanson, R. 1998 Continuing medical education: an opportunity for bringing about change in clinical practice. *Br J Obstet Gynaecol* **105**: 940–945.
- Buskens, E., Grobbee, D.E., Frohn-Mulder I.M.E., Stewart, P.A., Juttman, R.E., Wladimiroff, J.W., Hess, J. 1996 Efficacy of routine fetal ultrasound screening for congenital heart disease in normal pregnancies. *Circulation* **94**: 67–72.
- Callan, N.A., Maggio, M., Steger, S., Kan, J.S. 1991 Fetal echocardiography: Indications for referral, prenatal diagnoses, and outcomes. *Am J Perinatol* **8**: 390–394.
- Campbell, S. 1968 An improved method of fetal cephalometry by ultrasound. *J Obstet Gynaecol Br Commonw* **75**: 568–576.
- Campbell, S., Johnstone, F.D., Holt, E.M., May, P. 1972 Anencephaly: Early ultrasonic diagnosis and active management. *Lancet* **2**: 1226–1227.
- Campbell, S. 1977 Early prenatal diagnosis of neural tube defects by ultrasound. *Clin Obstet Gynecol* **20**: 351–359.
- Carlgren, L.-E. 1969 The incidence of congenital heart disease in Gothenburg. *Proc Ass Europ Paediat Cardiol* **V**: 2–8.
- Carlgren, L.E., Ericson, A., Källén, B. 1987 Monitoring of congenital cardiac defects. *Pediatr Cardiol* **8**: 247–256.
- Carvalho, J.S., Mavrides, E., Shinebourne, E.A., Campbell, S., Thilaganathan, B. 2002 Improving the effectiveness of routine prenatal screening for major congenital heart defects. *Heart* **88**: 387–391.
- Chaoui, R. 2001 Fetal echocardiography: state of the art of the state of the heart. *Ultrasound Obstet Gynecol* **17**: 277–284.
- Chaoui, R. 2003a The examination of the normal fetal heart using two-dimensional echocardiography. In: Fetal cardiology. Yagel, S., Silverman, N.H., Gembruch, U. (Eds.) Martin Dunitz, Taylor & Francis Group, United Kingdom, pp. 141–149.
- Chaoui, R. 2003b The four-chamber view: four reasons why it seems to fail in screening for cardiac abnormalities and suggestions to improve detection rate. *Ultrasound Obstet Gynecol* **22**: 3–10.
- Chaoui, R., McEwing, R. 2003 Three cross-sectional planes for fetal color Doppler echocardiography. *Ultrasound Obstet Gynecol* **21**: 81–93.
- Chaoui, R., Hoffmann, J., Heling, K.S. 2004 Three-dimensional (3D) and 4D color Doppler fetal echocardiography using spatio-temporal image correlation (STIC). *Ultrasound Obstet Gynecol* **23**: 535–545.

- Chinn, A., Fitzsimmons, J., Shepard, H., Fantel, A.G. 1989 Congenital heart disease among spontaneous abortuses and stillborn fetuses: Prevalence and associations. *Teratology* **40**: 475–482.
- Chitty, L.S., Hunt, G.H., Moore, J., Lobb, M.O. 1991 Effectiveness of routine ultrasonography in detecting fetal structural abnormalities in a low risk population. *BMJ* **303**: 1165–1169.
- Chung, T. 2000 Assessment of cardiovascular anatomy in patients with congenital heart disease by magnetic resonance imaging. *Pediatr Cardiol* **21**: 18–26.
- Copel, J.A., Pilu, G., Green, J., Hobbins, J.C., Kleinman, C.S. 1987 Fetal echocardiographic screening for congenital heart disease: the importance of the four-chamber view. *Am J Obstet Gynecol* **157**: 648–655.
- Copel, J.A., Cullen, M., Green, J.J., Mahoney, M.J., Hobbins, J.C., Kleinman, C.S. 1988 The frequency of aneuploidy in prenatally diagnosed congenital heart disease: An indication for fetal karyotyping. *Am J Obstet Gynecol* **158**: 409–413.
- Copel, J.A., Tan, A.S.A., Kleinman, C.S. 1997 Does a prenatal diagnosis of congenital heart disease alter short-term outcome? *Ultrasound Obstet Gynecol* **10**: 237–241.
- Crane, J.P., LeFevre, M.J., Winborn, R.C., Evans, J.K., Ewigman, B.G., Bain, R.P., Frigoletto, F.D., McNellis, D., the RADIUS Study Group. 1994 A randomized trial of prenatal ultrasonographic screening: Impact on the detection, management, and outcome of anomalous fetuses. *Am J Obstet Gynecol* **171**: 392–399.
- Cullen, S., Sharland, G.K., Allan, L.D., Sullivan, I.D. 1992 Potential impact of population screening for prenatal diagnosis of congenital heart disease. *Arch Dis Child* **67**: 775–778.
- Cuneo, B.F., Curran, L.F., Davis, N., Elrad, H. 2004 Trends in prenatal diagnosis of critical cardiac defects in an integrated obstetric and pediatric cardiac imaging center. *J Perinatol* **24**: 674–678.
- Curie, J., Curie, P. 1880 Développement, par pression, de l'électricité polaire dans les cristaux hémihédres à faces inclinées. *Comp Rend* **91**: 294–295.
- Davis, G.K., Farquhar, C.M., Allan, L.D., Crawford, D.C., Chapman, M.G. 1990 Structural cardiac abnormalities in the fetus: reliability of prenatal diagnosis and outcome. *Br J Obstet Gynaecol* **97**: 27–31.
- Deng, J., Gardener, J.E., Rodeck, C.H., Lees, W.R. 1996 Fetal echocardiography in three and four dimensions. *Ultrasound in Med & Biol* **8**: 979–986.
- Deng, J., Ruff, C.F., Linney, A.D., Lees, W.R., Hanson, M.A., Rodeck, C.H. 2000 Simultaneous use of two ultrasound scanners for motion-gated three-dimensional fetal echocardiography. *Ultrasound in Med & Biol* **26**: 1021–1032.
- Deng, J., Sullivan, I.D., Yates, R., Vogel, M., McDonald, D., Linney, A.D., Rodeck, C.H., Anderson, R.H. 2002a Real-time three-dimensional fetal echocardiography – optimal imaging windows. *Ultrasound in Med & Biol* **28**: 1099–1105.

- Deng, J., Yates, R., Sullivan, I.D., McDonald, D., Linney, A.D., Lees, W.R., Anderson, R.H., Rodeck, C.H. 2002b Dynamic three-dimensional color Doppler ultrasound of human fetal intracardiac flow. *Ultrasound Obstet Gynecol* **20**: 131–136.
- Deng, J. 2003 Terminology of three-dimensional and four-dimensional ultrasound imaging of the fetal heart and other moving body parts. *Ultrasound Obstet Gynecol* **22**: 336–344.
- Devine, P.C., Malone, F.D. 1999 First trimester screening for structural fetal abnormalities: Nuchal translucency sonography. *Sem Perinatol* **23**: 382–392.
- DeVore, G.R. 1985 The prenatal diagnosis of congenital heart disease—A practical approach for the fetal sonographer. *J Clin Ultrasound* **13**: 229–245.
- DeVore, G.R., Medearis, A.L., Bear, M.B., Horenstein, J., Platt, L.D. 1993 Fetal echocardiography: Factors that influence imaging of the fetal heart during the second trimester of pregnancy. *J Ultrasound Med* **12**: 659–663.
- DeVore, G.R., Falkensammer, P., Sklansky, M.S., Platt, L.D. 2003 Spatio-temporal image correlation (STIC): new technology for evaluation of the fetal heart. *Ultrasound Obstet Gynecol* **22**: 380–387.
- Dickinson, D.F., Arnold, R., Wilkinson, J.L. 1981 Congenital heart disease among 160 480 liveborn children in Liverpool 1960 to 1969: Implications for surgical treatment. *Br Heart J* **46**: 55–62.
- Dolk, H. 2005 EUROCAT: 25 years of European surveillance of congenital anomalies. *Arch Dis Child Fetal Neonatal Ed* **90**: F355–F358.
- Donald, I., MacVicar, J., Brown, T.G. 1958 Investigation of abdominal masses by pulsed ultrasound. *Lancet* **1**: 1188–1195.
- Donald, I., Brown, T.G. 1961 Demonstration of tissue interfaces within the body by ultrasonic echo sounding. *Br J Radiol* **34**: 539–546.
- Donald, I. 1962 Clinical application of ultrasound techniques in obstetrical and gynaecological diagnosis. *J Obstet Gynaecol Br Emp* **69**: 1036–1039.
- Downey, D.B., Fenster, A., Williams, M.A. 2000 Clinical utility of three-dimensional US. *RadioGraphics* **20**: 559–571.
- Du, Z.-D., Roguin, N., Wu, X.-J. 1998 Spontaneous closure of muscular ventricular septal defect identified by echocardiography in neonates. *Cardiol Young* **8**: 500–505.
- Eapen, R.S., Rowland, D.G., Franklin, W.H. 1998 Effect of prenatal diagnosis of critical left heart obstruction on perinatal morbidity and mortality. *Am J Perinatol* **15**: 237–242.
- Edler, E. 1961 Ultrasonocardiography. *Acta Med Scand Suppl* **170**: 1–124.
- Edler, I., Hertz, C.H. 1954 The use of ultrasonic reflectoscope for the continuous recording of the movements of heart walls. *Kungl Fysiogr Sällsk Lund Förhandl* **24**: 40–58.



- Eik-Nes, S.H., Brubakk, A.O., Ulstein, M.K. 1980 Measurement of human fetal blood flow. *Br Med J* **280**: 283–284.
- Eik-Nes, S.H., Maršál, K., Brubakk, A.O., Kristofferson, K., Ulstein, M. 1982 Ultrasonic measurement of human fetal blood flow. *J Biomed Eng* **4**: 28–36.
- Eik-Nes, S.H., Brinkley, J. 1983 Tredimensjonal framstilling av foster *in utero* ved hjelp av ultralyd og moderne datateknologi. Abstract. (Three-dimensional imaging of the fetus *In Utero* using ultrasound and modern computer technology. Abstract). *Norwegian Society for Diagnostic Ultrasound in Medicine*. Annual meeting, Røros, p. 40
- Eik-Nes, S.H., Økland, O., Aure, J.C., Ulstein, M. 1984a Ultrasound screening in pregnancy: a randomized controlled trial. *Lancet* **1**: 1347.
- Eik-Nes, S.H., Maršál, K., Kristoffersen, K. 1984b Methodology and basic problems related to blood flow studies in the human fetus. *Ultrasound Med Biol* **10**: 329–337.
- Eik-Nes, S.H. 1986 Ultralyd diagnostikk i svangerskapet. Muligheter, resultater, organisering. In: Backe, B., Buhaug, H. (eds.) *Bruk av ultralyd i svangerskapet. Konsensuskonferansen (Use of ultrasound in pregnancy. The consensus statement)*. NIS-rapport 8/86. (Trondheim: Norwegian Institute for Hospital Research), pp. 38–41.
- Eik-Nes, S.H. 1993a An overview of routine versus selective use of ultrasound. In: *Ultrasound in Obstetrics and Gynecology. Volume I*. Chervenak, F.A., Isaacson, G.C., Campbell, S. (eds.) Little, Brown and company, Boston, pp. 229–238.
- Eik-Nes, S.H. 1993b The fetal examination. *Ultrasound Obstet Gynecol* **3**: 83–85.
- Eik-Nes, S.H., Salvesen, K.Å., Økland, O., Vatten, L.J. 2000 Routine ultrasound fetal examination in pregnancy: the “Ålesund” randomized controlled trial. *Ultrasound Obstet Gynecol* **15**: 473–478.
- Evans, J.R., Rowe, R.D., Keith, J.D. 1960 Spontaneous closure of ventricular septal defects. *Circulation* **22**: 1044–1054.
- Ewigman, B.G., Crane, J.P., Frigoletto, F.D., LeFevre, M.L., Bain, R.P., McNellis, D., and the RADIUS study group. 1993 Effect of prenatal ultrasound screening on perinatal outcome. *N Engl J Med* **329**: 821–827.
- Ferencz, C., Rubin, J.D., McCarter, R.J., Brenner, J.I., Neill, C.A., Perry, L.W., Hepner, S.I., Downing, J.W. 1985 Congenital heart disease: Prevalence at livebirth. The Baltimore-Washington infant study. *Am J Epidemiol* **121**: 31–36.
- Ferencz, C., Neill, C.A., Boughman, J.A., Rubin, J.D., Brenner, J.I., Perry, L.W. 1989 Congenital cardiovascular malformations associated with chromosome abnormalities: An epidemiologic study. *J Pediatr* **114**: 79–86.
- Ferencz, C., Czeizel, A., Lys, F. 1990 The problem of comparative analysis of birth prevalence of congenital cardiovascular malformations. *Acta Paediat Hung* **30**: 169–189.
- Fermont, L., de Geeter, B., Aubry, B., Kachaner, J., Sidi, D. 1985 A close collaboration between obstetricians and pediatric cardiologists allows antenatal detection of

- severe cardiac malformations by 2D echocardiography. Presented at the 2<sup>nd</sup> World congress of Paediatric Cardiology New York, p. 10.
- Fernandez, C.O., Ramaciotti, C., Martin, L.B., Twickler, D.M. 1998 The four-chamber view and its sensitivity in detecting congenital heart defects. *Cardiology* **90**: 202–206.
- FitzGerald, D.E., Drumm, J.E. 1977 Non-invasive measurement of human fetal circulation using ultrasound: a new method. *Br Med J* **2**: 1450–1451.
- Fogel, M.A., Wilson, R.D., Flake, A., Johnson, M., Cohen, D., McNeal, G., Tian, Z.Y., Rychik, J. 2005 Preliminary investigations into a new method of functional assessment of the fetal heart using a novel application of 'real-time' cardiac magnetic resonance imaging. *Fetal Diagn Ther* **20**: 475–480.
- Franklin, O., Burch, M., Manning, N., Sleeman, K., Gould, S., Archer, N. 2002 Prenatal diagnosis of coarctation of the aorta improves survival and reduces morbidity. *Heart* **87**: 67–69.
- Gardiner, H.M. 2001 Fetal echocardiography: 20 years of progress. *Heart* **86** (Suppl II): ii12–ii22.
- Garne, E., Stoll, C., Clementi, M., the Euroscan Group. 2001 Evaluation of prenatal diagnosis of congenital heart diseases by ultrasound: experience from 20 European registries. *Ultrasound Obstet Gynecol* **17**: 386–391.
- Garne, E., Loane, M., Dolk, H., De Vigan, C., Scarano, G., Tucker, D., Stoll, C., Gener, B., Pierini, A., Nelen, V., Rösch, C., Gillerot, Y., Feijoo, M., Tincheva, R., Queisser-Luft, A., Addor, A.-C., Mosquera, C., Gatt, M., Barisic, I. 2005 Prenatal diagnosis of severe structural congenital malformations in Europe. *Ultrasound Obstet Gynecol* **25**: 6–11.
- Geirsson, R.T. 1987 Leidbeininar um omskodun a medgongu. *Laeknabladid* **3**: 12–15.
- Gembruch, U., Knöpfle, G., Chatterjee, M., Bald, R., Hansmann, M. 1990 First-trimester diagnosis of fetal congenital heart disease by transvaginal two-dimensional and Doppler echocardiography. *Obstet Gynecol* **75**: 496–498.
- Gembruch, U., Knöpfle, G., Bald, R., Hansmann, M. 1993 Early diagnosis of fetal congenital heart disease by transvaginal echocardiography. *Ultrasound Obstet Gynecol* **3**: 310–317.
- Gembruch, U., Geipel, A. 2003 Indication for echocardiography: screening in low- and high-risk populations. In: *Fetal Echocardiography*. Yagel, S., Silverman, N.H., Gembruch, U. (eds.) Martin Dunitz, London, pp. 89–106.
- Gerlis, L.M. 1985 Cardiac malformations in spontaneous abortions. *Int J Cardiol* **7**: 29–43.
- Gill, R.W., Kossoff, G. 1979 Pulsed Doppler combined with B-mode imaging for blood flow measurement. *Contr Gynec Obstet* **6**: 139–141.
- Gonçalves, L.F., Romero, R. 1993 A critical appraisal of the RADIUS study. *The Fetus* **3**: 7–18.

- Gonçalves, L.F., Romero, R., Espinoza, J., Lee, W., Treadwell, M., Chintala, K., Brandl, H., Chaiworapongsa, T. 2004 Four-dimensional ultrasonography of the fetal heart using color Doppler spatiotemporal image correlation. *J Ultrasound Med* **23**: 473–481.
- Grandjean, H., Larroque, G., Levi, S., and the Eurofetus Study Group. 1999 The performance of routine ultrasonographic screening of pregnancies in the Eurofetus Study. *Am J Obstet Gynecol* **181**: 446–454.
- Grennert, L., Persson, P.-H., Gennser, G. 1978 Benefits of ultrasonic screening of a pregnant population. *Acta Obstet Gynecol Scand Suppl* **78**: 5–14.
- Haak, M.C., Twisk, J.W.R., Van Vugt, J.M.G. 2002 How successful is fetal echocardiographic examination in the first trimester of pregnancy? *Ultrasound Obstet Gynecol* **20**: 9–13.
- Hafner, E., Schuchter, K., Liebhart, E., Philipp, K. 1998a Results of routine fetal nuchal translucency measurement at weeks 10–13 in 4233 unselected pregnant women. *Prenat Diagn* **18**: 29–34.
- Hafner, E., Scholler, J., Schuchter, K., Sterniste, W., Philipp, K. 1998b Detection of fetal congenital heart disease in a low-risk population. *Prenat Diagn* **18**: 808–815.
- Hata, T., Aoki, S., Hata, K., Miyazaki, K., Akahane, M., Mochizuki, T. 1998 Three-dimensional ultrasonographic assessments of fetal development. *Obstet Gynecol* **91**: 218–223.
- Hatle, L., Brubakk, A., Tromsdal, A., Angelsen, B. 1978 Noninvasive assessment of pressure drop in mitral stenosis by Doppler ultrasound. *Br Heart J* **40**: 131–140.
- Hatle, L., Angelsen, B.A., Tromsdal, A. 1980 Non-invasive assessment of aortic stenosis by Doppler ultrasound. *Br Heart J* **43**: 284–292.
- Hatle, L., Angelsen, B.A.J., Tromsdal, A. 1981 Non-invasive estimation of pulmonary artery systolic pressure with Doppler ultrasound. *Br Heart J* **45**: 157–165.
- Hatle, L., Angelsen, B. 1982 Doppler ultrasound in cardiology. Lea & Febiger, Philadelphia, p. 5.
- Helgason, H., Jonsdottir, G. 1999 Spontaneous closure of atrial septal defects. *Pediatr Cardiol* **20**: 195–199.
- Hendler, I., Blackwell, S.C., Bujold, E., Treadwell, M.C., Mittal, P., Sokol, R.J., Sorokin, Y. 2005 Suboptimal second-trimester ultrasonographic visualization of the fetal heart in obese women. Should we repeat the examination? *J Ultrasound Med* **24**: 1205–1209.
- Herberg, U., Goldberg, H., Breuer, J. 2003 Dynamic free-hand three-dimensional fetal echocardiography gated by cardiotocography. *Ultrasound Obstet Gynecol* **22**: 493–502.
- Herberg, U., Goldberg, H., Breuer, J. 2005 Three- and four-dimensional freehand fetal echocardiography: a feasibility study using a hand-held Doppler probe for cardiac gating. *Ultrasound Obstet Gynecol* **25**: 362–371.

- Hiraishi, S., Agata, Y., Nowatari, M., Oguchi, K., Misawa, H., Hirota, H., Fujino, N., Horiguchi, Y., Yashiro, K., Nakae, S. 1992 Incidence and natural course of trabecular ventricular septal defect: Two-dimensional echocardiography and color Doppler flow imaging study. *J Pediatr* **120**: 409–415.
- Hoffman, J.I.E., Christianson, R. 1978 Congenital heart disease in a cohort of 19,502 births with long-term follow-up. *Am J Cardiol* **42**: 641–647.
- Hoffman, J.I.E. 1995a Incidence of congenital heart disease: I. Postnatal incidence. *Pediatr Cardiol* **16**: 103–113.
- Hoffman, J.I.E. 1995b Incidence of congenital heart disease: II. Prenatal incidence. *Pediatr Cardiol* **16**: 155–165.
- Hofstaetter, C., Gudmundsson, S., Hansmann, M. 2002 Venous Doppler velocimetry in the surveillance of severely compromised fetuses. *Ultrasound Obstet Gynecol* **20**: 233–239.
- Holt, J., Vold, I.N., Odland, J.Ø., Førde, O.H. 2000 Perinatal deaths in a Norwegian county 1986–96 classified by the Nordic-Baltic perinatal classification: Geographical contrasts as a basis for quality assessment. *Acta Obstet Gynecol Scand* **79**: 107–112.
- Huhta, J.C. 1986 Uses and abuses of fetal echocardiography: A pediatric cardiologist's view. *J Am Coll Cardiol* **8**: 451–458.
- Huhta, J.C., Rotondo, K.M. 1991 Fetal echocardiography. *Semin Roentgenol* **26**: 5–11.
- Hull, A.D., Pretorius, D.H., Lev-Toaff, A., Budorick, N.E., Salerno, C.C., Johnson, M.M., James, G., Nelson, T.R. 2000 Artifacts and the visualization of fetal distal extremities using three-dimensional ultrasound. *Ultrasound Obstet Gynecol* **16**: 341–344.
- Hunter, S., Heads, A., Wyllie, J., Robson, S. 2000 Prenatal diagnosis of congenital heart disease in the northern region of England: benefits of a training programme for obstetric ultrasonographers. *Heart* **84**: 294–298.
- Hyett, J.A., Perdu, M., Sharland, G.K., Snijders, R.S.M., Nicolaides, K.H. 1997 Increased nuchal translucency at 10–14 weeks of gestation as a marker for major cardiac defects. *Ultrasound Obstet Gynecol* **10**: 242–246.
- Hyett, J.A. 2002 Increased nuchal translucency in fetuses with a normal karyotype. *Prenat Diagn* **22**: 864–868.
- Isaaz, K., Thompson, A., Ethevenot, G., Cloez, J.L., Brembilla, B., Pernot, C. 1989 Doppler echocardiographic measurement of low velocity motion of the left ventricular posterior wall. *Am J Cardiol* **64**: 66–75.
- Isaksen, C.V., Eik-Nes, S.H., Blaas, H.-G., Tegnander, E., Torp, S.H. 1999 Comparison of prenatal ultrasound and postmortem findings in fetuses and infants with congenital heart defects. *Ultrasound Obstet Gynecol* **13**: 117–126.
- ISUOG educational committee 1996 Update on proposed minimum standards for ultrasound training for residents in OB/Gyn. *Ultrasound Obstet Gynecol* **8**: 363–365.

- ISUOG guidelines 2006 Cardiac screening examination of the fetus: guidelines for performing the 'basic' and 'extended basic' cardiac scan. *Ultrasound Obstet Gynecol* **27**: 107–113.
- Jacobs, M.L., Norwood Jr., W.I. 1994 Fontan operation: Influence of modifications on morbidity and mortality. *Ann Thorac Surg* **58**: 945–952.
- Jaeggi, E.T., Sholler, G.F., Jones, O.D.H., Cooper, S.G. 2001 Comparative analysis of pattern, management and outcome of pre- versus postnatally diagnosed major congenital heart disease: a population-based study. *Ultrasound Obstet Gynecol* **17**: 380–385.
- Jouppila, P. 1971 Ultrasound in the diagnosis of early pregnancy and its complications. A comparative study of the A-, B- and Doppler methods. Thesis. *Acta Obstet Gynecol Scand Suppl* **50**: 3–56.
- Kirk, J.S., Comstock, C.H., Lee, W., Smith, R.S., Riggs, T.W., Weinhouse, E. 1997 Sonographic screening to detect fetal cardiac abnormalities: A 5-year experience with 111 abnormal cases. *Obstet Gynecol* **89**: 227–232.
- Kirkinen, P., Jouppila, P., Eik-Nes, S.H. 1983 Umbilical vein blood flow in rhesus-isoimmunization. *Br J Obstet Gynaecol* **90**: 640–643.
- Kleinman, C.S., Hobbins, J.C., Jaffe, C.C., Lynch, D.C., Talner, N.S. 1980 Echocardiographic studies of the human fetus: prenatal diagnosis of congenital heart disease and cardiac dysrhythmias. *Pediatrics* **65**: 1059–1067.
- Knox, E.M., Muamar, B., Thompson, P.J., Lander, A., Chapman, S., Kilby, M.D. 2005 The use of high resolution magnetic resonance imaging in the prenatal diagnosis of fetal nuchal tumors. *Ultrasound Obstet Gynecol* **26**: 672–675
- Kratochwil, A., Eisenhut, L. 1967 [The earliest detection of fetal heart activity by ultrasound] [German] *Geburtshilfe Frauenheilkd* **27**: 176–180.
- Kratochwil, A. 1968 *Ultraschalldiagnostik in Geburtshilfe und Gynäkologie*. Georg Thieme Verlag, Stuttgart, pp. 1–116.
- Kremkau, F.W. 2006 *Diagnostic ultrasound: Principles and instruments*. Seventh edition, Saunders Elsevier, Missouri, pp. 3–53, 66, 185–216.
- Lange, L.W., Sahn, D.J., Allen, H.D., Goldberg, S.J., Anderson, C., Giles, H. 1980 Qualitative real-time cross-sectional echocardiographic imaging of the human fetus during the second half of pregnancy. *Circulation* **62**: 799–806.
- Larssen, K.-E., Bakketeig, L.S., Bergsjø, P., Finne, P.H., Laurini, R., Knoff, H., Holt, J., Vogt, H., Hapnes, C. 1982 Perinatal audit in Norway 1980. NIS-rapport 7/82, Norwegian Institute of Hospital Research, Trondheim, pp. 7–150.
- Levi, S., Zhang, W.H., Alexander, S., Viart, P., Grandjean, H., the Eurofetus Study Group. 2003 Short-term outcome of isolated and associated congenital heart defects in relation to antenatal ultrasound screening. *Ultrasound Obstet Gynecol* **21**: 532–538.
- Levine, D., Hatabu, H., Gaa, J., Atkinson, M.W., Edelman, R.R. 1996 Fetal anatomy revealed with fast MR sequences. *AJR Am J Roentgenol* **167**: 905–908.

- Levine, D., Barnes, P.D., Edelman, R.R. 1999a Obstetric MR Imaging. *Radiology* **211**: 609–617.
- Levine, D., Barnes, P.D., Madsen, J.R., Abbott, J., Wong, G.P., Hulka, C., Mehta, T., Li, W., Edelman, R.R. 1999b Fetal CNS anomalies revealed on ultrafast MR imaging. *AJR Am J Roentgenol* **172**: 813–818.
- Levine, D. 2001 Ultrasound versus magnetic resonance imaging in fetal evaluation. *Top Magn Reson Imaging* **12**: 25–38.
- Ludwig, G.D., Struthers, F.W. 1950 Detecting gallstones with ultrasonic echoes. *Electronics* **23**: 172–178.
- Lys, F., De Wals, P., Borlee-Grimee, I., Billiet, A., Vincotte-Mols, M., Levi, S. 1989 Evaluation of routine ultrasound examination for the prenatal diagnosis of malformations. *Eur J Obstet Gynecol Reprod Biol* **30**: 101–109.
- MacVicar, J., Donald, I. 1963 Sonar in the diagnosis of early pregnancy and its complications. *J Obstet Gynaecol Br Commonw* **70**: 387–395.
- Maeno, Y., Himeno, W., Fujino, H., Sugahara, Y., Furui, J., Mizumoto, Y., Kato, H. 1999 Progression of congenital heart disease in the prenatal period. *Pediatr Int* **41**: 709–715.
- Maher, J.E., Colvin, E.V., Samdarshi, T.E., Owen, J., Hauth, J.C. 1994 Fetal echocardiography in gravidas with historic risk factors for congenital heart disease. *Am J Perinatol* **11**: 334–336.
- Mahle, W.T., Clancy, R.R., Moss, E.M., Gerdes, M., Jobes, D.R., Wernovsky, G. 2000 Neurodevelopment outcome and lifestyle assessment in school-aged and adolescent children with hypoplastic left heart syndrome. *Pediatrics* **105**: 1082–1089.
- Maršál, K., Lindblad, A., Lingman, G., Eik-Nes, S.H. 1984 Blood flow in the fetal descending aorta: intrinsic factors affecting fetal blood flow, i.e. fetal breathing movements and cardiac arrhythmia. *Ultrasound Med Biol* **10**: 339–348.
- Martin, G.R., Perry, L.W., Ferencz, C. 1989 Increased prevalence of ventricular septal defect: Epidemic or improved diagnosis. *Pediatrics* **83**: 200–203.
- Mavrides, E., Cobian-Sanchez, F., Tekay, A., Moscoso, G., Campbell, S., Thilaganathan, B., Carvalho, J.S. 2001 Limitations of using first-trimester nuchal translucency measurement in routine screening for major congenital heart defects. *Ultrasound Obstet Gynecol* **17**: 106–110.
- McCallum, W.D., Williams, C.S., Napel, S., Daigle, R.E. 1978 Fetal blood velocity waveforms. *Am J Obstet Gynecol* **132**: 425–429.
- Meberg, A., Otterstad, J.E., Frøland, G., Sørland, S. 1990 Barn med medfødt hjertefeil i Vestfold 1982–88. *Tidsskr Nor Lægeforen* **110**: 354–357.
- Meberg, A., Otterstad, J.E., Frøland, G., Sørland, S., Nitter-Hauge, S. 1994 Increasing incidence of ventricular septal defects caused by improved detection rate. *Acta Paediatr* **83**: 653–657.

- Meberg, A., Otterstad, J.E., Frøland, G., Lindberg, H., Sørland, S.J. 2000 Outcome of congenital heart defects – a population based study. *Acta Paediatr* **89**: 1344–1351.
- Medical diagnostic ultrasound: A retrospective on its 40<sup>th</sup> anniversary. American Institute of Ultrasound in Medicine, Rochester, NY, Eastman Kodak Co, 1988: p. 16.
- Merz, E., Bahlmann, F., Weber, G. 1995 Volume scanning in the evaluation of fetal malformations: a new dimension in prenatal diagnosis. *Ultrasound Obstet Gynecol* **5**: 222–227.
- Meyer, R.A., Hagler, D., Huhta, J., Smallhorn, J., Snider, R., Williams, R. Kleinman, C., Silverman, N.H. 1990 Guidelines for physician training in fetal echocardiography: Recommendations of Society of Pediatric Echocardiography Committee on physician training. *J Am Soc Echocardiogr* **3**: 1–3.
- Meyer-Wittkopf, M., Cooper, S., Vaughan, J., Sholler, G. 2001 Three-dimensional (3D) echocardiography analysis of congenital heart disease in the fetus: comparison with cross-sectional (2D) fetal echocardiography. *Ultrasound Obstet Gynecol* **17**: 485–492.
- Mitchell, S.C., Korones, S.B., Berendes, H.W. 1971 Congenital heart disease in 56,109 births. Incidence and natural history. *Circulation* **43**: 323–332.
- Montaña, E., Khoury, M.J., Cragan, J.D., Sharma, S., Dhar, P., Fyfe, D. 1996 Trends and outcomes after prenatal diagnosis of congenital heart malformations by fetal echocardiography in a well defined birth population, Atlanta, Georgia, 1990–1994. *J Am Coll Cardiol* **28**: 1805–1809.
- Mutterschafts-Richtlinien. Beilage Nr. 4-80 zum Bundesanzeiger Nr. 22 vom 1. Februar 1980. [Guidelines for maternity care] (Suppl.).
- Nafstad, P., Backe, B. 1989 Prevalence and practice of obstetrical ultrasound examinations in Norway. *Tidsskr Nor Lægeforen* **109**: 2975–2978.
- Neilson, J.P., Munjana, S.P., Whitfield, C.R. 1984 Screening for small for dates fetuses: a controlled trial. *Br Med J* **289**: 1179–1182.
- Neilson, J.P. 2004 Ultrasound for fetal assessment in early pregnancy (Cochrane review). In: The Cochrane Library, Issue 3. Chichester, UK: John Wiley & Sons, Ltd.
- Nelson, T.R., Pretorius, D.H., Sklansky, M., Hagen-Ansert, S. 1996 Three-dimensional echocardiographic evaluation of the fetal heart anatomy and function: acquisition, analyses, and display. *J Ultrasound Med* **15**: 1–9.
- Nicolaidis, K.H., Azar, G., Byrne, D., Mansur, C., Marks, K. 1992 Fetal nuchal translucency: ultrasound screening for chromosomal defects in first trimester of pregnancy. *BMJ* **304**: 867–869.
- Nicolaidis, K.H., Sebire, N.J., Snijders, J.M. 1999 The 11–14-week scan. The Parthenon Publishing Group, London, pp. 3–196.

- Nicolaides, K.H., Bindra, R., Heath, V., Cicero, D. 2002 One-stop clinic for assessment of risk of chromosomal defects at 12 weeks gestation. *J Maternal-Fetal Neonatal Med* **12**: 9–10.
- Nicolaides, K.H. 2004 Nuchal translucency and other first-trimester sonographic markers of chromosomal abnormalities. *Am J Obstet Gynecol* **191**: 45–67.
- Nilsson, J., Westling, H. 2004 Ultrasound in Lund – three world premieres. *Clin Physiol Funct Imaging* **24**: 137–140.
- Norges offentlige utredninger, Perinatal omsorg i Norge. NOU 1984:17. Universitetsforlaget, Oslo 1984, pp. 9–118.
- Oberhänsli, I., Extermann, P., Jaggi, E., Pfizenmaier, M. 2000 Fetal echocardiography in pregnancies of women with congenital heart disease – clinical utility and limitations. *Thorac Cardiovasc Surg* **48**: 323–327.
- Olsson, S.B., Lindström, K., Marsal, K. 2004 Echocardiography – The 50<sup>th</sup> anniversary Edler–Hertz meeting 2003. *Clin Physiol Funct Imaging* **24**: 117–178.
- Ott, W.J. 1995 The accuracy of antenatal fetal echocardiography screening in high- and low-risk patients. *Am J Obstet Gynecol* **172**: 1741–1749.
- Paladini, D., Calabro, R., Palmieri, S., D’Andrea, T. 1993 Prenatal diagnosis of congenital heart disease and fetal karyotyping. *Obstet Gynecol* **81**: 679–682.
- Papp, Z., Tóth-Pál, E., Papp, Cs., Tóth, Z., Szabó, M., Veress, L., Török, O. 1995 Impact of prenatal mid-trimester screening on the prevalence of fetal structural anomalies: a prospective epidemiological study. *Ultrasound Obstet Gynecol* **6**: 320–326.
- Peronneau, P., Deloche, A., Bui-Mong-Hung, Hinglais, J. 1969 [Ultrasonic flowmetry – developments and experimental applications]. *Eur Surg Res* **1**: 147–156.
- Powell, M.C., Worthington, B.S., Buckley, J.M., Symonds, E.M. 1988 Magnetic resonance imaging (MRI) in obstetrics. II. Fetal anatomy. *Br J Obstet Gynaecol* **95**: 38–46.
- Pöhls, U.G., Rempfen, A. 1998 Fetal lung volumetry by three-dimensional ultrasound. *Ultrasound Obstet Gynecol* **11**: 6–12.
- Radzik, D., Davignon, A., van Doesburg, N., Fournier, A., Marchand, T., Ducharme, G. 1993 Predictive factors for spontaneous closure of atrial septal defects diagnosed in the 3 first months of life. *J Am Coll Cardiol* **22**: 851–853.
- Roberts, L.J., Bewley, S., Mackinson, A.-M., Rodeck, C.H. 1995 First trimester nuchal translucency: Problems with screening the general population 1. *Br J Obstet Gynaecol* **102**: 381–385.
- Robinson, H.P. 1973 Sonar measurement of fetal crown-rump length as means of assessing maturity in first trimester of pregnancy. *Br Med J* **4**: 28–31.



- Robinson, H.P., Shaw-Dunn, J. 1973 Fetal heart rates as determined by sonar in early pregnancy. *J Obstet Gynaecol Br Commonw* **80**: 805–809.
- Roguin, N., Du, Z.-D., Barak, M., Nasser, N., Hershkowitz, S., Milgram, E. 1995 High prevalence of muscular ventricular septal defects in neonates. *J Am Coll Cardiol* **26**: 1545–1548.
- Rosendahl, H., Kivinen, S. 1989 Antenatal detection of congenital malformations by routine ultrasonography. *Obstet Gynecol* **73**: 947–951.
- Rustico, M.A., Benettoni, A., D'Ottavio, G., Maieron, A., Fischer-Tamaro, I., Conoscenti, G., Meir, Y., Montesano, M., Cattaneo, A., Mandruzzato, G. 1995 Fetal heart screening in low-risk pregnancies. *Ultrasound Obstet Gynecol* **6**: 313–319.
- Rustico, M.A., Benettoni, A., D'Ottavio, G., Fischer-Tamaro, L., Conoscenti, G.C., Meir, Y., Natale, R., Bussani, R., Mandruzzato, G.P. 2000 Early screening for fetal cardiac anomalies by transvaginal echocardiography in an unselected population: the role of operator experience. *Ultrasound Obstet Gynecol* **16**: 614–619.
- Saari-Kemppainen, A., Karjalainen, O., Ylöstalo, P., Heinonen, O.P. 1990 Ultrasound screening and perinatal mortality: controlled trial of systematic one-stage screening in pregnancy. *Lancet* **336**: 387–391.
- Salvesen, K.Å., Eik-Nes, S.H. 1994 The routine fetal examination. In: The fetus as a patient. Kurjac, A., Chervenak, F.A. (eds.) The Parthenon Publishing Group Ltd., New York, USA, pp. 79–88.
- Šamánek, M., Slavík, Z., Zbořilová, B., Hroboňová, V., Voříšková, M., Škovránek, J. 1989 Prevalence, treatment, and outcome of heart disease in live-born children: A prospective analysis of 91,823 live-born children. *Pediatr Cardiol* **10**: 205–211.
- Satomura, S. 1957 Ultrasonic Doppler method for the inspection of cardiac function. *J Acoust Soc Am* **29**: 1181–1185.
- Satomura, S. 1959 Study of the flow patterns in peripheral arteries by ultrasonics. *J Acoust Soc Jpn* **15**: 151–158.
- SBU-rapport nr. 139. 1998 Rutinmässig användning av ultraljud under graviditet i internasjonellt perspektiv. The Swedish Council on Technology Assessment in Health Care. SB Offset AB, Stockholm, pp. 55–67.
- Schwanitz, G., Zerres, K., Gembruch, U., Bald, R., Gamerdinger, F., Hansmann, M. 1990 Prenatal detection of heart defects as an indication for chromosome analysis. *Ann Génét* **33**: 79–83.
- Schwärzler, P., Carvalho, J.S., Senat, M.-V., Masroor, T., Campbell, S., Ville, Y. 1999a Screening for fetal aneuploidies and fetal cardiac abnormalities by nuchal translucency thickness measurement at 10–14 weeks of gestation as part of routine antenatal care in an unselected population. *Br J Obstet Gynecol* **106**: 1029–1034.
- Schwärzler, P., Senat, M.-V., Holden, D., Bernard, J.P., Masroor, T., Ville, Y. 1999b Feasibility of the second-trimester fetal ultrasound examination in an unselected

- population at 18, 20 or 22 weeks of pregnancy: a randomized trial. *Ultrasound Obstet Gynecol* **14**: 92–97.
- Sharland, G.K., Lockhart, S.M., Chita, S.K., Allan, L.D. 1990 Factors influencing the outcome of congenital heart disease detected prenatally. *Arch Dis Child* **65**: 284–287.
- Sharland, G.K., Allan, L.D. 1992 Screening for congenital heart disease prenatally. Results of a 2<sup>1/2</sup>-year study in the South East Thames Region. *Br J Obstet Gynaecol* **99**: 220–225.
- Sharland, G. 2004 Routine fetal cardiac screening: what are we doing and what should we do? *Prenat Diagn* **24**: 1123–1129.
- Sklansky, M.S., Nelson, T.R., Pretorius, D.H. 1998 Three-dimensional fetal echocardiography: Gated versus nongated techniques. *J Ultrasound Med* **17**: 451–457.
- Sklansky, M. 2004 Advances in fetal cardiac imaging. *Pediatr Cardiol* **25**: 307–321.
- Smith, F.W., Adam, A.H., Phillips, W.D.P. 1983 NMR imaging in pregnancy. *Lancet* **1**: 61–62.
- Souka, A.P., Krampfl, E., Bakalis, S., Heath, V., Nicolaides, K.H. 2001 Outcome of pregnancy in chromosomally normal fetuses with increased nuchal translucency in the first trimester. *Ultrasound Obstet Gynecol* **18**: 9–17.
- Stewart, P.A., Wladimiroff, J.W., Reuss, A., Sachs, E.S. 1987 Fetal echocardiography: A review of six years experience. *Fetal Ther* **2**: 222–231.
- Stoll, C., Alembik, Y., Dott, B., Meyer, M.J., Pennerath, A., Peter, M.O., De Geeter, B. 1998 Evaluation of prenatal diagnosis of congenital heart disease. *Prenat Diagn* **18**: 801–807.
- Stoll, C., Alembik, Y., Dott, B., Roth, M.P. 2002 Impact of prenatal diagnosis on livebirth prevalence of children with congenital anomalies. *Ann Génét* **45**: 115–121.
- Stümpflen, I., Stümpflen, A., Wimmer, M., Bernaschek, G. 1996 Effect of detailed fetal echocardiography as part of routine prenatal ultrasonographic screening on detection of congenital heart disease. *Lancet* **348**: 854–857.
- Sundén, B. 1964 On the diagnostic value of ultrasound in obstetrics and gynaecology. *Acta Obstet Gynecol Scand* **43**: Suppl 6: 1–191.
- Takeuchi, H., Nakazawa, T., Kusano, R., Kumakiri, K., Nakano, K., Mizuno, S. 1968 Ultrasonic Doppler method for detecting the fetal heart beat. *Jpn J Med Ultrason* **6**: 80–82.
- Tegnander, E., Eik-Nes, S.H., Linker, D.T. 1994 Incorporating the four-chamber view into the second-trimester routine fetal examination. *Ultrasound Obstet Gynecol* **4**: 24–28.
- Tegnander, E., Eik-Nes, S.H., Johansen, O.J., Linker, D.T. 1995 Prenatal detection of heart defects at the routine fetal examination at 18 weeks in a non-selected population. *Ultrasound Obstet Gynecol* **5**: 372–380.

- Tennstedt, C., Chaoui, R., Körner, H., Dietel, M. 1999 Spectrum of congenital heart defects and extracardiac malformations associated with chromosomal abnormalities: results of a seven year necropsy study. *Heart* **82**: 34–39.
- Todros, T., Faggiano, F., Chiappa, E., Gaglioti, P., Mitola, B., Sciarrone, A., and the Gruppo Piemontese for Perinatal Screening of Congenital Heart Disease. 1997 Accuracy of routine ultrasonography in screening heart disease prenatally. *Prenat Diagn* **17**: 901–906.
- Trines, J., Hornberger, L.K. 2004 Evolution of heart disease *in utero*. *Pediatr Cardiol* **25**: 287–298.
- Trop, I., Lavine, D. 2001 Normal fetal anatomy as visualized with fast magnetic resonance imaging. *Top Magn Reson Imaging* **12**: 3–17.
- Tworetzky, W., McElhinney, D.B., Reddy, V.M., Brook, M.M., Hanley, F.L., Silverman, N.H. 2001 Improved surgical outcome after fetal diagnosis of hypoplastic left heart syndrome. *Circulation* **103**: 1269–1273.
- Vergani, P., Mariani, S., Ghidini, A., Schiavina, R., Cavallone, M., Locatelli, A., Strobelt, N., Cerruti, P. 1992 Screening for congenital heart disease with the four-chamber view of the fetal heart. *Am J Obstet Gynecol* **167**: 1000–1003.
- Vial, Y., Tran, Ch., Addor, M.-C., Hohlfeld, P. 2001 Screening for foetal malformations: performance of routine ultrasonography in the population of the Swiss Canton of Vaud. *Swiss Med Wkly* **131**: 490–494.
- Viñals, F., Tapia, J., Giuliano, A. 2002 Prenatal detection of ductal-dependent congenital heart disease: how can things be made easier? *Ultrasound Obstet Gynecol* **19**: 246–249.
- Viñals, F., Poblete, P., Giuliano, A. 2003 Spatio-temporal image correlation (STIC): a new tool for the prenatal screening of congenital heart defects. *Ultrasound Obstet Gynecol* **22**: 388–394.
- Wakui, K., Tanemura, M., Suzumori, K., Hidaka, E., Ishikawa, M., Kubota, T., Fukushima, Y. 1999 Clinical applications of two-color telomeric fluorescence in situ hybridization for prenatal diagnosis: Identification of chromosomal translocation in five families with recurrent miscarriages or a child with multiple congenital anomalies. *J Hum Genet* **44**: 85–90.
- Waldenström, U., Axelsson, O., Nilsson, S., Eklund, G., Fall, O., Lindeberg, S., Sjödin, Y. 1988 Effects of routine one-stage ultrasound screening in pregnancy: a randomised controlled trial. *Lancet* **2**: 585–588.
- Weinreb, J.C., Lowe, T., Cohen, J.M., Kutler, M. 1985 Human fetal anatomy: MR imaging. *Radiology* **157**: 715–720.
- Wilkins-Haug, L.E., Benson, C.B., Tworetzky, W., Marshall, A.C., Jennings, R.W., Lock, J.E. 2005 *In-utero* intervention for hypoplastic left heart syndrome – a perinatologist’s perspective. *Ultrasound Obstet Gynecol* **26**: 481–486.
- Willocks, J., Donald, I., Duggan, T.C., Day, N. 1964 Foetal cephalometry by ultrasound. *J Obstet Gynaecol Br Commonw* **71**: 11–20.

- Willocks, J., Donald, I., Campbell, S., Dunsmore, I.R. 1967 Intrauterine growth assessed by ultrasonic foetal cephalometry. *J Obstet Gynaecol Br Commonw* **74**: 639–647.
- Wong, S.F., Chan, F.Y., Cincotta, R.B., Lee-Tannock, A., Ward, C. 2003 Factors influencing the prenatal detection of structural congenital heart diseases. *Ultrasound Obstet Gynecol* **21**: 19–25.
- Woo, J. 2005 A short history of the development of ultrasound in obstetrics and gynecology. <http://www.ob-ultrasound.net/history1.html> [Accessed 28 Desember 2005].
- Wren, C., Richmond, S., Donaldson, L. 2000 Temporal variability in birth prevalence of cardiovascular malformations. *Heart* **83**: 414–419.
- Yagel, S., Cohen, S.M., Achiron, R. 2001 Examination of the fetal heart by five short-axis views: a proposed screening method for comprehensive cardiac evaluation. *Ultrasound Obstet Gynecol* **17**: 367–369.
- Yates, R.S. 2004 The influence of prenatal diagnosis on postnatal outcome in patients with structural congenital heart disease. *Prenat Diagn* **24**: 1143–1149.
- Yoo, S.-J., Lee, Y.-H., Kim, E.S., Ryu, H.M., Kim, M.Y., Choi, H.-K., Cho, K.S., Kim, A. 1997 Three-vessel view of the fetal upper mediastinum: an easy means of detecting abnormalities of the ventricular outflow tracts and great arteries during obstetric screening. *Ultrasound Obstet Gynecol* **9**: 173–182.
- Yoo, S.-J., Lee, Y.H., Cho, K.S. 1999 Abnormal three-vessel view on sonography: A clue to the diagnosis of congenital heart disease in the fetus. *AJR Am J Roentgenol* **172**: 825–830.
- Zosmer, N., Souter, V.L., Chan, C.S.Y., Huggon, I.C., Nicolaides, K.H. 1999 Early diagnosis of major cardiac defects in chromosomally normal fetuses with increased nuchal translucency. *Br J Obstet Gynaecol* **106**: 829–833.
- Åmark, K., Mattsson, L.Å., Sunnegårdh, J., Mellander, M. 2004 Begränsad värde av riktad prenatal screening för hjärtmissbildningar. *Läkartidningen* **101**: 3882–3889.

## CORRECTIONS

Paper II      Page 376, second column, line six:  
“Eighteen percent of the critical and 11%...” *should be* “Fifteen percent  
of the critical and 11%...”.

Page 377, Table 10, first line under “Outcome”:  
“Intrauterine fetal death” *should be* “Alive, died 2 days old, Trisomy 18”.



# Paper I

Paper I is not included due to copyright.



## Paper II

Paper II is not included due to copyright.

# Paper III

Paper III is not included due to copyright.

# Paper IV

Paper IV is not included due to copyright.



# Paper V



Paper V is not included due to copyright.



## Dissertations at the Faculty of Medicine, NTNU

1977

1. Knut Joachim Berg: EFFECT OF ACETYLSALICYLIC ACID ON RENAL FUNCTION
2. Karl Erik Viken and Arne Ødegaard: STUDIES ON HUMAN MONOCYTES CULTURED *IN VITRO*

1978

3. Karel Bjørn Cyvin: CONGENITAL DISLOCATION OF THE HIP JOINT.
4. Alf O. Brubakk: METHODS FOR STUDYING FLOW DYNAMICS IN THE LEFT VENTRICLE AND THE AORTA IN MAN.

1979

5. Geirmund Unsgaard: CYTOSTATIC AND IMMUNOREGULATORY ABILITIES OF HUMAN BLOOD MONOCYTES CULTURED IN VITRO

1980

6. Størker Jørstad: URAEMIC TOXINS
7. Arne Olav Jenssen: SOME RHEOLOGICAL, CHEMICAL AND STRUCTURAL PROPERTIES OF MUCOID SPUTUM FROM PATIENTS WITH CHRONIC OBSTRUCTIVE BRONCHITIS

1981

8. Jens Hammerstrøm: CYTOSTATIC AND CYTOLYTIC ACTIVITY OF HUMAN MONOCYTES AND EFFUSION MACROPHAGES AGAINST TUMOR CELLS *IN VITRO*

1983

9. Tore Syversen: EFFECTS OF METHYLMERCURY ON RAT BRAIN PROTEIN.
10. Torbjørn Iversen: SQUAMOUS CELL CARCINOMA OF THE VULVA.

1984

11. Tor-Erik Widerøe: ASPECTS OF CONTINUOUS AMBULATORY PERITONEAL DIALYSIS.
12. Anton Hole: ALTERATIONS OF MONOCYTE AND LYMPHOCYTE FUNCTIONS IN REACTION TO SURGERY UNDER EPIDURAL OR GENERAL ANAESTHESIA.
13. Terje Terjesen: FRACTURE HEALING AND STRESS-PROTECTION AFTER METAL PLATE FIXATION AND EXTERNAL FIXATION.
14. Carsten Saunte: CLUSTER HEADACHE SYNDROME.
15. Inggard Lereim: TRAFFIC ACCIDENTS AND THEIR CONSEQUENCES.
16. Bjørn Magne Eggen: STUDIES IN CYTOTOXICITY IN HUMAN ADHERENT MONONUCLEAR BLOOD CELLS.
17. Trond Haug: FACTORS REGULATING BEHAVIORAL EFFECTS OF DRUGS.

1985

18. Sven Erik Gisvold: RESUSCITATION AFTER COMPLETE GLOBAL BRAIN ISCHEMIA.
19. Terje Espevik: THE CYTOSKELETON OF HUMAN MONOCYTES.
20. Lars Bevanger: STUDIES OF THE Ibc (c) PROTEIN ANTIGENS OF GROUP B STREPTOCOCCI.
21. Ole-Jan Iversen: RETROVIRUS-LIKE PARTICLES IN THE PATHOGENESIS OF PSORIASIS.
22. Lasse Eriksen: EVALUATION AND TREATMENT OF ALCOHOL DEPENDENT BEHAVIOUR.
23. Per I. Lundmo: ANDROGEN METABOLISM IN THE PROSTATE.

1986

24. Dagfinn Berntzen: ANALYSIS AND MANAGEMENT OF EXPERIMENTAL AND CLINICAL PAIN.
25. Odd Arnold Kildahl-Andersen: PRODUCTION AND CHARACTERIZATION OF MONOCYTE-DERIVED CYTOTOXIN AND ITS ROLE IN MONOCYTE-MEDIATED CYTOTOXICITY.

26. Ola Dale: VOLATILE ANAESTHETICS.

1987

27. Per Martin Kleveland: STUDIES ON GASTRIN.
28. Audun N. Øksendal: THE CALCIUM PARADOX AND THE HEART.
29. Vilhjalmur R. Finsen: HIP FRACTURES

1988

30. Rigmor Austgulen: TUMOR NECROSIS FACTOR: A MONOCYTE-DERIVED REGULATOR OF CELLULAR GROWTH.
31. Tom-Harald Edna: HEAD INJURIES ADMITTED TO HOSPITAL.
32. Joseph D. Borsi: NEW ASPECTS OF THE CLINICAL PHARMACOKINETICS OF METHOTREXATE.

33. Olav F. M. Sellevold: GLUCOCORTICOIDS IN MYOCARDIAL PROTECTION.
34. Terje Skjærpe: NONINVASIVE QUANTITATION OF GLOBAL PARAMETERS ON LEFT VENTRICULAR FUNCTION: THE SYSTOLIC PULMONARY ARTERY PRESSURE AND CARDIAC OUTPUT.
35. Eyvind Rødahl: STUDIES OF IMMUNE COMPLEXES AND RETROVIRUS-LIKE ANTIGENS IN PATIENTS WITH ANKYLOSING SPONDYLITIS.
36. Ketil Thorstensen: STUDIES ON THE MECHANISMS OF CELLULAR UPTAKE OF IRON FROM TRANSFERRIN.
37. Anna Midelfart: STUDIES OF THE MECHANISMS OF ION AND FLUID TRANSPORT IN THE BOVINE CORNEA.
38. Eirik Helseth: GROWTH AND PLASMINOGEN ACTIVATOR ACTIVITY OF HUMAN GLIOMAS AND BRAIN METASTASES - WITH SPECIAL REFERENCE TO TRANSFORMING GROWTH FACTOR BETA AND THE EPIDERMAL GROWTH FACTOR RECEPTOR.
39. Petter C. Borchgrevink: MAGNESIUM AND THE ISCHEMIC HEART.
40. Kjell-Arne Rein: THE EFFECT OF EXTRACORPOREAL CIRCULATION ON SUBCUTANEOUS TRANSCAPILLARY FLUID BALANCE.
41. Arne Kristian Sandvik: RAT GASTRIC HISTAMINE.
42. Carl Bredo Dahl: ANIMAL MODELS IN PSYCHIATRY.  
1989
43. Torbjørn A. Fredriksen: CERVICOGENIC HEADACHE.
44. Rolf A. Walstad: CEFTAZIDIME.
45. Rolf Salvesen: THE PUPIL IN CLUSTER HEADACHE.
46. Nils Petter Jørgensen: DRUG EXPOSURE IN EARLY PREGNANCY.
47. Johan C. Ræder: PREMEDICATION AND GENERAL ANAESTHESIA IN OUTPATIENT GYNECOLOGICAL SURGERY.
48. M. R. Shalaby: IMMUNOREGULATORY PROPERTIES OF TNF- $\alpha$  AND THE RELATED CYTOKINES.
49. Anders Waage: THE COMPLEX PATTERN OF CYTOKINES IN SEPTIC SHOCK.
50. Bjarne Christian Eriksen: ELECTROSTIMULATION OF THE PELVIC FLOOR IN FEMALE URINARY INCONTINENCE.
51. Tore B. Halvorsen: PROGNOSTIC FACTORS IN COLORECTAL CANCER.  
1990
52. Asbjørn Nordby: CELLULAR TOXICITY OF ROENTGEN CONTRAST MEDIA.
53. Kåre E. Tvedt: X-RAY MICROANALYSIS OF BIOLOGICAL MATERIAL.
54. Tore C. Stiles: COGNITIVE VULNERABILITY FACTORS IN THE DEVELOPMENT AND MAINTENANCE OF DEPRESSION.
55. Eva Hofslie: TUMOR NECROSIS FACTOR AND MULTIDRUG RESISTANCE.
56. Helge S. Haarstad: TROPHIC EFFECTS OF CHOLECYSTOKININ AND SECRETIN ON THE RAT PANCREAS.
57. Lars Engebretsen: TREATMENT OF ACUTE ANTERIOR CRUCIATE LIGAMENT INJURIES.
58. Tarjei Rygnesstad: DELIBERATE SELF-POISONING IN TRONDHEIM.
59. Arne Z. Henriksen: STUDIES ON CONSERVED ANTIGENIC DOMAINS ON MAJOR OUTER MEMBRANE PROTEINS FROM ENTEROBACTERIA.
60. Steinar Westin: UNEMPLOYMENT AND HEALTH: Medical and social consequences of a factory closure in a ten-year controlled follow-up study.
61. Ylva Sahlin: INJURY REGISTRATION, a tool for accident preventive work.
62. Helge Bjørnstad Pettersen: BIOSYNTHESIS OF COMPLEMENT BY HUMAN ALVEOLAR MACROPHAGES WITH SPECIAL REFERENCE TO SARCOIDOSIS.
63. Berit Schei: TRAPPED IN PAINFUL LOVE.
64. Lars J. Vatten: PROSPECTIVE STUDIES OF THE RISK OF BREAST CANCER IN A COHORT OF NORWEGIAN WOMAN.  
1991
65. Kåre Bergh: APPLICATIONS OF ANTI-C5a SPECIFIC MONOCLONAL ANTIBODIES FOR THE ASSESSMENT OF COMPLEMENT ACTIVATION.
66. Svein Svenningsen: THE CLINICAL SIGNIFICANCE OF INCREASED FEMORAL ANTEVERSION.
67. Olbjørn Klepp: NONSEMINOMATOUS GERM CELL TESTIS CANCER: THERAPEUTIC OUTCOME AND PROGNOSTIC FACTORS.

68. Trond Sand: THE EFFECTS OF CLICK POLARITY ON BRAINSTEM AUDITORY EVOKED POTENTIALS AMPLITUDE, DISPERSION, AND LATENCY VARIABLES.
  69. Kjetil B. Åsbakk: STUDIES OF A PROTEIN FROM PSORIATIC SCALE, PSO P27, WITH RESPECT TO ITS POTENTIAL ROLE IN IMMUNE REACTIONS IN PSORIASIS.
  70. Arnulf Hestnes: STUDIES ON DOWN'S SYNDROME.
  71. Randi Nygaard: LONG-TERM SURVIVAL IN CHILDHOOD LEUKEMIA.
  72. Bjørn Hagen: THIO-TEPA.
  73. Svein Anda: EVALUATION OF THE HIP JOINT BY COMPUTED TOMOGRAPHY AND ULTRASONOGRAPHY.
- 1992
74. Martin Svartberg: AN INVESTIGATION OF PROCESS AND OUTCOME OF SHORT-TERM PSYCHODYNAMIC PSYCHOTHERAPY.
  75. Stig Arild Slørdahl: AORTIC REGURGITATION.
  76. Harold C Sexton: STUDIES RELATING TO THE TREATMENT OF SYMPTOMATIC NON-PSYCHOTIC PATIENTS.
  77. Maurice B. Vincent: VASOACTIVE PEPTIDES IN THE OCULAR/FOREHEAD AREA.
  78. Terje Johannessen: CONTROLLED TRIALS IN SINGLE SUBJECTS.
  79. Turid Nilsen: PYROPHOSPHATE IN HEPATOCYTE IRON METABOLISM.
  80. Olav Haraldseth: NMR SPECTROSCOPY OF CEREBRAL ISCHEMIA AND REPERFUSION IN RAT.
  81. Eiliv Brenna: REGULATION OF FUNCTION AND GROWTH OF THE OXYNTIC MUCOSA.
- 1993
82. Gunnar Bovim: CERVICOGENIC HEADACHE.
  83. Jarl Arne Kahn: ASSISTED PROCREATION.
  84. Bjørn Naume: IMMUNOREGULATORY EFFECTS OF CYTOKINES ON NK CELLS.
  85. Rune Wiseth: AORTIC VALVE REPLACEMENT.
  86. Jie Ming Shen: BLOOD FLOW VELOCITY AND RESPIRATORY STUDIES.
  87. Piotr Kruszewski: SUNCT SYNDROME WITH SPECIAL REFERENCE TO THE AUTONOMIC NERVOUS SYSTEM.
  88. Mette Haase Moen: ENDOMETRIOSIS.
  89. Anne Vik: VASCULAR GAS EMBOLISM DURING AIR INFUSION AND AFTER DECOMPRESSION IN PIGS.
  90. Lars Jacob Stovner: THE CHIARI TYPE I MALFORMATION.
  91. Kjell Å. Salvesen: ROUTINE ULTRASONOGRAPHY IN UTERO AND DEVELOPMENT IN CHILDHOOD.
- 1994
92. Nina-Beate Liabakk: DEVELOPMENT OF IMMUNOASSAYS FOR TNF AND ITS SOLUBLE RECEPTORS.
  93. Sverre Helge Torp: *erbB* ONCOGENES IN HUMAN GLIOMAS AND MENINGIOMAS.
  94. Olav M. Linaker: MENTAL RETARDATION AND PSYCHIATRY. Past and present.
  95. Per Oscar Feet: INCREASED ANTIDEPRESSANT AND ANTIPANIC EFFECT IN COMBINED TREATMENT WITH DIXYRAZINE AND TRICYCLIC ANTIDEPRESSANTS.
  96. Stein Olav Samstad: CROSS SECTIONAL FLOW VELOCITY PROFILES FROM TWO-DIMENSIONAL DOPPLER ULTRASOUND: Studies on early mitral blood flow.
  97. Bjørn Backe: STUDIES IN ANTENATAL CARE.
  98. Gerd Inger Ringdal: QUALITY OF LIFE IN CANCER PATIENTS.
  99. Torvid Kiserud: THE DUCTUS VENOSUS IN THE HUMAN FETUS.
  100. Hans E. Fjøsne: HORMONAL REGULATION OF PROSTATIC METABOLISM.
  101. Eylert Brodtkorb: CLINICAL ASPECTS OF EPILEPSY IN THE MENTALLY RETARDED.
  102. Roar Juul: PEPTIDERGIC MECHANISMS IN HUMAN SUBARACHNOID HEMORRHAGE.
  103. Unni Syversen: CHROMOGRANIN A. Physiological and Clinical Role.
- 1995
104. Odd Gunnar Brakstad: THERMOSTABLE NUCLEASE AND THE *nuc* GENE IN THE DIAGNOSIS OF *Staphylococcus aureus* INFECTIONS.
  105. Terje Engan: NUCLEAR MAGNETIC RESONANCE (NMR) SPECTROSCOPY OF PLASMA IN MALIGNANT DISEASE.
  106. Kirsten Rasmussen: VIOLENCE IN THE MENTALLY DISORDERED.
  107. Finn Egil Skjeldestad: INDUCED ABORTION: Timetrends and Determinants.
  108. Roar Stenseth: THORACIC EPIDURAL ANALGESIA IN AORTOCORONARY BYPASS SURGERY.

109. Arild Faxvaag: STUDIES OF IMMUNE CELL FUNCTION *in mice infected with* MURINE RETROVIRUS.  
1996
110. Svend Aakhus: NONINVASIVE COMPUTERIZED ASSESSMENT OF LEFT VENTRICULAR FUNCTION AND SYSTEMIC ARTERIAL PROPERTIES. Methodology and some clinical applications.
111. Klaus-Dieter Bolz: INTRAVASCULAR ULTRASONOGRAPHY.
112. Petter Aadahl: CARDIOVASCULAR EFFECTS OF THORACIC AORTIC CROSS-CLAMPING.
113. Sigurd Steinshamn: CYTOKINE MEDIATORS DURING GRANULOCYTOPENIC INFECTIONS.
114. Hans Stifoss-Hanssen: SEEKING MEANING OR HAPPINESS?
115. Anne Kvikstad: LIFE CHANGE EVENTS AND MARITAL STATUS IN RELATION TO RISK AND PROGNOSIS OF CANCER.
116. Torbjørn Grøntvedt: TREATMENT OF ACUTE AND CHRONIC ANTERIOR CRUCIATE LIGAMENT INJURIES. A clinical and biomechanical study.
117. Sigrud Hørven Wigers: CLINICAL STUDIES OF FIBROMYALGIA WITH FOCUS ON ETIOLOGY, TREATMENT AND OUTCOME.
118. Jan Schjøtt: MYOCARDIAL PROTECTION: Functional and Metabolic Characteristics of Two Endogenous Protective Principles.
119. Marit Martinussen: STUDIES OF INTESTINAL BLOOD FLOW AND ITS RELATION TO TRANSITIONAL CIRCULATORY ADAPATION IN NEWBORN INFANTS.
120. Tomm B. Müller: MAGNETIC RESONANCE IMAGING IN FOCAL CEREBRAL ISCHEMIA.
121. Rune Haaverstad: OEDEMA FORMATION OF THE LOWER EXTREMITIES.
122. Magne Børset: THE ROLE OF CYTOKINES IN MULTIPLE MYELOMA, WITH SPECIAL REFERENCE TO HEPATOCYTE GROWTH FACTOR.
123. Geir Smedslund: A THEORETICAL AND EMPIRICAL INVESTIGATION OF SMOKING, STRESS AND DISEASE: RESULTS FROM A POPULATION SURVEY.  
1997
124. Torstein Vik: GROWTH, MORBIDITY, AND PSYCHOMOTOR DEVELOPMENT IN INFANTS WHO WERE GROWTH RETARDED *IN UTERO*.
125. Siri Forsmo: ASPECTS AND CONSEQUENCES OF OPPORTUNISTIC SCREENING FOR CERVICAL CANCER. Results based on data from three Norwegian counties.
126. Jon S. Skranes: CEREBRAL MRI AND NEURODEVELOPMENTAL OUTCOME IN VERY LOW BIRTH WEIGHT (VLBW) CHILDREN. A follow-up study of a geographically based year cohort of VLBW children at ages one and six years.
127. Knut Bjørnstad: COMPUTERIZED ECHOCARDIOGRAPHY FOR EVALUATION OF CORONARY ARTERY DISEASE.
128. Grethe Elisabeth Borchgrevink: DIAGNOSIS AND TREATMENT OF WHIPLASH/NECK SPRAIN INJURIES CAUSED BY CAR ACCIDENTS.
129. Tor Elsås: NEUROPEPTIDES AND NITRIC OXIDE SYNTHASE IN OCULAR AUTONOMIC AND SENSORY NERVES.
130. Rolf W. Gråwe: EPIDEMIOLOGICAL AND NEUROPSYCHOLOGICAL PERSPECTIVES ON SCHIZOPHRENIA.
131. Tonje Strømholm: CEREBRAL HAEMODYNAMICS DURING THORACIC AORTIC CROSSCLAMPING. An experimental study in pigs.  
1998
132. Martinus Bråten: STUDIES ON SOME PROBLEMS REALTED TO INTRAMEDULLARY NAILING OF FEMORAL FRACTURES.
133. Ståle Nordgård: PROLIFERATIVE ACTIVITY AND DNA CONTENT AS PROGNOSTIC INDICATORS IN ADENOID CYSTIC CARCINOMA OF THE HEAD AND NECK.
134. Egil Lien: SOLUBLE RECEPTORS FOR TNF AND LPS: RELEASE PATTERN AND POSSIBLE SIGNIFICANCE IN DISEASE.
135. Marit Bjørgaas: HYPOGLYCAEMIA IN CHILDREN WITH DIABETES MELLITUS
136. Frank Skorpen: GENETIC AND FUNCTIONAL ANALYSES OF DNA REPAIR IN HUMAN CELLS.
137. Juan A. Pareja: SUNCT SYNDROME. ON THE CLINICAL PICTURE. ITS DISTINCTION FROM OTHER, SIMILAR HEADACHES.
138. Anders Angelsen: NEUROENDOCRINE CELLS IN HUMAN PROSTATIC CARCINOMAS AND THE PROSTATIC COMPLEX OF RAT, GUINEA PIG, CAT AND DOG.

139. Fabio Antonaci: CHRONIC PAROXYSMAL HEMICRANIA AND HEMICRANIA CONTINUA: TWO DIFFERENT ENTITIES?
140. Sven M. Carlsen: ENDOCRINE AND METABOLIC EFFECTS OF METFORMIN WITH SPECIAL EMPHASIS ON CARDIOVASCULAR RISK FACTORES.  
1999
141. Terje A. Murberg: DEPRESSIVE SYMPTOMS AND COPING AMONG PATIENTS WITH CONGESTIVE HEART FAILURE.
142. Harm-Gerd Karl Blaas: THE EMBRYONIC EXAMINATION. Ultrasound studies on the development of the human embryo.
143. Noëmi Becser Andersen: THE CEPHALIC SENSORY NERVES IN UNILATERAL HEADACHES. Anatomical background and neurophysiological evaluation.
144. Eli-Janne Fiskerstrand: LASER TREATMENT OF PORT WINE STAINS. A study of the efficacy and limitations of the pulsed dye laser. Clinical and morfological analyses aimed at improving the therapeutic outcome.
145. Bård Kulseng: A STUDY OF ALGINATE CAPSULE PROPERTIES AND CYTOKINES IN RELATION TO INSULIN DEPENDENT DIABETES MELLITUS.
146. Terje Haug: STRUCTURE AND REGULATION OF THE HUMAN UNG GENE ENCODING URACIL-DNA GLYCOSYLASE.
147. Heidi Brurok: MANGANESE AND THE HEART. A Magic Metal with Diagnostic and Therapeutic Possibilities.
148. Agnes Kathrine Lie: DIAGNOSIS AND PREVALENCE OF HUMAN PAPILLOMAVIRUS INFECTION IN CERVICAL INTRAEPITHELIAL NEOPLASIA. Relationship to Cell Cycle Regulatory Proteins and HLA DQBI Genes.
149. Ronald Mårvik: PHARMACOLOGICAL, PHYSIOLOGICAL AND PATHOPHYSIOLOGICAL STUDIES ON ISOLATED STOMACS.
150. Ketil Jarl Holen: THE ROLE OF ULTRASONOGRAPHY IN THE DIAGNOSIS AND TREATMENT OF HIP DYSPLASIA IN NEWBORNS.
151. Irene Hetlevik: THE ROLE OF CLINICAL GUIDELINES IN CARDIOVASCULAR RISK INTERVENTION IN GENERAL PRACTICE.
152. Katarina Tunò: ULTRASOUND AND PREDICTION OF GESTATIONAL AGE.
153. Johannes Soma: INTERACTION BETWEEN THE LEFT VENTRICLE AND THE SYSTEMIC ARTERIES.
154. Arild Aamodt: DEVELOPMENT AND PRE-CLINICAL EVALUATION OF A CUSTOM-MADE FEMORAL STEM.
155. Agnar Tegnander: DIAGNOSIS AND FOLLOW-UP OF CHILDREN WITH SUSPECTED OR KNOWN HIP DYSPLASIA.
156. Bent Indredavik: STROKE UNIT TREATMENT: SHORT AND LONG-TERM EFFECTS
157. Jolanta Vanagaite Vingen: PHOTOPHOBIA AND PHONOPHOBIA IN PRIMARY HEADACHES  
2000
158. Ola Dalsegg Sæther: PATHOPHYSIOLOGY DURING PROXIMAL AORTIC CROSS-CLAMPING CLINICAL AND EXPERIMENTAL STUDIES
159. xxxxxxxx (blind number)
160. Christina Vogt Isaksen: PRENATAL ULTRASOUND AND POSTMORTEM FINDINGS – A TEN YEAR CORRELATIVE STUDY OF FETUSES AND INFANTS WITH DEVELOPMENTAL ANOMALIES.
161. Holger Seidel: HIGH-DOSE METHOTREXATE THERAPY IN CHILDREN WITH ACUTE LYMPHOCYTIC LEUKEMIA: DOSE, CONCENTRATION, AND EFFECT CONSIDERATIONS.
162. Stein Hallan: IMPLEMENTATION OF MODERN MEDICAL DECISION ANALYSIS INTO CLINICAL DIAGNOSIS AND TREATMENT.
163. Malcolm Sue-Chu: INVASIVE AND NON-INVASIVE STUDIES IN CROSS-COUNTRY SKIERS WITH ASTHMA-LIKE SYMPTOMS.
164. Ole-Lars Brekke: EFFECTS OF ANTIOXIDANTS AND FATTY ACIDS ON TUMOR NECROSIS FACTOR-INDUCED CYTOTOXICITY.
165. Jan Lundbom: AORTOCORONARY BYPASS SURGERY: CLINICAL ASPECTS, COST CONSIDERATIONS AND WORKING ABILITY.
166. John-Anker Zwart: LUMBAR NERVE ROOT COMPRESSION, BIOCHEMICAL AND NEUROPHYSIOLOGICAL ASPECTS.
167. Geir Falck: HYPEROSMOLALITY AND THE HEART.

168. Eirik Skogvoll: CARDIAC ARREST Incidence, Intervention and Outcome.
169. Dalius Bansevicius: SHOULDER-NECK REGION IN CERTAIN HEADACHES AND CHRONIC PAIN SYNDROMES.
170. Bettina Kinge: REFRACTIVE ERRORS AND BIOMETRIC CHANGES AMONG UNIVERSITY STUDENTS IN NORWAY.
171. Gunnar Qvigstad: CONSEQUENCES OF HYPERGASTRINEMIA IN MAN
172. Hanne Ellekjær: EPIDEMIOLOGICAL STUDIES OF STROKE IN A NORWEGIAN POPULATION. INCIDENCE, RISK FACTORS AND PROGNOSIS
173. Hilde Grimstad: VIOLENCE AGAINST WOMEN AND PREGNANCY OUTCOME.
174. Astrid Hjelde: SURFACE TENSION AND COMPLEMENT ACTIVATION: Factors influencing bubble formation and bubble effects after decompression.
175. Kjell A. Kvistad: MR IN BREAST CANCER – A CLINICAL STUDY.
176. Ivar Rossvoll: ELECTIVE ORTHOPAEDIC SURGERY IN A DEFINED POPULATION. Studies on demand, waiting time for treatment and incapacity for work.
177. Carina Seidel: PROGNOSTIC VALUE AND BIOLOGICAL EFFECTS OF HEPATOCYTE GROWTH FACTOR AND SYNDECAN-1 IN MULTIPLE MYELOMA.
- 2001
178. Alexander Wahba: THE INFLUENCE OF CARDIOPULMONARY BYPASS ON PLATELET FUNCTION AND BLOOD COAGULATION – DETERMINANTS AND CLINICAL CONSEQUENCES
179. Marcus Schmitt-Egenolf: THE RELEVANCE OF THE MAJOR HISTOCOMPATIBILITY COMPLEX FOR THE GENETICS OF PSORIASIS
180. Odrun Arna Gederaas: BIOLOGICAL MECHANISMS INVOLVED IN 5-AMINOLEVULINIC ACID BASED PHOTODYNAMIC THERAPY
181. Pål Richard Romundstad: CANCER INCIDENCE AMONG NORWEGIAN ALUMINIUM WORKERS
182. Henrik Hjorth-Hansen: NOVEL CYTOKINES IN GROWTH CONTROL AND BONE DISEASE OF MULTIPLE MYELOMA
183. Gunnar Morken: SEASONAL VARIATION OF HUMAN MOOD AND BEHAVIOUR
184. Bjørn Olav Haugen: MEASUREMENT OF CARDIAC OUTPUT AND STUDIES OF VELOCITY PROFILES IN AORTIC AND MITRAL FLOW USING TWO- AND THREE-DIMENSIONAL COLOUR FLOW IMAGING
185. Geir Bråthen: THE CLASSIFICATION AND CLINICAL DIAGNOSIS OF ALCOHOL-RELATED SEIZURES
186. Knut Ivar Asarød: RENAL INVOLVEMENT IN INFLAMMATORY RHEUMATIC DISEASE. A Study of Renal Disease in Wegener's Granulomatosis and in Primary Sjögren's Syndrome
187. Trude Helen Flo: RECEPTORS INVOLVED IN CELL ACTIVATION BY DEFINED URONIC ACID POLYMERS AND BACTERIAL COMPONENTS
188. Bodil Kavli: HUMAN URACIL-DNA GLYCOSYLASES FROM THE UNG GENE: STRUCTURAL BASIS FOR SUBSTRATE SPECIFICITY AND REPAIR
189. Liv Thommesen: MOLECULAR MECHANISMS INVOLVED IN TNF- AND GASTRIN-MEDIATED GENE REGULATION
190. Turid Lingaas Holmen: SMOKING AND HEALTH IN ADOLESCENCE; THE NORD-TRØNDELAG HEALTH STUDY, 1995-97
191. Øyvind Hjertner: MULTIPLE MYELOMA: INTERACTIONS BETWEEN MALIGNANT PLASMA CELLS AND THE BONE MICROENVIRONMENT
192. Asbjørn Støylen: STRAIN RATE IMAGING OF THE LEFT VENTRICLE BY ULTRASOUND. FEASIBILITY, CLINICAL VALIDATION AND PHYSIOLOGICAL ASPECTS
193. Kristian Midthjell: DIABETES IN ADULTS IN NORD-TRØNDELAG. PUBLIC HEALTH ASPECTS OF DIABETES MELLITUS IN A LARGE, NON-SELECTED NORWEGIAN POPULATION.
194. Guanglin Cui: FUNCTIONAL ASPECTS OF THE ECL CELL IN RODENTS
195. Ulrik Wisløff: CARDIAC EFFECTS OF AEROBIC ENDURANCE TRAINING: HYPERTROPHY, CONTRACTILITY AND CALCIUM HANDLING IN NORMAL AND FAILING HEART
196. Øyvind Halaas: MECHANISMS OF IMMUNOMODULATION AND CELL-MEDIATED CYTOTOXICITY INDUCED BY BACTERIAL PRODUCTS
197. Tore Amundsen: PERFUSION MR IMAGING IN THE DIAGNOSIS OF PULMONARY EMBOLISM



198. Nanna Kurtze: THE SIGNIFICANCE OF ANXIETY AND DEPRESSION IN FATIGUE AND PATTERNS OF PAIN AMONG INDIVIDUALS DIAGNOSED WITH FIBROMYALGIA: RELATIONS WITH QUALITY OF LIFE, FUNCTIONAL DISABILITY, LIFESTYLE, EMPLOYMENT STATUS, CO-MORBIDITY AND GENDER
199. Tom Ivar Lund Nilsen: PROSPECTIVE STUDIES OF CANCER RISK IN NORD-TRØNDELAGE: THE HUNT STUDY. Associations with anthropometric, socioeconomic, and lifestyle risk factors
200. Asta Kristine Håberg: A NEW APPROACH TO THE STUDY OF MIDDLE CEREBRAL ARTERY OCCLUSION IN THE RAT USING MAGNETIC RESONANCE TECHNIQUES
- 2002
201. Knut Jørgen Arntzen: PREGNANCY AND CYTOKINES
202. Henrik Døllner: INFLAMMATORY MEDIATORS IN PERINATAL INFECTIONS
203. Asta Bye: LOW FAT, LOW LACTOSE DIET USED AS PROPHYLACTIC TREATMENT OF ACUTE INTESTINAL REACTIONS DURING PELVIC RADIOTHERAPY. A PROSPECTIVE RANDOMISED STUDY.
204. Sylvester Moyo: STUDIES ON STREPTOCOCCUS AGALACTIAE (GROUP B STREPTOCOCCUS) SURFACE-ANCHORED MARKERS WITH EMPHASIS ON STRAINS AND HUMAN SERA FROM ZIMBABWE.
205. Knut Hagen: HEAD-HUNT: THE EPIDEMIOLOGY OF HEADACHE IN NORD-TRØNDELAGE
206. Li Lixin: ON THE REGULATION AND ROLE OF UNCOUPLING PROTEIN-2 IN INSULIN PRODUCING  $\beta$ -CELLS
207. Anne Hildur Henriksen: SYMPTOMS OF ALLERGY AND ASTHMA VERSUS MARKERS OF LOWER AIRWAY INFLAMMATION AMONG ADOLESCENTS
208. Egil Andreas Fors: NON-MALIGNANT PAIN IN RELATION TO PSYCHOLOGICAL AND ENVIRONMENTAL FACTORS. EXPERIMENTAL AND CLINICAL STUDIES OF PAIN WITH FOCUS ON FIBROMYALGIA
209. Pål Klepstad: MORPHINE FOR CANCER PAIN
210. Ingunn Bakke: MECHANISMS AND CONSEQUENCES OF PEROXISOME PROLIFERATOR-INDUCED HYPERFUNCTION OF THE RAT GASTRIN PRODUCING CELL
211. Ingrid Susann Gribbestad: MAGNETIC RESONANCE IMAGING AND SPECTROSCOPY OF BREAST CANCER
212. Rønnaug Astri Ødegård: PREECLAMPSIA – MATERNAL RISK FACTORS AND FETAL GROWTH
213. Johan Haux: STUDIES ON CYTOTOXICITY INDUCED BY HUMAN NATURAL KILLER CELLS AND DIGITOXIN
214. Turid Suzanne Berg-Nielsen: PARENTING PRACTICES AND MENTALLY DISORDERED ADOLESCENTS
215. Astrid Rydning: BLOOD FLOW AS A PROTECTIVE FACTOR FOR THE STOMACH MUCOSA. AN EXPERIMENTAL STUDY ON THE ROLE OF MAST CELLS AND SENSORY AFFERENT NEURONS
- 2003
216. Jan Pål Loennechen: HEART FAILURE AFTER MYOCARDIAL INFARCTION. Regional Differences, Myocyte Function, Gene Expression, and Response to Cariporide, Losartan, and Exercise Training.
217. Elisabeth Qvigstad: EFFECTS OF FATTY ACIDS AND OVER-STIMULATION ON INSULIN SECRETION IN MAN
218. Arne Åsberg: EPIDEMIOLOGICAL STUDIES IN HEREDITARY HEMOCHROMATOSIS: PREVALENCE, MORBIDITY AND BENEFIT OF SCREENING.
219. Johan Fredrik Skomsvoll: REPRODUCTIVE OUTCOME IN WOMEN WITH RHEUMATIC DISEASE. A population registry based study of the effects of inflammatory rheumatic disease and connective tissue disease on reproductive outcome in Norwegian women in 1967-1995.
220. Siv Mørkved: URINARY INCONTINENCE DURING PREGNANCY AND AFTER DELIVERY: EFFECT OF PELVIC FLOOR MUSCLE TRAINING IN PREVENTION AND TREATMENT
221. Marit S. Jordhøy: THE IMPACT OF COMPREHENSIVE PALLIATIVE CARE
222. Tom Christian Martinsen: HYPERGASTRINEMIA AND HYPOACIDITY IN RODENTS – CAUSES AND CONSEQUENCES
223. Solveig Tingulstad: CENTRALIZATION OF PRIMARY SURGERY FOR OVARIAN CANCER. FEASIBILITY AND IMPACT ON SURVIVAL

224. Haytham Eloqayli: METABOLIC CHANGES IN THE BRAIN CAUSED BY EPILEPTIC SEIZURES
225. Torunn Bruland: STUDIES OF EARLY RETROVIRUS-HOST INTERACTIONS – VIRAL DETERMINANTS FOR PATHOGENESIS AND THE INFLUENCE OF SEX ON THE SUSCEPTIBILITY TO FRIEND MURINE LEUKAEMIA VIRUS INFECTION
226. Torstein Hole: DOPPLER ECHOCARDIOGRAPHIC EVALUATION OF LEFT VENTRICULAR FUNCTION IN PATIENTS WITH ACUTE MYOCARDIAL INFARCTION
227. Vibeke Nossum: THE EFFECT OF VASCULAR BUBBLES ON ENDOTHELIAL FUNCTION
228. Sigurd Fasting: ROUTINE BASED RECORDING OF ADVERSE EVENTS DURING ANAESTHESIA – APPLICATION IN QUALITY IMPROVEMENT AND SAFETY
229. Solfrid Romundstad: EPIDEMIOLOGICAL STUDIES OF MICROALBUMINURIA. THE NORD-TRØNDELAG HEALTH STUDY 1995-97 (HUNT 2)
230. Geir Torheim: PROCESSING OF DYNAMIC DATA SETS IN MAGNETIC RESONANCE IMAGING
231. Catrine Ahlén: SKIN INFECTIONS IN OCCUPATIONAL SATURATION DIVERS IN THE NORTH SEA AND THE IMPACT OF THE ENVIRONMENT
232. Arnulf Langhammer: RESPIRATORY SYMPTOMS, LUNG FUNCTION AND BONE MINERAL DENSITY IN A COMPREHENSIVE POPULATION SURVEY. THE NORD-TRØNDELAG HEALTH STUDY 1995-97. THE BRONCHIAL OBSTRUCTION IN NORD-TRØNDELAG STUDY
233. Einar Kjelsås: EATING DISORDERS AND PHYSICAL ACTIVITY IN NON-CLINICAL SAMPLES
234. Arne Wibe: RECTAL CANCER TREATMENT IN NORWAY – STANDARDISATION OF SURGERY AND QUALITY ASSURANCE
- 2004
235. Eivind Witsø: BONE GRAFT AS AN ANTIBIOTIC CARRIER
236. Anne Mari Sund: DEVELOPMENT OF DEPRESSIVE SYMPTOMS IN EARLY ADOLESCENCE
237. Hallvard Lærum: EVALUATION OF ELECTRONIC MEDICAL RECORDS – A CLINICAL TASK PERSPECTIVE
238. Gustav Mikkelsen: ACCESSIBILITY OF INFORMATION IN ELECTRONIC PATIENT RECORDS; AN EVALUATION OF THE ROLE OF DATA QUALITY
239. Steinar Krokstad: SOCIOECONOMIC INEQUALITIES IN HEALTH AND DISABILITY. SOCIAL EPIDEMIOLOGY IN THE NORD-TRØNDELAG HEALTH STUDY (HUNT), NORWAY
240. Arne Kristian Myhre: NORMAL VARIATION IN ANOGENITAL ANATOMY AND MICROBIOLOGY IN NON-ABUSED PRESCHOOL CHILDREN
241. Ingunn Dybedal: NEGATIVE REGULATORS OF HEMATOPOIETEC STEM AND PROGENITOR CELLS
242. Beate Sitter: TISSUE CHARACTERIZATION BY HIGH RESOLUTION MAGIC ANGLE SPINNING MR SPECTROSCOPY
243. Per Arne Aas: MACROMOLECULAR MAINTENANCE IN HUMAN CELLS – REPAIR OF URACIL IN DNA AND METHYLATIONS IN DNA AND RNA
244. Anna Bofin: FINE NEEDLE ASPIRATION CYTOLOGY IN THE PRIMARY INVESTIGATION OF BREAST TUMOURS AND IN THE DETERMINATION OF TREATMENT STRATEGIES
245. Jim Aage Nøttestad: DEINSTITUTIONALIZATION AND MENTAL HEALTH CHANGES AMONG PEOPLE WITH MENTAL RETARDATION
246. Reidar Fossmark: GASTRIC CANCER IN JAPANESE COTTON RATS
247. Wibeke Nordhøy: MANGANESE AND THE HEART, INTRACELLULAR MR RELAXATION AND WATER EXCHANGE ACROSS THE CARDIAC CELL MEMBRANE
- 2005
248. Sturla Molden: QUANTITATIVE ANALYSES OF SINGLE UNITS RECORDED FROM THE HIPPOCAMPUS AND ENTORHINAL CORTEX OF BEHAVING RATS
249. Wenche Brenne Drøyvold: EPIDEMIOLOGICAL STUDIES ON WEIGHT CHANGE AND HEALTH IN A LARGE POPULATION. THE NORD-TRØNDELAG HEALTH STUDY (HUNT)
250. Ragnhild Støen: ENDOTHELIUM-DEPENDENT VASODILATION IN THE FEMORAL ARTERY OF DEVELOPING PIGLETS

251. Aslak Steinsbekk: HOMEOPATHY IN THE PREVENTION OF UPPER RESPIRATORY TRACT INFECTIONS IN CHILDREN
252. Hill-Aina Steffenach: MEMORY IN HIPPOCAMPAL AND CORTICO-HIPPOCAMPAL CIRCUITS
253. Eystein Stordal: ASPECTS OF THE EPIDEMIOLOGY OF DEPRESSIONS BASED ON SELF-RATING IN A LARGE GENERAL HEALTH STUDY (THE HUNT-2 STUDY)
254. Viggo Pettersen: FROM MUSCLES TO SINGING: THE ACTIVITY OF ACCESSORY BREATHING MUSCLES AND THORAX MOVEMENT IN CLASSICAL SINGING
255. Marianne Fyhn: SPATIAL MAPS IN THE HIPPOCAMPUS AND ENTORHINAL CORTEX
256. Robert Valderhaug: OBSESSIVE-COMPULSIVE DISORDER AMONG CHILDREN AND ADOLESCENTS: CHARACTERISTICS AND PSYCHOLOGICAL MANAGEMENT OF PATIENTS IN OUTPATIENT PSYCHIATRIC CLINICS
257. Erik Skaaheim Haug: INFRARENAL ABDOMINAL AORTIC ANEURYSMS – COMORBIDITY AND RESULTS FOLLOWING OPEN SURGERY
258. Daniel Kondziella: GLIAL-NEURONAL INTERACTIONS IN EXPERIMENTAL BRAIN DISORDERS
259. Vegard Heimly Brun: ROUTES TO SPATIAL MEMORY IN HIPPOCAMPAL PLACE CELLS
260. Kenneth McMillan: PHYSIOLOGICAL ASSESSMENT AND TRAINING OF ENDURANCE AND STRENGTH IN PROFESSIONAL YOUTH SOCCER PLAYERS
261. Marit Sæbø Indredavik: MENTAL HEALTH AND CEREBRAL MAGNETIC RESONANCE IMAGING IN ADOLESCENTS WITH LOW BIRTH WEIGHT
262. Ole Johan Kemi: ON THE CELLULAR BASIS OF AEROBIC FITNESS, INTENSITY-DEPENDENCE AND TIME-COURSE OF CARDIOMYOCYTE AND ENDOTHELIAL ADAPTATIONS TO EXERCISE TRAINING
263. Eszter Vanky: POLYCYSTIC OVARY SYNDROME – METFORMIN TREATMENT IN PREGNANCY
264. Hild Fjærtøft: EXTENDED STROKE UNIT SERVICE AND EARLY SUPPORTED DISCHARGE. SHORT AND LONG-TERM EFFECTS
265. Grete Dyb: POSTTRAUMATIC STRESS REACTIONS IN CHILDREN AND ADOLESCENTS
266. Vidar Fykse: SOMATOSTATIN AND THE STOMACH
267. Kirsti Berg: OXIDATIVE STRESS AND THE ISCHEMIC HEART: A STUDY IN PATIENTS UNDERGOING CORONARY REVASCLARIZATION
268. Björn Inge Gustafsson: THE SEROTONIN PRODUCING ENTEROCHROMAFFIN CELL, AND EFFECTS OF HYPERSEROTONINEMIA ON HEART AND BONE
- 2006
269. Torstein Baade Rø: EFFECTS OF BONE MORPHOGENETIC PROTEINS, HEPATOCYTE GROWTH FACTOR AND INTERLEUKIN-21 IN MULTIPLE MYELOMA
270. May-Britt Tessem: METABOLIC EFFECTS OF ULTRAVIOLET RADIATION ON THE ANTERIOR PART OF THE EYE
271. Anne-Sofie Helvik: COPING AND EVERYDAY LIFE IN A POPULATION OF ADULTS WITH HEARING IMPAIRMENT
272. Therese Standal: MULTIPLE MYELOMA: THE INTERPLAY BETWEEN MALIGNANT PLASMA CELLS AND THE BONE MARROW MICROENVIRONMENT
273. Ingvild Saltvedt: TREATMENT OF ACUTELY SICK, FRAIL ELDERLY PATIENTS IN A GERIATRIC EVALUATION AND MANAGEMENT UNIT – RESULTS FROM A PROSPECTIVE RANDOMISED TRIAL
274. Birger Henning Endreseth: STRATEGIES IN RECTAL CANCER TREATMENT – FOCUS ON EARLY RECTAL CANCER AND THE INFLUENCE OF AGE ON PROGNOSIS
275. Anne Mari Aukan Rokstad: ALGINATE CAPSULES AS BIOREACTORS FOR CELL THERAPY
276. Mansour Akbari: HUMAN BASE EXCISION REPAIR FOR PRESERVATION OF GENOMIC STABILITY
277. Stein Sundstrøm: IMPROVING TREATMENT IN PATIENTS WITH LUNG CANCER – RESULTS FROM TWO MULTICENTRE RANDOMISED STUDIES
278. Hilde Pleym: BLEEDING AFTER CORONARY ARTERY BYPASS SURGERY - STUDIES ON HEMOSTATIC MECHANISMS, PROPHYLACTIC DRUG TREATMENT AND EFFECTS OF AUTOTRANSFUSION
279. Line Merethe Oldervoll: PHYSICAL ACTIVITY AND EXERCISE INTERVENTIONS IN CANCER PATIENTS

- 280.Boye Welde: THE SIGNIFICANCE OF ENDURANCE TRAINING, RESISTANCE TRAINING AND MOTIVATIONAL STYLES IN ATHLETIC PERFORMANCE AMONG ELITE JUNIOR CROSS-COUNTRY SKIERS
- 281.Per Olav Vandvik: IRRITABLE BOWEL SYNDROME IN NORWAY, STUDIES OF PREVALENCE, DIAGNOSIS AND CHARACTERISTICS IN GENERAL PRACTICE AND IN THE POPULATION
- 282.Idar Kirkeby-Garstad: CLINICAL PHYSIOLOGY OF EARLY MOBILIZATION AFTER CARDIAC SURGERY
- 283.Linn Getz: SUSTAINABLE AND RESPONSIBLE PREVENTIVE MEDICINE. CONCEPTUALISING ETHICAL DILEMMAS ARISING FROM CLINICAL IMPLEMENTATION OF ADVANCING MEDICAL TECHNOLOGY
- 284.Eva Tegnander: DETECTION OF CONGENITAL HEART DEFECTS IN A NON-SELECTED POPULATION OF 42,381 FETUSES