



# Neuron-Specific Enolase as an Immunohistochemical Marker Is Better Than Its Reputation

Patricia Mjønes, Liv Sagatun, Ivar S. Nordrum, and Helge L. Waldum

Department of Gastroenterology and Hepatology (LS, HLW) and Department of Pathology (PM, ISN), St. Olav's Hospital, Trondheim University Hospital, Trondheim, Norway, and Department of Cancer Research and Molecular Medicine, Faculty of Medicine and Health Sciences (PM, LS, HLW) and Department of Laboratory Medicine, Children's and Woman's Health (PM, ISN), Norwegian University of Science and Technology, Trondheim, Norway

## Summary

The diagnosis of neuroendocrine neoplasms (NENs) may be challenging and is based on typical morphological features and positive staining for antibodies of neuroendocrine differentiation. Neuron-specific enolase (NSE) being a cytosolic marker may be useful in this setting. NSE is by many considered nonspecific, due to the finding of this marker in tumors considered not to be of neuroendocrine origin. Our aim was to determine whether this is true and whether NSE is more specific than previously realized. We examined 178 tumors (carcinomas and NENs) from breast, lung, stomach, and kidney using immunohistochemistry with the following markers: chromogranin A, synaptophysin, CD56, secretagogin, and NSE. Expression of NSE was compared with that of the other markers. NSE was expressed in 138 (78%) of all tumors. Of the NSE-expressing tumors, 95 (68%) cases expressed one or more additional neuroendocrine markers. The staining intensity and number of NSE-expressing tumor cells were highest among tumors of neuroendocrine origin and clear cell renal cell carcinomas. A positive association was found between NSE expression and the number of additional neuroendocrine markers expressed in each of the tumors. Practically all tumors positive for an accepted neuroendocrine marker also expressed NSE. (*J Histochem Cytochem* 65:687–703, 2017)

## Keywords

carcinoid, CgA, chromogranin A, neuroendocrine tumor, neuron-specific enolase, NSE, secretagogin, synaptophysin

## Introduction

The incidence and prevalence of neuroendocrine neoplasms (NENs) have been increasing over the past years partly due to increased awareness and improvements in instrumental diagnostic techniques. Regardless of organ, the diagnosis of NENs may be challenging due to the heterogeneous nature of these tumors. Correct diagnosis is of importance to give patients the right treatment. The diagnosis of NENs is based on a characteristic morphological appearance and a positive reaction in the tumor cells for at least two neuroendocrine (NE) markers,<sup>1</sup> the latter is usually done with the aid of immunohistochemistry (IHC) by using antibodies against general cytosolic and granular NE markers. Chromogranin A (CgA) and

synaptophysin are currently considered to be the most sensitive and specific markers of NE differentiation that are used in the routine diagnostic setting.<sup>2,3</sup> NE markers used in IHC are usually associated with secretory granules, small vesicles, or elements of the cytosol. CgA and synaptophysin are beneficial for well-differentiated NENs, but are less helpful in the diagnosis of poorly differentiated NENs, partly due to

Received for publication June 12, 2017; accepted September 1, 2017.

## Corresponding Author:

Patricia Mjønes, Department of Cancer Research and Molecular Medicine, Norwegian University of Science and Technology, PO Box 8905 MTF, NO-7491 Trondheim, Norway.  
E-mail: patricia.mjones@ntnu.no

dedifferentiation and subsequently degranulation of tumor cells; thus, the application of more sensitive markers is necessary.

Neuron-specific enolase (NSE) was introduced as a marker for NE cells particularly to be used in diagnosis of malignant tumors, and it was the first marker used to identify NE cells.<sup>4</sup> However, it got a bad reputation as positivity for this marker was found not only in accepted NENs but also in tumors classified as adenocarcinomas or undifferentiated carcinomas. The specificity of NSE was therefore considered limited,<sup>4,5</sup> and, thus, pathologists often used the term “nonspecific enolase” for this marker. Enolases are dimers consisting of three distinct subunits;  $\alpha$ ,  $\beta$ , and  $\gamma$ , and are glycolytic enzymes widely distributed in mammals. High levels of NSE are present in neuronal and NE cells as  $\alpha\gamma$  or  $\gamma\gamma$  forms, and in tumors derived from these cells.<sup>6</sup> The downside to the antibody used in NSE detection, which is an antibody against the  $\gamma\gamma$  form, is cross-reactivity with the  $\alpha\gamma$  form of enolase, which is found in lymphocytes, myoepithelial cells, and smooth muscle cells.<sup>7</sup> Moderate levels of this protein have also been found in tumors believed not to be of NE origin.<sup>8</sup> Even though NSE is often regarded as a rather unspecific marker for NE differentiation, NSE is observed in the majority of NE tumors,<sup>9</sup> and because it is a cytosolic marker, it can even be detected in degranulated tumor cells.<sup>10,11</sup> It has been increasingly evident that many tumors previously classified as adenocarcinomas or undifferentiated carcinomas are, in fact, NE carcinomas, or at least have areas of NE differentiation.<sup>12–14</sup> Moreover, before the development of antibodies against NE specific polypeptides, normal and neoplastic NE cells were identified by the use of morphological criteria alone, and a number of tumors of NE origin may therefore have been missed in the past. Therefore, it is possible that many of the reclassified tumors also are NSE positive, and that NSE, nevertheless, is a useful marker.

CD56, also known as neural cell adhesion molecule (NCAM), is another marker used in the diagnosis of NE differentiation, and is a glycoprotein involved in cell-binding, migration, and differentiation.<sup>15</sup> NE cells and tumors containing neurosecretory granules tend to express both CD56 mRNA and protein.<sup>16</sup> Although there have been questions raised with regard to the specificity of this marker, it seems to be useful in the diagnosis of small cell lung carcinoma (SCLC).<sup>17</sup> Secretagogin, a calcium-binding protein, is currently not in use in the routine diagnosis of NENs. It is, however, found to be co-localized with other accepted markers like CgA and synaptophysin, and is therefore considered to be useful in the diagnosis of NENs.<sup>18,19</sup> In addition to the above-mentioned markers, other markers of NE differentiation of more limited value

include protein gene product (PGP 9.5) and LEU7 (CD57).

The aim of our study was 2-fold. First, we wished to explore whether NSE as a marker of NE differentiation is better than its reputation; is NSE a specific as well as sensitive marker of NE differentiation? This was done by examining 178 tumors from breast, lung, stomach, and kidney with an antibody against NSE, and comparing the results with other NE markers like CgA, synaptophysin, CD56, and secretagogin. We wanted to see if all tumors positive for one of the other NE markers also express NSE. Second, we wanted to further explore the expression of secretagogin and determine whether this marker could be of use in the diagnosis of NE differentiation in tumors.

## Materials and Methods

### Patients

Tumor tissue from 178 patients who were surgically treated for tumors of the breast, lung, stomach, or kidney at St. Olav's Hospital—Trondheim University Hospital between 1995 and 2016 were included in the study. The patients were identified from previous studies<sup>20,21</sup> and by going through our records at the pathology and gastroenterology departments. To limit the study, only four tumor locations were evaluated, and the selection criteria were as follows: Various types of carcinomas and NENs from breast, lung, stomach, and kidney that were available in the archives at the pathology or gastroenterology departments were included in the study. For practical reasons, most of the tumors were from before the year 2000. Of the breast and lung tumors, we aimed to examine approximately equal amounts of the most common subtypes, and when other subtypes were found, these were also added to the study population. The tumors from breast and lung were identified by going through the records at the pathology department. The number of stomach tumors examined was limited due to lack of tumor tissue in the archives caused by material being used in previous studies. Patients diagnosed with adenocarcinoma of diffuse, intestinal, or mixed/indeterminate types according to Laurén, or NENs according to the World Health Organization (WHO), were included. In all, 14 tumors from the stomach were identified from an unpublished study and 13 cases from the archives at the pathology department. Of the 14 cases identified previously, examination with markers against CgA and synaptophysin were already performed, and not repeated in this study. Examination with the other NE markers (NSE and secretagogin), however, was performed as described below. Carcinomas of the breast, lung, and stomach are known to occasionally express

NE markers, and we wanted to see whether the same areas expressing other NE markers also expressed NSE. All 45 patients with kidney cancer were identified from a previous study,<sup>20</sup> and included cases of clear cell renal cell carcinoma (CCRCC), papillary renal cell carcinoma (PRCC) type 1 and type 2, and chromophobe renal cell carcinoma (chRCC). The renal cell carcinomas (RCCs) were already explored with markers against CgA, synaptophysin, NSE, and erythropoietin, and not repeated in this study. In a previous study, we found that all CCRCCs expressing NSE also express erythropoietin, a hormone, thus, we wished to explore this further by using secretagogin as described below. As tissue microarray (TMA) blocks had not been made for 14 stomach cancers and RCCs identified from previous studies, whole sections were also used for the remaining markers examined for these cases.

### *Specimen Characteristics*

Formalin-fixed, paraffin-embedded (FFPE) tissue from 178 patients was collected from the archives and used in this study. All tumors were previously classified into histopathological type, and in relation to this study, reclassified according to the most recent WHO classifications<sup>22–25</sup> and according to Laurén.<sup>26</sup> *American Joint Committee on Cancer (AJCC) Cancer Staging Manual* (8th ed.) was used to stage the tumor.<sup>27</sup> Tumor size was, when available, noted and was defined as the area with greatest diameter recorded in the pathology report. Sections were stained with either hematoxylin and eosin (HE) or hematoxylin, eosin, and saffron (HES). They were then reviewed, and representative tumor areas were selected for further evaluation. From all lung and breast tumors and from 13 stomach tumors, TMAs were constructed by using an advanced tissue arrayer ATA-100 (Chemicon International, Temecula, CA). Three cylindrical tissue cores with a diameter of 1 mm were taken from paraffin blocks with tumor tissue, and reembedded into a recipient microarray block at defined microarray coordinates. In cases where tumor tissue was not observed in the TMA sections, the above step was repeated, and new TMA blocks were made. A total of 10 TMA blocks, each containing tumor tissue from 8 to 20 tumors, were put together. TMA blocks were not constructed from the remaining 14 stomach tumors and the 45 kidney tumors. In these cases, whole sections from the tumors were used.

Immunohistochemical stainings with antibodies against NSE, CgA, synaptophysin, and secretagogin were performed. By conducting these studies, we wished to find out whether all tumors positive for CgA, synaptophysin, CD56, and/or secretagogin also

expressed NSE, and whether these markers are expressed in the same areas of the tumor.

### *Histopathology and IHC*

From FFPE tissue blocks, 4 µm thick sections were cut and afterward transferred to SuperFrost slides (Thermo Scientific, Braunschweig, Germany). The sections were dried at room temperature overnight before being baked in a heat cabinet for 60 min at 60°C, and subsequently deparaffinized in Neo-Clear (Merck KGaA, Darmstadt, Germany). They were then rinsed in decreasing concentrations of alcohol down to water, before being put in a bath of 0.3% hydrogen peroxide for 10 min. After immersing the sections in a bath of epitope retrieval solution, they were put in a microwave oven at 160W for 15 min. Tris/EDTA (pH 9) was used as epitope retrieval solution for all antibodies. Thereafter, the sections were cooled for 15 min at room temperature before being washed in a wash buffer solution. A TNT wash buffer—based on 0.1 M Trizma hydrochloride, 0.15 M NaCl, and 0.05% Tween 20 (VWR, Briare, France), pH 7.5—was used for all the washing steps. For approximately 1 hr at room temperature, the sections were incubated with a primary antibody. The following antibodies were used in this study: CgA (M0869, Dako, Glostrup, Denmark, 1:200), synaptophysin (M7315, Dako, 1:200), NSE (BBS/NC/VI-H14, Dako, 1:200), CD56 (123C3, Dako, 1:50), and secretagogin (MAb 4878, R&D Systems, Minneapolis, MN, 1:200). To further amplify the signal, Mouse Link (K8021, Dako) was used with the monoclonal mouse antibodies (CgA, synaptophysin, NSE, CD56, and secretagogin). All antibodies were visualized by using an EnVision-HRP kit with DAB+ (K5007, Dako). The sections were incubated with EnVision for 30 min before being developed using DAB+. The sections were subsequently counterstained with Mayer's hematoxylin (Sigma Life Science, Saint Louis, MO) for 10 sec. Mouse IgG2b (X0944, Dako) was used as a negative isotype control for CgA, and mouse IgG1 (X0931, Dako) was used for synaptophysin, NSE, CD56, and secretagogin. A wash buffer solution was used between all steps after incubation with primary antibody. For all antibodies, a known neuroendocrine tumor (NET) of the stomach was used as a positive control. The surrounding connective tissue was used as a negative control.

### *Scoring and Reporting*

A bright field microscope (Olympus CX41; Olympus Optical Co. [Europa] GMBH, Hamburg, Germany) was used to examine the sections. IHC markers were assessed by one researcher. When there were any uncertainties with regard to results, a second pathologist/researcher was consulted.

### Classification of Tumors

The tumors were reclassified according to the most recent WHO classifications<sup>22–25</sup> and according to Laurén.<sup>26</sup> The breast tumors were classified into invasive carcinoma of no special type (previously known as invasive ductal carcinoma), invasive lobular carcinoma, medullary carcinoma, and carcinoma with NE features. The lung tumors were classified into carcinoid tumors (consisting of typical and atypical carcinoid tumors of the lung), SCLC, and non–small cell lung carcinomas (NSCLC; consisting of squamous cell carcinoma, adenocarcinoma, large cell carcinoma, and large cell NE carcinoma). Tumors of the stomach were classified according to Laurén into diffuse, intestinal, or mixed/indeterminate types, and according to the WHO into NENs. In the present study, mixed and indeterminate types are described together. The NENs are subdivided into NETs grade 1 or 2, or NE carcinoma (grade 3) depending on the proliferative index of these tumors. The kidney tumors were classified according to the WHO into CCRCC and non-CCRCC, the latter group consisting of PRCC type 1 and type 2, and ChRCC.

### Classification of Markers

The expression of the various markers was classified as positive or negative, and the number of positive cancer cells expressing each of the markers was also noted. If less than 2% of the cancer cells stained positive, the staining was reported as negative. The expression was considered low if 2–10% of cancer cells were positive, moderate if there were 10–40% positive cells, high when 40–70% of cells were positive, and very high if more than 70% of cells expressed the marker. *RE*porting recommendations for tumor *MARK*er prognostic studies (*REMARK*) with a few minor modifications were used.<sup>28</sup>

### Statistical Analysis

For calculation of median and mean values as well as range for the different parameters, IBM SPSS statistics v22 (Chicago, IL) was used. The descriptive data are presented as median or mean as appropriate. To look for association between the various variables, Spearman's nonparametric test was used.

## Results

### Patient and Tumor Characteristics

Of all the 178 patients included in the study, 86 (48%) were female and 92 (52%) male. At the time of diagnosis, their median age was 66 (range: 32–87) years. At follow-up, 116 patients were dead and 62 alive. Of the

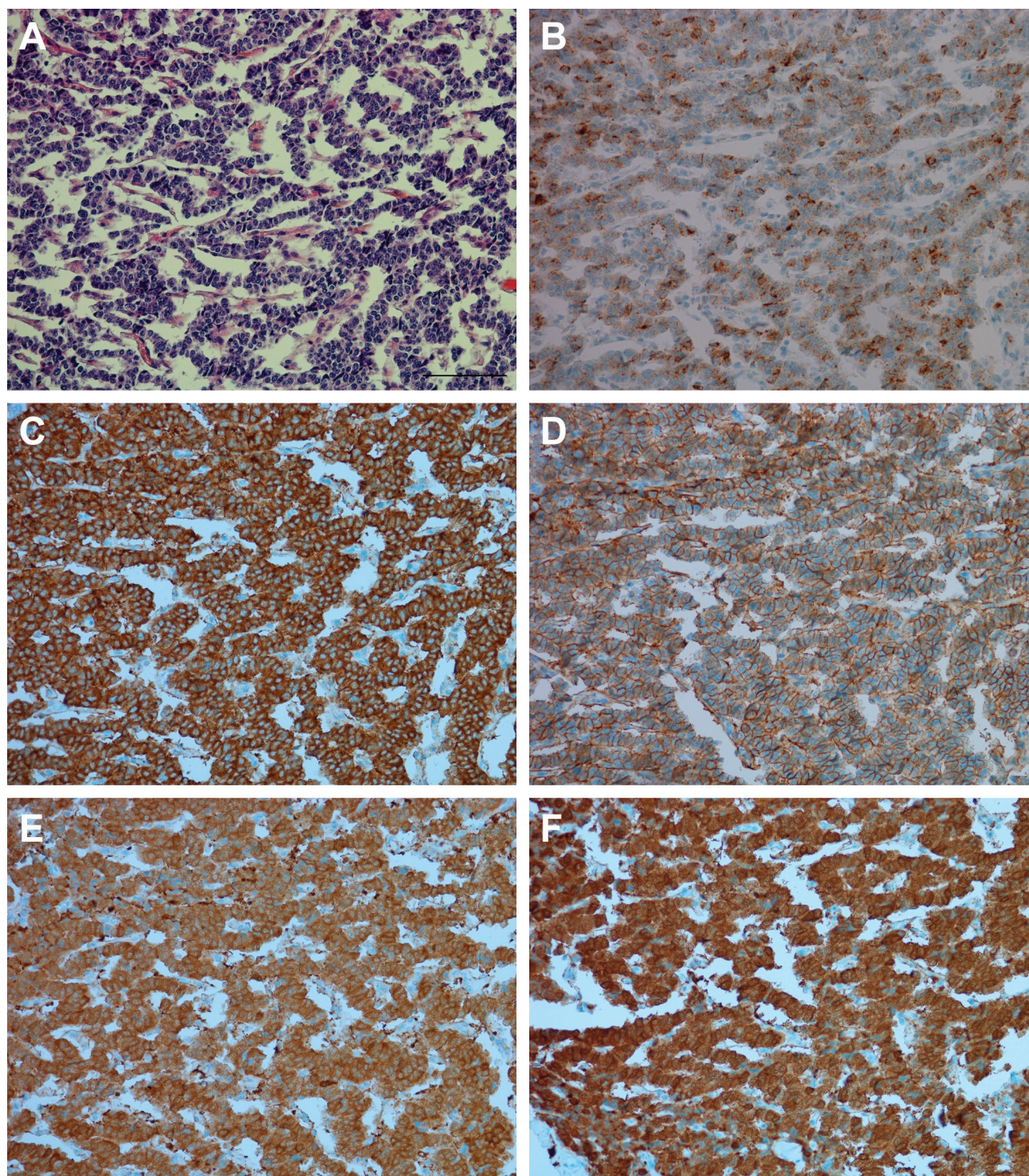
patients still alive, 11 were diagnosed with cancer of the breast, 7 with cancer of the lung, 6 with cancer of the stomach, and 38 with cancer of the kidney. Of the tumors removed, 37 (21%) were from breast, 69 (39%) from lung, 27 (15%) from stomach, and 45 (25%) from kidney.

**Breast.** A total of 37 (21%) tumors were from breast, all of the patients female. The median age of these patients was 67 (range: 46–87) years. In total, 21 (57%) patients with tumors of the breast were diagnosed with invasive carcinoma of no special type, 13 (35%) with invasive lobular carcinoma, 2 (5%) with medullary carcinoma, and 1 (3%) case with carcinoma with NE features. Mean tumor size registered in the pathology report was 4.3 (range: 1.0–15.0) cm with SD 2.5. When classified in accordance with the TNM classification system, 5 (14%) tumors were in the T1 category, 17 (46%) in the T2 category, 12 (32%) in the T3 category, and 3 (8%) in the T4 category.

**Lung.** A total of 69 (39%) tumors were from the lung, where 25 (36%) were from female, and 44 (64%) from male patients. The median age of these patients was 66 (range: 33–84) years. A total of 22 (32%) were diagnosed with squamous cell carcinoma, 23 (33%) with adenocarcinoma, 3 (4%) with large cell carcinoma, 4 (6%) with large cell NE carcinoma, 7 (10%) with SCLC, and 9 (13%) with carcinoid tumor. One (1%) patient was diagnosed with adenocarcinoma, which most likely represented metastasis from the uterus. Mean tumor size registered in the pathology report was 4.0 (range: 1.2–13.0) cm with SD 2.1. In all, 18 (26%) tumors were in the T1 category, 28 (41%) in the T2 category, 13 (19%) in the T3 category, and 10 (14%) in the T4 category. Figures 1 and 2 illustrate the expression of the various markers in carcinoid (typical) and SCLC. The carcinoid tumor expresses all the NE markers, whereas in the SCLC, expression of CgA and synaptophysin is weak compared with the other markers.

**Stomach.** In total, 27 (15%) of 178 tumors were from the stomach, and of these, 15 (56%) were from female and 12 (44%) from male patients. Their median age was 70 (range: 32–80) years. A total of 10 (37%) stomach tumors were adenocarcinoma of intestinal type, 7 (26%) of diffuse type, and 2 (7%) of mixed/indeterminate type. The remaining eight (30%) were NENs: Six (22%) of these were NETs (four grade 1, two grade 2) and two were NECs. The mean tumor size registered in the pathology report was 4.6 (range: 0.4–13.0) cm with SD 3.1. Nine (33%) of the 27 stomach tumors were in the T1 category, 5 (19%) T2, 11 (41%) T3, and 2 (7%) T4. Figure 3 illustrates





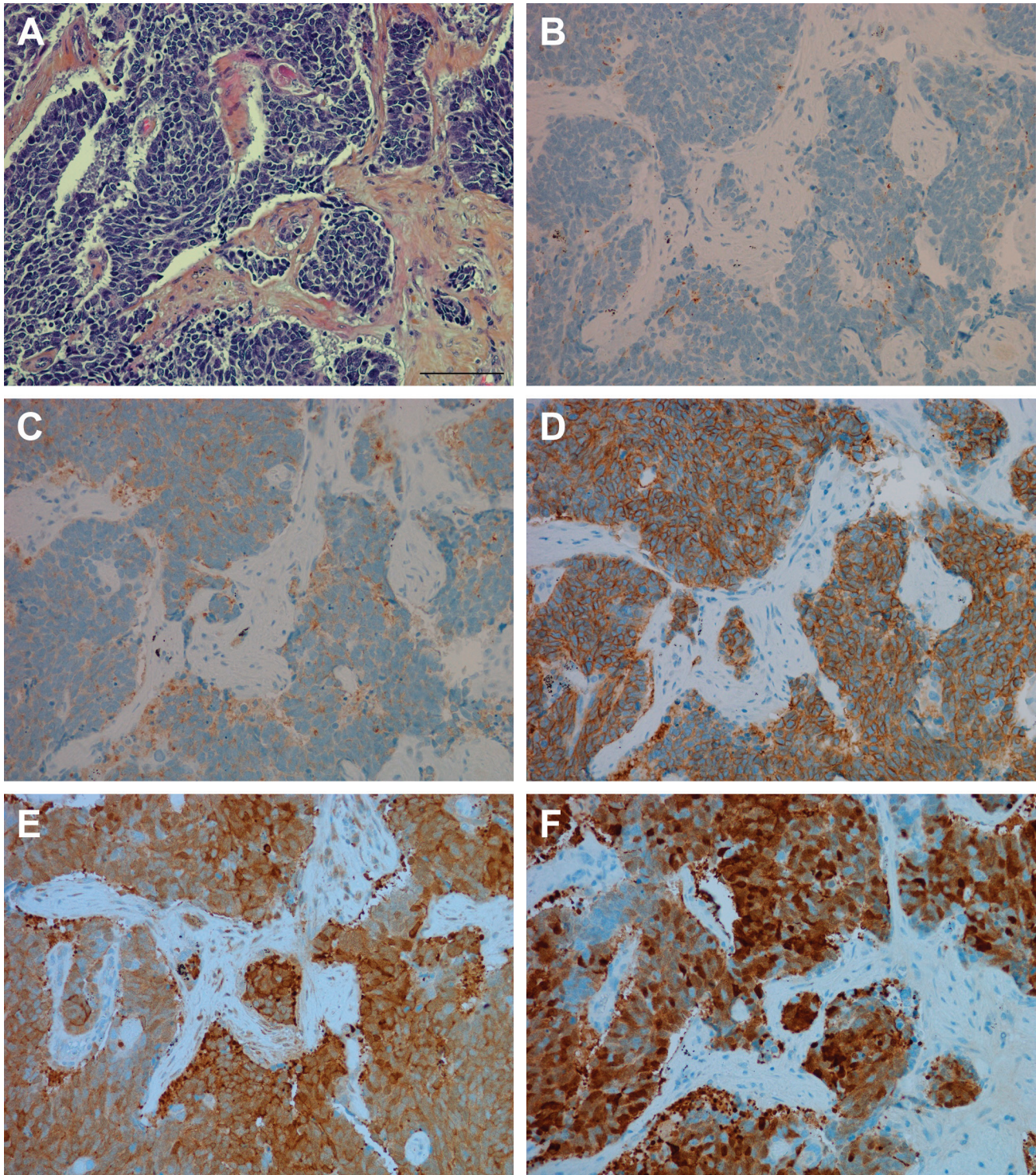
**Figure 1.** Lung with typical carcinoid tumor illustrated by (A) hematoxylin, eosin, and saffron (HES); (B) chromogranin A; (C) synaptophysin; (D) CD56; (E) neuron-specific enolase (NSE); and (F) Secretagoin. Scale bar = 100  $\mu$ m.

the expression of NE markers in adenocarcinoma of intestinal type.

*Kidney.* Of the 178 tumors, 45 (25%) were from the kidney. Nine (20%) of these were from female and 36

(80%) from male patients. The median age of the patients was 60 (range: 37–82) years. In all, 34 (76%) were CCRCC, and the remaining 11 (24%) were non-CCRCC. Of the non-CCRCC, seven (64%) were PRCC type 1, two (18%) PRCC type 2, and two (18%)





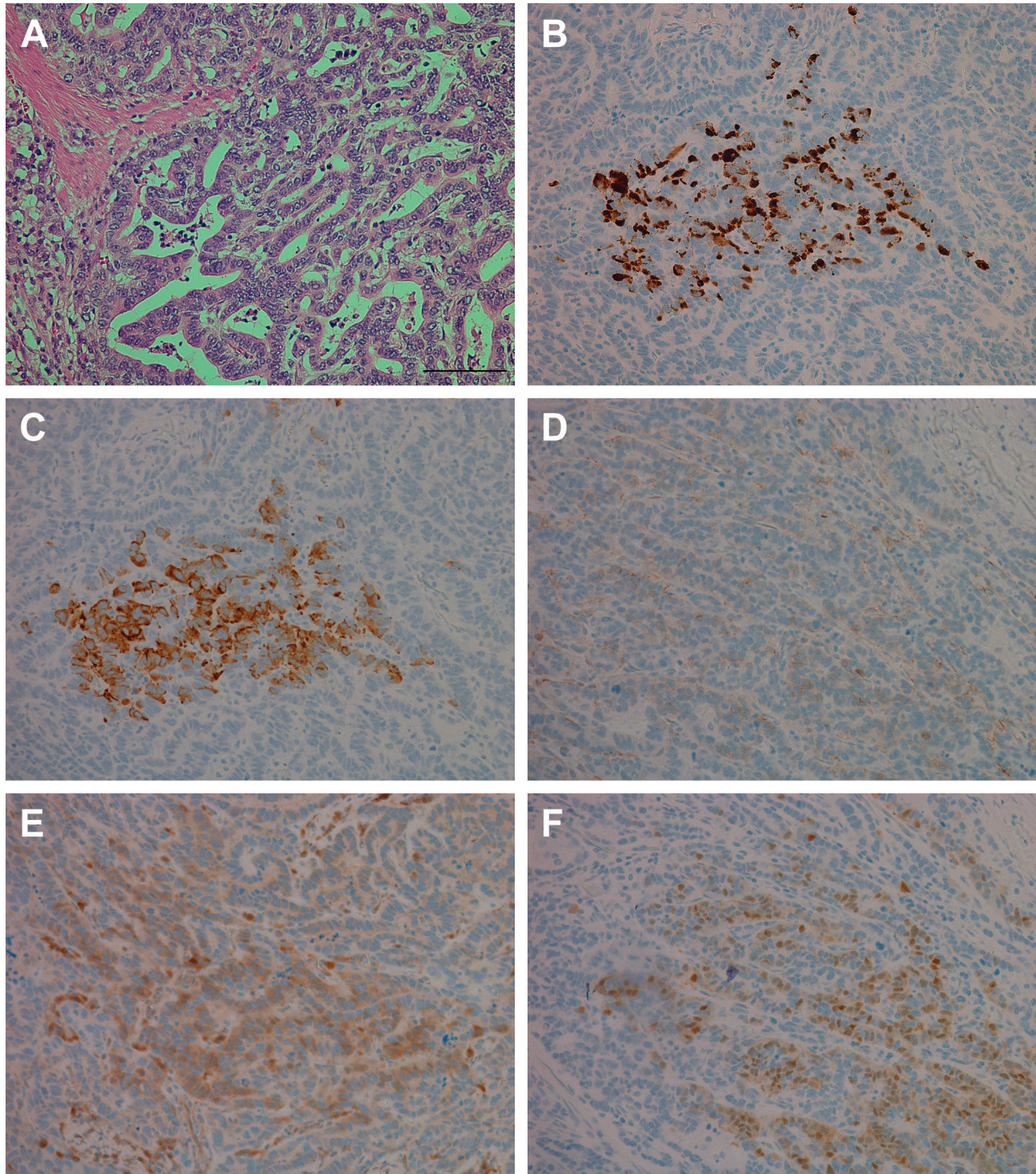
**Figure 2.** Lung with small cell lung carcinoma illustrated by (A) hematoxylin, eosin, and saffron (HES); (B) chromogranin A; (C) synaptophysin; (D) CD56; (E) neuron-specific enolase (NSE); and (F) Secretagogin. Scale bar = 100  $\mu$ m.

ChRCC. The mean tumor size registered in the pathology report was 3.7 (range: 1.2–10.0) cm with SD 2.2. Of the 45 kidney tumors, 38 (84%) were in the T1 category, 4 (9%) T2, 1 (2%) T3, and 2 (4%) T4.

#### *Immunohistochemistry*

All 178 tumors were examined using antibodies against CgA, synaptophysin, CD56, NSE, and Secretagogin.





**Figure 3.** Adenocarcinoma of intestinal type (according to Laurén) illustrated by (A) hematoxylin and eosin (HE), (B) chromogranin A, (C) synaptophysin, (D) CD56, (E) neuron-specific enolase (NSE), and (F) Secretagogin. Scale bar = 100  $\mu$ m.

The staining of CgA was granular and cytoplasmic, and the staining intensity mainly strong. When positive, synaptophysin was expressed in the cytoplasm, and the staining intensity of this marker was strong in

the NENs and weaker in the carcinomas. CD56 was expressed mainly on the cell membrane. The staining of secretagogin was cytoplasmic and nuclear, but otherwise similar to that of synaptophysin. NSE was



expressed in the cytoplasm when positive, and the staining intensity varied from strong to weak. The strongest staining was observed in NENs and CCRCC. When looking at the group as a whole, 48 (27%) expressed synaptophysin, 32 (18%) CgA, 46 (26%) CD56, 77 (43%) secretagogin, and 138 (78%) expressed NSE. Of the tumors positive for NSE, 95 (68%) expressed one or more additional NE markers. Which markers expressed in addition to NSE depended on the organ in question and tumor type. As seen for the breast and kidney, secretagogin was the marker most commonly co-expressed with NSE, whereas for the lung and stomach, this was not the case. (A summary of results are seen in Tables 1–3.)

*Breast.* Four (11%) of the tumors expressed synaptophysin, where two (5%) cases expressed the marker in 10–40% of tumor cells, and two (5%) cases in more than 70% of tumor cells. Three (8%) expressed CD56, where one (3%) case expressed this marker in 10–40% of tumor cells, whereas the other two (5%) in 40–70% of tumor cells. NSE was expressed in 19 (51%) cases, where 6 (16%) cases expressed this marker in 2–10% of tumor cells, 4 (11%) in 10–40%, 5 (14%) in 40–70%, and 4 (11%) in more than 70% of tumor cells. Secretagogin expression was noted in 10 (27%) cases, where 6 (16%) cases expressed this marker in 10–40% of tumor cells, 2 (5%) in 40–70%, and 2 (5%) in more than 70% of tumor cells. None (0%) of the cases expressed CgA. Out of all 19 cases expressing NSE, 11 (58%) cases expressed one or more additional NE markers. Of the 18 (49%) cases negative for NSE, 1 (5%) case (invasive carcinoma of no special type) expressed one additional NE marker, secretagogin, in approximately 20% of tumor cells and the staining intensity was mostly weak. In addition, the same tumor expressed NSE in a few scattered cells, but this amounted to less than 2% of tumor cells, and was therefore considered negative.

*Lung.* Of the lung cancers, 26 (38%) tumors expressed synaptophysin, where 3 (4%) cases expressed the marker in 2–10% of tumor cells, 3 (4%) in 10–40%, 3 (4%) in 40–70%, and 17 (25%) in more than 70% of tumor cells. CgA was positive in 17 (25%) of lung tumors, and the distribution was as follows; 2 (3%) expressed this marker in 2–10% of tumor cells, 2 (3%) in 10–40%, 2 (3%) in 40–70%, and 11 (16%) in more than 70% of tumors. In all, 25 (36%) cases expressed CD56, of which 6 (9%) expressed this marker in 2–10% of tumor cells, 2 (3%) in 10–40%, 3 (4%) in 40–70%, and 14 (20%) in more than 70% of tumor cells. A total of 59 (86%) expressed NSE, where 15 (22%) cases expressed this marker in 2–10% of tumor

cells, 10 (15%) in 10–40%, 12 (17%) in 40–70%, and 22 (32%) in more than 70% of tumor cells. Secretagogin was expressed in 18 (26%) cases, where 3 (4%) cases expressed this marker in 2–10% of tumor cells, 3 (4%) in 40–70%, and the remaining 12 (17%) in more than 70% of tumor cells. Of the 59 NSE-expressing cases, 33 (56%) expressed one or more additional NE markers. The 10 NSE-negative cases were also negative for other NE markers.

*Stomach.* A total of 16 (59%) of the tumors in the stomach expressed synaptophysin, where in 2 (7%) of the cases, the marker was expressed in 2–10% of tumor cells, 4 (15%) in 10–40%, 2 (7%) in 40–70%, and 8 (30%) cases in more than 70% of tumor cells. CgA was expressed in 15 (56%) cases, where in 1 (4%) case, positivity was observed in 2–10% of tumor cells, 7 (26%) in 10–40%, 2 (7%) in 40–70%, and 5 (19%) in more than 70% of tumor cells. In all, 12 (44%) cases expressed CD56, where 4 (15%) cases expressed this marker in 2–10% of tumor cells, 1 (4%) in 10–40%, 2 (7%) in 40–70%, and 5 (19%) in more than 70% of tumor cells. NSE was expressed in 20 (74%) cases, where 5 (19%) cases expressed this marker in 2–10% of tumor cells, 7 (35%) in 10–40%, 3 (11%) in 40–70%, and 5 (19%) in more than 70% of tumor cells. Secretagogin expression was found in 13 (48%) cases, where 1 (4%) case expressed this marker in 2–10% of tumor cells, 4 (15%) in 10–40%, 1 (4%) in 40–70%, and 7 (35%) in more than 70% of tumor cells. Out of all the 20 NSE-expressing cases, 15 (75%) cases expressed one or more additional NE markers. Of the seven NSE-negative cases, one (14%) tumor (adenocarcinoma of intestinal type) expressed synaptophysin in 10–40% of the tumor cells. A couple of NSE positive cells were observed, but this amounted to less than 1%.

*Kidney.* Of the 45 kidney tumors examined, two (4%) cases expressed synaptophysin. In one (2%) case, this expression was seen in 2–10% of tumor cells, and in one (2%) in 10–40% of tumor cells. Six (13%) expressed CD56, where three (7%) cases expressed this marker in 2–10% of tumor cells, one (2%) in 10–40%, one (2%) in 40–70%, and one (2%) in more than 70% of tumor cells. NSE expression was observed in 40 cases (89%), where 7 (16%) cases expressed this marker in 2–10% of tumor cells, 4 (9%) in 40–70%, and 29 (64%) in more than 70% of tumor cells. In CCRCC, the staining intensity was strong and the number of positive cells high. Of the few papRCC expressing NSE, the staining intensity was weak, and the location of expression was mainly in cells located toward cystic lumens, and in a diagnostic setting, the result would be considered negative. Secretagogin



**Table 1.** The Number of Tumors Positive and Negative for NE Markers Associated With Each of the Histological Subtypes.

Histological Subtype	Synaptophysin		CgA		CD56		NSE		Secretogin	
	Positive	Negative	Positive	Negative	Positive	Negative	Positive	Negative	Positive	Negative
	n (%)	n (%)	n (%)	n (%)	n (%)	n (%)	n (%)	n (%)	n (%)	n (%)
<b>Breast</b>										
Invasive carcinoma NST (n=21)	2 (10%)	19 (90%)	0 (0%)	21 (100%)	2 (10%)	19 (90%)	13 (62%)	8 (38%)	5 (24%)	16 (76%)
Invasive lobular carcinoma (n=13)	1 (8%)	12 (92%)	0 (0%)	13 (100%)	1 (8%)	12 (92%)	5 (38%)	8 (62%)	4 (31%)	9 (69%)
Medullary carcinoma (n=2)	0 (0%)	2 (100%)	0 (0%)	2 (100%)	0 (0%)	2 (100%)	0 (0%)	2 (100%)	0 (0%)	2 (100%)
Carcinoma with NE features (n=1)	1 (100%)	0 (0%)	0 (0%)	1 (100%)	0 (0%)	1 (100%)	1 (100%)	0 (0%)	1 (100%)	0 (0%)
All breast tumors (n=37)	4 (11%)	33 (89%)	0 (0%)	37 (100%)	3 (8%)	34 (92%)	19 (51%)	18 (49%)	10 (27%)	27 (73%)
<b>Lung</b>										
Squamous cell carcinoma (n=22)	0 (0%)	22 (100%)	0 (0%)	22 (100%)	3 (14%)	19 (86%)	18 (82%)	4 (18%)	0 (0%)	22 (100%)
Adenocarcinoma (n=23)	6 (26%)	17 (74%)	1 (4%)	22 (96%)	5 (22%)	18 (78%)	19 (83%)	4 (17%)	1 (4%)	22 (96%)
Large cell carcinoma (n=3)	1 (33%)	2 (67%)	0 (0%)	3 (100%)	0 (0%)	3 (100%)	2 (67%)	1 (33%)	0 (0%)	3 (100%)
Large cell NE carcinoma (n=4)	3 (75%)	1 (25%)	1 (25%)	3 (75%)	3 (75%)	1 (25%)	4 (100%)	0 (0%)	1 (25%)	3 (75%)
Small cell lung carcinoma (n=7)	7 (100%)	0 (0%)	6 (86%)	1 (14%)	7 (100%)	0 (0%)	7 (100%)	0 (0%)	7 (100%)	0 (0%)
Carcinoid tumor, typical and atypical (n=9)	9 (100%)	0 (0%)	9 (100%)	0 (0%)	7 (78%)	2 (22%)	9 (100%)	0 (0%)	9 (100%)	0 (0%)
Metastasis (adenocarcinoma) (n=1)	0 (0%)	1 (100%)	0 (0%)	1 (100%)	0 (0%)	1 (100%)	0 (0%)	1 (100%)	0 (0%)	1 (100%)
All lung tumors (n=69)	26 (38%)	43 (62%)	17 (25%)	52 (75%)	25 (36%)	44 (64%)	59 (86%)	10 (14%)	18 (26%)	51 (74%)
<b>Stomach</b>										
Adenocarcinoma, intestinal type (n=10)	3 (30%)	7 (70%)	2 (20%)	8 (80%)	2 (20%)	8 (80%)	5 (50%)	5 (50%)	1 (10%)	9 (90%)
Adenocarcinoma, diffuse type (n=7)	3 (43%)	4 (57%)	3 (43%)	4 (57%)	0 (0%)	7 (100%)	5 (71%)	2 (29%)	2 (29%)	5 (71%)
Adenocarcinoma, mixed or indeterminate type (n=2)	2 (100%)	0 (0%)	2 (100%)	0 (0%)	2 (100%)	0 (0%)	2 (100%)	0 (0%)	2 (100%)	0 (0%)
Neuroendocrine neoplasm (n=8)	8 (100%)	0 (0%)	8 (100%)	0 (0%)	8 (100%)	0 (0%)	8 (100%)	0 (0%)	8 (100%)	0 (0%)
All stomach tumors (n=27)	16 (59%)	11 (41%)	15 (56%)	12 (44%)	12 (44%)	15 (56%)	20 (74%)	7 (26%)	13 (48%)	14 (52%)
<b>Kidney</b>										
Clear cell renal cell carcinoma (n=34)	2 (6%)	32 (94%)	0 (0%)	34 (100%)	6 (18%)	28 (82%)	33 (97%)	1 (3%)	30 (88%)	4 (12%)
Papillary renal cell carcinoma type 1 (n=7)	0 (0%)	7 (100%)	0 (0%)	7 (100%)	0 (0%)	7 (100%)	5 <sup>a</sup> (71%)	2 (29%)	4 <sup>a</sup> (57%)	3 (43%)
Papillary renal cell carcinoma type 2 (n=2)	0 (0%)	2 (100%)	0 (0%)	2 (100%)	0 (0%)	2 (100%)	2 <sup>a</sup> (100%)	0 (0%)	2 <sup>a</sup> (100%)	0 (0%)
Chromophobe renal cell carcinoma (n=2)	0 (0%)	2 (100%)	0 (0%)	2 (100%)	0 (0%)	2 (100%)	0 (0%)	2 (100%)	0 (0%)	2 (100%)
All kidney tumors (n=45)	2 (4%)	43 (96%)	0 (0%)	45 (100%)	6 (13%)	39 (87%)	40 (89%)	5 (11%)	36 (80%)	9 (20%)
All tumors (n=178)	48 (27%)	130 (73%)	32 (18%)	146 (82%)	46 (26%)	132 (74%)	138 (78%)	40 (22%)	77 (43%)	101 (57%)

<sup>a</sup>Weak expression of NSE and secretogin was observed in a few cells next to cystic lumens of papillary renal cell carcinomas, and may represent artifacts and not positive staining in these cases. Abbreviations: CgA, chromogranin A; NSE, neuron-specific enolase; NE, neuroendocrine; NST, no special type.

**Table 2.** The Association of Histological Subtype and Number of NE Markers Expressed in Each of the Subtypes.

Histological Subtype	Number of Positive NE Markers					
	0 Positive NE Markers	1 Positive NE Marker	2 Positive NE Markers	3 Positive NE Markers	4 Positive NE Markers	5 Positive NE Markers
<b>Breast</b>						
Invasive carcinoma NST (n=21)	7 (33%)	8 (38%)	4 (19%)	2 (10%)	0 (0%)	0 (0%)
Invasive lobular carcinoma (n=13)	8 (62%)	1 (8%)	2 (15%)	2 (15%)	0 (0%)	0 (0%)
Medullary carcinoma (n=2)	2 (100%)	0 (0%)	0 (0%)	0 (0%)	0 (0%)	0 (0%)
Carcinoma with NE features (n=1)	0 (0%)	0 (0%)	0 (0%)	1 (100%)	0 (0%)	0 (0%)
All breast tumors (n=37)	17 (46%)	9 (24%)	6 (16%)	5 (14%)	0 (0%)	0 (0%)
<b>Lung</b>						
Squamous cell carcinoma (n=22)	4 (18%)	15 (68%)	3 (14%)	0 (0%)	0 (0%)	0 (0%)
Adenocarcinoma (n=23)	4 (17%)	10 (43%)	7 (30%)	1 (4%)	0 (0%)	1 (4%)
Large cell carcinoma (n=3)	1 (33%)	1 (33%)	1 (33%)	0 (0%)	0 (0%)	0 (0%)
Large cell NE carcinoma (n=4)	0 (0%)	0 (0%)	2 (50%)	0 (0%)	2 (50%)	0 (0%)
Small cell lung carcinoma (n=7)	0 (0%)	0 (0%)	0 (0%)	0 (0%)	1 (14%)	6 (86%)
Carcinoid tumor, typical and atypical (n=9)	0 (0%)	0 (0%)	0 (0%)	0 (0%)	2 (22%)	7 (78%)
Metastasis (adenocarcinoma) (n=1)	1 (100%)	0 (0%)	0 (0%)	0 (0%)	0 (0%)	0 (0%)
All lung tumors (n=69)	10 (14%)	26 (38%)	13 (19%)	1 (1%)	5 (7%)	14 (20%)
<b>Stomach</b>						
Adenocarcinoma, intestinal type (n=11)	4 (36%)	4 (36%)	0 (0%)	0 (0%)	2 (18%)	1 (9%)
Adenocarcinoma, diffuse type (n=6)	2 (33%)	2 (33%)	0 (0%)	1 (17%)	1 (17%)	0 (0%)
Adenocarcinoma, mixed or indeterminate type (n=2)	0 (0%)	0 (0%)	0 (0%)	0 (0%)	0 (0%)	2 (100%)
Neuroendocrine neoplasm (n=8)	0 (0%)	0 (0%)	0 (0%)	0 (0%)	0 (0%)	8 (100%)
All stomach tumors (n=27)	6 (22%)	6 (22%)	0 (0%)	1 (4%)	3 (11%)	11 (41%)
<b>Kidney</b>						
Clear cell renal cell carcinoma (n=34)	0 (0%)	3 (9%)	25 (74%)	6 (18%)	0 (0%)	0 (0%)
Papillary renal cell carcinoma type 1 (n=7)	1 (14%)	3 (43%)	3 (43%)	0 (0%)	0 (0%)	0 (0%)
Papillary renal cell carcinoma type 2 (n=2)	0 (0%)	0 (0%)	2 (100%)	0 (0%)	0 (0%)	0 (0%)
Chromophobe renal cell carcinoma (n=2)	2 (100%)	0 (0%)	0 (0%)	0 (0%)	0 (0%)	0 (0%)
All kidney tumors (n=45)	3 (7%)	6 (13%)	30 (67%)	6 (13%)	0 (0%)	0 (0%)
All tumors (n=178)	36 (20%)	47 (26%)	49 (28%)	13 (7%)	8 (4%)	25 (14%)

Abbreviations: NE, neuroendocrine; NST, no special type.

was positive in 36 (80%) cases, where 10 (22%) cases expressed this marker in 2–10% of tumor cells, 10 (22%) in 10–40%, 10 (22%) in 40–70%, and 6 (13%) cases in more than 70% of tumor cells. In the surrounding normal kidney, a few secretagogin positive cells were observed in the vascular pole of the Bowman's capsule and in a few tubular cells. CgA expression was not observed in any of the cases (0%). Of all the NSE-expressing cases, 38 (84%) expressed one or more additional NE markers, where secretagogin was the marker most commonly expressed in addition to NSE. Of the five (11%) cases negative for NSE, one of the cases expressed an additional NE marker, secretagogin, which was observed in approximately 10% of its tumor cells, mainly toward cystic areas in the tumor. When reexamining the expression of NSE in the same tumor, small areas amounting to less than 2% displayed weak staining. Interestingly, the

expression of CD56 and synaptophysin was only observed in CCRCC. The staining intensity of secretagogin was stronger for CCRCC compared with non-CCRCC. In addition, the number of cells with positive staining for secretagogin was notably higher in CCRCC compared with non-CCRCC.

### Correlations

When considering all 178 cases, a significant association was observed between NSE and secretagogin ( $r = 0.6$ ,  $p < 0.001$ ), CD56 and CgA ( $r = 0.7$ ,  $p < 0.001$ ), CD56 and synaptophysin ( $r = 0.6$ ,  $p < 0.001$ ), synaptophysin and CgA ( $r = 0.8$ ,  $p < 0.001$ ), secretagogin and CgA ( $r = 0.6$ ,  $p < 0.001$ ), and secretagogin and synaptophysin ( $r = 0.5$ ,  $p < 0.001$ ). There was also a significant association between the number of NE markers expressed in each of the tumors and the number of

**Table 3.** Illustrating the Number of Positive Cells for Each Marker in the Various Organs Examined (where 0 < 2% positive cells, 1 = 2–10% positive tumor cells, 2 = 10–40% positive tumor cells, 3 = 40–70% positive tumor cells, and 4 > 70% positive tumor cells).

No Positive Cells	0	1	2	3	4	Total (n)
Organ						
Marker						
Breast						
CgA	37	0	0	0	0	37
Synaptophysin	33	0	2	0	2	37
CD56	34	0	1	2	0	37
NSE	18	6	4	5	4	37
Secretagogin	27	0	6	2	2	37
Lung						
CgA	52	2	2	2	11	69
Synaptophysin	43	3	3	3	17	69
CD56	44	6	2	3	14	69
NSE	10	15	10	12	22	69
Secretagogin	51	3	0	3	12	69
Stomach						
CgA	12	1	7	2	5	27
Synaptophysin	11	2	4	2	8	27
CD56	15	4	1	2	5	27
NSE	7	5	7	3	5	27
Secretagogin	14	1	4	1	7	27
Kidney						
CgA	45	0	0	0	0	45
Synaptophysin	43	1	1	0	0	45
CD56	39	3	1	1	1	45
NSE	5	6	1	4	29	45
Secretagogin	9	10	10	10	6	45

Abbreviations: CgA, chromogranin A; NSE, neuron-specific enolase.

cells expressing NSE ( $r = 0.7$ ,  $p < 0.001$ ), CD56 ( $r = 0.7$ ,  $p < 0.001$ ), secretagogin ( $r = 0.8$ ,  $p < 0.001$ ), CgA ( $r = 0.7$ ,  $p < 0.001$ ), and synaptophysin ( $r = 0.7$ ,  $p < 0.001$ ). Tables 4 to 8 illustrate the correlations between the different markers in the group as a whole, and in the various organs.

## Discussion

In our study, we identified NSE expression in a large proportion (78%) of tumors examined. The staining intensity and number of tumor cells expressing NSE was highest among tumors of NE origin, including carcinoma with NE features (breast), carcinoid tumor (lung), SCLC (lung), large cell NE carcinoma (lung), and NENs (stomach). NSE expression was also strong among CCRCC (kidney), and all these tumors expressed NSE to some degree. A total of 95 (68%) of the NSE positive tumors also expressed at least

one additional NE marker. The number of additional NE markers was highest for the tumors of NE origin, and an association between the number of NE markers that were positive in each tumor and the number of cells staining positive for the various markers was also found, both when looking at all the cases together and for the various locations. Furthermore, a strong association was found between expressions of the different NE markers. In particular, the association between the expression of secretagogin and number of NE markers expressed was strong, which could be due to the high number of CCRCC expressing both NSE and secretagogin. When dividing the cases according to location, there was a moderate and strong association between the expressions of all the NE markers, but in particular, the association between secretagogin and CgA was strong. The same was noted for the stomach, whereas for tumors located to kidney or breast, this was not the case, and only a moderate association between secretagogin and NSE was noted.

Three NSE-negative tumors (case numbers 12, 154, and 178 in the supplementary table), were found to express one other NE marker. One case from the breast (carcinoma of no special type) expressed secretagogin in about 20% of tumor cells. This staining was, however, mostly weak. When reexamining the section stained with NSE, a few positive cells were observed, but this amounted to less than 2%, and, as a result, NSE was in this case considered negative. The same situation was observed in one tumor located in the kidney, PRCC type 1. In this case, however, the staining intensity was weak and mainly located toward cystic lumens in the tumor, and could be interpreted as nonspecific staining of secretagogin. The third NSE-negative case expressing an additional marker was found in the stomach, and was adenocarcinoma of intestinal type. Synaptophysin, which is considered to be one of the more reliable markers of NE differentiation, was observed in approximately 20% of tumor cells. A couple of NSE-expressing cells were observed in this case as well, but like the previous-mentioned cases, the number of NSE-expressing cells was low, amounting to less than 1%. Importantly, of all the cases with morphology consistent with NE differentiation, NSE expression was observed. This finding was also verified with the more accepted NE markers like CgA and synaptophysin. In some cases, the interpretation of NSE was challenging due to NSE expression in surrounding smooth muscle cells and some fibroblast-like stromal cells. Lobular carcinoma of the breast and adenocarcinoma of the diffuse type in the stomach were the most difficult to evaluate due to diffuse growth of the tumor cells intermixed with NSE positive

**Table 4.** Spearman's Correlation Coefficients for NE Markers and Number of NE Markers for All Tumors.

Correlations	NSE	CD56	Secretagogen	CgA	Synaptophysin	Number of NE Markers
NSE	I	0.346 ( <i>p</i> <0.001)	0.614 ( <i>p</i> <0.001)	0.319 ( <i>p</i> <0.001)	0.360 ( <i>p</i> <0.001)	0.745 ( <i>p</i> <0.001)
CD56		I	0.453 ( <i>p</i> <0.001)	0.672 ( <i>p</i> <0.001)	0.599 ( <i>p</i> <0.001)	0.675 ( <i>p</i> <0.001)
Secretagogen			I	0.551 ( <i>p</i> <0.001)	0.498 ( <i>p</i> <0.001)	0.802 ( <i>p</i> <0.001)
CgA				I	0.815 ( <i>p</i> <0.001)	0.663 ( <i>p</i> <0.001)
Synaptophysin					I	0.678 ( <i>p</i> <0.001)
Number of NE markers						I

Abbreviations: NE, neuroendocrine; NSE, neuron-specific enolase; CgA, chromogranin A.

**Table 5.** Spearman's Correlation Coefficients for NE Markers and Number of NE Markers for Tumors Located to the Breast.

Correlations	NSE	CD56	Secretagogen	CgA	Synaptophysin	Number of NE Markers
NSE	I	0.267 ( <i>p</i> =0.110)	0.493 ( <i>p</i> =0.002)	—	0.463 ( <i>p</i> =0.004)	0.876 ( <i>p</i> <0.001)
CD56		I	0.258 ( <i>p</i> =0.124)	—	-0.103 ( <i>p</i> =0.543)	0.418 ( <i>p</i> =0.010)
Secretagogen			I	—	0.361 ( <i>p</i> =0.028)	0.750 ( <i>p</i> <0.001)
CgA				—	—	—
Synaptophysin					I	0.509 ( <i>p</i> =0.001)
Number of NE markers						I

Abbreviations: NE, neuroendocrine; NSE, neuron-specific enolase; CgA, chromogranin A.

**Table 6.** Spearman's Correlation Coefficients for NE Markers and Number of NE Markers for Tumors Located to the Lung.

Correlations	NSE	CD56	Secretagogen	CgA	Synaptophysin	Number of NE Markers
NSE	I	0.401 ( <i>p</i> =0.001)	0.583 ( <i>p</i> <0.001)	0.543 ( <i>p</i> <0.001)	0.551 ( <i>p</i> <0.001)	0.601 ( <i>p</i> <0.001)
CD56		I	0.728 ( <i>p</i> <0.001)	0.688 ( <i>p</i> <0.001)	0.683 ( <i>p</i> <0.001)	0.823 ( <i>p</i> <0.001)
Secretagogen			I	0.919 ( <i>p</i> <0.001)	0.847 ( <i>p</i> <0.001)	0.781 ( <i>p</i> <0.001)
CgA				I	0.833 ( <i>p</i> <0.001)	0.763 ( <i>p</i> <0.001)
Synaptophysin					I	0.859 ( <i>p</i> <0.001)
Number NE markers						I

Abbreviations: NE, neuroendocrine; NSE, neuron-specific enolase; CgA, chromogranin A.

stromal cells consisting mainly of smooth muscle cells, lymphocytes, and fibroblast-like cells.

CgA and synaptophysin were expressed in 32 (18%) and 48 (27%) of all tumors, respectively. Of

note, all tumors positive for CgA also expressed NSE. In the case of synaptophysin, however, one of the tumors (adenocarcinoma of intestinal type from the stomach) expressing synaptophysin was negative for



**Table 7.** Spearman's Correlation Coefficients for NE Markers and Number of NE Markers for Tumors Located to the Stomach.

Correlations	NSE	CD56	Secretagogen	CgA	Synaptophysin	Number of NE Markers
NSE	1	0.865 ( <i>p</i> <0.001)	0.828 ( <i>p</i> <0.001)	0.851 ( <i>p</i> <0.001)	0.837 ( <i>p</i> <0.001)	0.876 ( <i>p</i> <0.001)
CD56		1	0.888 ( <i>p</i> <0.001)	0.878 ( <i>p</i> <0.001)	0.894 ( <i>p</i> <0.001)	0.869 ( <i>p</i> <0.001)
Secretagogen			1	0.909 ( <i>p</i> <0.001)	0.842 ( <i>p</i> <0.001)	0.894 ( <i>p</i> <0.001)
CgA				1	0.924 ( <i>p</i> <0.001)	0.905 ( <i>p</i> <0.001)
Synaptophysin					1	0.882 ( <i>p</i> <0.001)
Number of NE markers						1

Abbreviations: NE, neuroendocrine; NSE, neuron-specific enolase; CgA, chromogranin A.

**Table 8.** Spearman's Correlation Coefficients for NE Markers and Number of NE Markers for All Tumors Located to the Kidney.

Correlations	NSE	CD56	Secretagogen	CgA	Synaptophysin	Number of NE Markers
NSE	1	0.192 ( <i>p</i> =0.207)	0.531 ( <i>p</i> <0.001)	—	0.156 ( <i>p</i> =0.307)	0.781 ( <i>p</i> <0.001)
CD56		1	-0.038 ( <i>p</i> =0.804)	—	-0.084 ( <i>p</i> =0.582)	0.586 ( <i>p</i> <0.001)
Secretagogen			1	—	0.265 ( <i>p</i> =0.079)	0.503 ( <i>p</i> <0.001)
CgA				—	—	—
Synaptophysin					1	0.212 ( <i>p</i> =0.162)
Number of NE markers						1

Abbreviations: NE, neuroendocrine; NSE, neuron-specific enolase; CgA, chromogranin A.

NSE. The reason for this is unknown. CgA and synaptophysin are two broad-spectrum markers commonly used in the diagnosis of NENs. CgA, which is a part of the granin family, is composed of acidic proteins found in the secretory granules of NE cells and tumors of known NE origin. The main issue with CgA as a marker of NE differentiation is that granins are primarily located in large secretory granules in the cytoplasm. As NE tumors dedifferentiate, there is a loss of neurosecretory granules, and as a result, poorly differentiated tumors may be completely negative for this marker. This certainly seems to be the case for some of the SCLCs and Merkel cell carcinomas of the skin.<sup>29</sup> Even so, CgA is considered to be one of the most specific markers of NE differentiation. As seen in the supplementary table, all cases expressing CgA also expressed additional NE markers supporting the above. Synaptophysin, another reputable NE marker, is found in the synaptic vesicles as a 38 kDA transmembrane glycoprotein. Synaptophysin has a slightly different staining profile compared with that of CgA

due to the difference between the vesicles and secretory granules of granins and may be positive in less-differentiated NE tumors.

In contrast to CgA and synaptophysin, NSE is localized in the cytosol of the cells rather than in neurosecretory granules and vesicles. As a consequence, NSE is able to stain even dedifferentiated and degranulated NE tumors. Even though this marker is considered sensitive for NE differentiation, its specificity is considered low due to cross-reactivity with smooth muscle cells, myoepithelial cells, and lymphocytes. In our study, this cross-reactivity made it more difficult to interpret NSE positivity seen in adenocarcinomas of the diffuse type in the stomach and invasive lobular carcinoma of the breast. These tumors have a more diffuse growth pattern compared with the other subtypes in the same organs, and subsequently recognizing tumor cells from NSE positive surrounding stromal cells was challenging. Many arguments go against NSE as a specific marker. In a study by Haimoto et al., NSE expression was found in the epithelial cells of the

loop of Henle.<sup>30</sup> In addition, NSE is expressed in a number of RCCs, in particular, CCRCCs. CCRCC is presently not considered to be of NE origin. In recent studies, however, the expression of both erythropoietin (a hormone) and NSE has been found in the majority of CCRCCs,<sup>20,31</sup> and a proportion of the CCRCC also expressed synaptophysin and CD56. As a result, one may question the nonendocrine nature of these tumors.<sup>10,11</sup> In another study by Abbona et al., where they investigated the expression of NE markers in NSCLC, they found that 21/40 (53%) tumors expressed NSE, 4/40 (10%) expressed synaptophysin, and 5/40 (13%) expressed CgA.<sup>32</sup> All the tumors expressing synaptophysin were also positive for NSE. The finding of NE markers in NSCLC is supported by another study done at our department.<sup>14</sup>

In our study, 77 (43%) of all cases expressed secretagogin, which is twice the amount when compared with CgA and synaptophysin. This is partly due to the high number of RCCs expressing this marker. Even so, the association between the expression of secretagogin and CgA was comparable with that of synaptophysin and CgA, at least for tumors located to lung and stomach. In some cases (as illustrated by Fig. 2), it may even be a better choice than synaptophysin. Secretagogin is a marker considered by some to be of value in diagnosis of NENs and NE differentiation in tumors,<sup>18,19</sup> but is not, however, in use in routine diagnosis of NENs. Secretagogin, which is a hexa EF-hand calcium-binding protein, was first cloned from the pancreas, and is considered to be specific for pancreatic beta cells and NE cells.<sup>33</sup> The physiology of secretagogin is poorly understood but in the islets of Langerhans, the beta cells are thought to deliver insulin-packed granules in a calcium-dependent fashion in response to elevated glucose levels. This marker is also implicated in calcium dependent- and growth regulatory processes, and Adolf et al. found that secretagogin is co-localized with other accepted markers like CgA, synaptophysin, and NSE, but in different subcellular compartments.<sup>19</sup> Interestingly, secretagogin is found in a number of RCCs.<sup>34</sup> Ilhan et al. discovered that 37% of CCRCCs expressed secretagogin, whereas non-CCRCCs were completely negative. They also found more metastasis in the subgroup of CCRCCs positive to secretagogin compared with the secretagogin negative subgroup. In the present study, we found that 30 out of 34 (88%) CCRCCs were positive for secretagogin, which is substantially higher than in the study by Ilhan and coworkers. This discrepancy could be due to methodological issues such as preanalytical factors like fixation time and/or primary and secondary antibodies used. In our study, we used mouse link to enhance the signal, which could further increase the number of positive tumors in our study.

Many pathologists are skeptical to the use of NSE in the diagnostic setting, especially for the diagnosis of NE differentiation in tumors. Studies have shown NSE to be expressed in tumors not believed to be derived from NE cells, and this has led to the term “nonspecific” enolase. Various studies concluding that NSE is a nonspecific marker for determining NE differentiation are based on the presence of NSE in epithelial cells in the loop of Henle,<sup>6</sup> and carcinomas of the ovaries and breast.<sup>35</sup> Since the time these studies were conducted, NE differentiation in carcinomas of the breast and ovaries have been described.<sup>24,36</sup> Another reason for concluding that NSE is nonspecific is the finding of NSE in a number of RCCs, especially CCRCC. In a recent study, we found almost all CCRCCs to express NSE, and the same tumors also expressed the hormone erythropoietin normally produced by the kidneys.<sup>20</sup> A number of tumors which in the past have been considered not to be of NE origin have, with improved antibodies and detection systems, displayed NE differentiation within the tumor tissue.<sup>37</sup> Interestingly, the carcinomas of the stomach with focal NSE expression also expressed one or more other NE markers in the same areas, thus supporting the finding of NE differentiation in these tumors. This was also observed in carcinomas originating from other locations. NE differentiation in adenocarcinomas of various organs including the prostate, breast, stomach, lung, and colorectum have been described, and the relevance of this finding seems to vary from organ to organ.<sup>32,38–41</sup> Thus, reporting the presence of NE differentiation in other tumor types like, for instance, adenocarcinomas may be of interest to learn more about the significance of this finding. Till now, the diagnosis of NENs has been based on characteristic morphological features together with positive reaction for accepted NE markers like synaptophysin and CgA. This works well for well-differentiated NENs that are typically composed of uniform cells with coarse chromatin arranged in islands, trabecular, or glandular structures. Poorly differentiated NENs, in contrast, are more difficult to classify due to lack of typical NE pattern and with diffuse necrosis, marked cellular atypia, and high number of mitosis. In addition, poorly differentiated NENs have low levels of neurosecretory granules in their cytoplasm, which in turn lead to a weak or negative reaction for the same markers, especially CgA. In our study, we observed that whenever CgA expression was seen, NSE was observed in the same areas. The number of NSE positive cells seemed to be higher than for other NE markers used. This was especially the case in the lungs, whereas a number of NSE positive cells were only slightly increased compared with CgA and synaptophysin in carcinomas of the stomach (illustrated in Figs. 1–3). In that respect, NSE expression

could be of value in confirming a suspicion of NE differentiation (either based on morphology or by some level of expression of another NE marker) in a tumor. Some authors therefore recommend that a panel of markers including CgA, synaptophysin, CD56, and NSE should be used for poorly differentiated NENs.<sup>42</sup> In the present study, we also noticed that the staining intensity for confirmed NENs and CCRCCs was strong. In addition, the number of cells positive for NSE in the same cases was high. Bearing this in mind, the staining intensity and number of positive cells could give us some indication whether we are dealing with a NEN. Furthermore, most tumors positive for the other NE markers were also positive for NSE, suggesting that NSE is a robust marker in tumors with proven NE differentiation. In total, 43 tumors expressed NSE without expressing other NE markers. The intensity of staining in these tumors was weak and as illustrated by Table 9, the number of positive cells was low in most of the cases. A weakness in this study, however, is the limited number of locations examined, especially when considering that NE cells are found in many different locations throughout the body.

Correct subtyping of tumors is of importance to give the best treatment possible to affected patients. The classification of tumors is traditionally based on morphological and immunohistochemical phenotype of the most differentiated area of the tumor. As tumors dedifferentiate, this classification may become increasingly challenging by the loss of expression of the various markers in the tumor cells, which in turn causes difficulties in recognizing the cell of origin. In cases of NE differentiation in poorly differentiated carcinomas, however, this finding has been explained by redifferentiation of the tumor, rather than the tumor originating from NE cells in the first place. Dedifferentiation, however, seldom leads to new properties, rather to loss of properties. Whereas there is an acceptance for NETs originating from normal NE cells due to stimulation of growth and through stages of hyperplasia, this is not the case for NECs. Stem cells are believed to be the origin of highly malignant tumors including NECs.<sup>43</sup> Cancer stem cells are thought to be a subpopulation of cells within a tumor with the ability to perpetuate indefinitely in contrast to the majority of cells found within the tumor. Even though cancer stem cells harbor properties of normal stem cells like the ability to self-renew and grow, they do not necessarily develop from normal-tissue stem cells. Research conducted on the brain has found that mature astrocytes have the ability to dedifferentiate under certain conditions and in turn gain stem cell-like qualities.<sup>44</sup> Studies have also revealed that NE cells have the ability to proliferate with the potential to develop into tumors of all degrees of malignancy.<sup>45</sup> There is a continuum of differentiation in tumors as demonstrated

**Table 9.** Illustrating the Expression of 43 NSE Positive Tumors Negative for Other NE Markers. (1 = 2–10% positive tumor cells, 2 = 10–40% positive tumor cells, 3 = 40–70% positive tumor cells, 4 > 70% positive tumor cells).

Organ	Expression of NSE				Total
	1	2	3	4	
Breast	4	1	2	1	8
Lung	5	8	7	6	26
Stomach	3	2	0	0	5
Kidney	2	0	1	1	4
Total	14	11	10	8	43

Abbreviations: NSE, neuron-specific enolase; NE, neuroendocrine.

by different expression of NE markers in these tumors; some NETs may express NE markers in almost all tumor cells, whereas NE markers are observed in a proportion of tumor cells in other NETs. NECs may even express NE markers in only a few scattered cells, and as a result, a clear cutoff value of number of positive NE cells to diagnose a tumor as NE may be difficult. Furthermore, well-differentiated NENs are usually easy to diagnose, NECs, on the contrary, are more challenging due to less recognizable morphology and reduced expression of NE markers in the tumor. Some small cell NECs may even be completely negative for NE markers; thus, using NSE and introducing secretagogin into routine diagnostics may be beneficial.

In conclusion, we found NSE to be expressed in 78% of tumors from the breast, lung, stomach, and kidney, and of the NSE-expressing cases, 68% expressed one or more additional NE markers. When keeping in mind NSE's ability to cross-react with other forms of enolases, this antibody may be useful in confirming the diagnosis of NENs or adenocarcinoma with NE differentiation. Due to the fact that NSE is a cytosolic marker, it may even give a better indication of how many cells are true NE cells, especially in cases where the tumor cells are dedifferentiated. The following questions are still in need of answers: Is the knowledge that NSE is expressed in a higher proportion of tumors compared with other NE markers an indication of NSE being a more sensitive marker of NE differentiation, or due to cross-reactivity with other forms of enolase? The fact that all tumors expressing the more accepted NE markers also are positive for NSE may suggest that this marker is more specific than previously realized. Secretagogin also seems promising in terms of determining NE differentiation and should be considered implemented in routine diagnosis of these tumors. Although secretagogin shows promising results, two of the kidney cancers expressing this marker did not express NSE. More research is needed to explore this further.

## Acknowledgments

We thank Bjørn Munkvold for technical assistance and Sissel Gyrid Freim Wahl for help in subclassification of lung tumors. In addition, we thank the National Registry for providing patient's data and the Department of Pathology at St. Olav's Hospital, Trondheim University Hospital, Norway, for supplying us with tissue from the archives.

## Competing Interests

The author(s) declared no potential conflicts of interest with respect to the research, authorship, and/or publication of this article.

## Author Contributions

PM made the tissue microarray (TMA) blocks, evaluated the hematoxylin and eosin (HE) and hematoxylin, eosin, and saffron (HES) stained sections, as well as performing and evaluating the immunohistochemical staining. Statistical analysis was done by PM and LS. HLW and PM designed the study. ISN, HLW, LS, and PM were involved in patient collection for the study, and ISN was consulted with regard to some of the sections. All authors revised and approved the final manuscript.

## Ethical Considerations

The study and permission to use the tissue for research were approved by the Regional Committee for Medical and Health Sciences Research Ethics (reference number in REK: 2016/838). For this study, no formal consent was required.

## Funding

The author(s) disclosed receipt of the following financial support for the research, authorship, and/or publication of this article: This work was funded by the Liaison Committee between the Central Norway Regional Health Authority and the Norwegian University of Science and Technology (project number 46056838).

## Literature Cited

- Delle Fave G, O'Toole D, Sundin A, Taal B, Ferolla P, Ramage JK, Ferone D, Ito T, Weber W, Zheng-Pei Z, De Herder WW, Pascher A, Ruzniewski P. Vienna Consensus Conference participants. ENETS consensus guidelines update for gastroduodenal neuroendocrine neoplasms. *Neuroendocrinology*. 2016;103(2):119–24. doi:10.1159/000443168.
- Gould VE, Wiedenmann B, Lee I, Schwechheimer K, Dockhorn-Dworniczak B, Radosevich JA, Moll R, Franke WW. Synaptophysin expression in neuroendocrine neoplasms as determined by immunocytochemistry. *Am J Pathol*. 1987;126(2):243–57.
- Wiedenmann B, Huttner WB. Synaptophysin and chromogranins/secretogranins—widespread constituents of distinct types of neuroendocrine vesicles and new tools in tumor diagnosis. *Virchows Arch B Cell Pathol Incl Mol Pathol*. 1989;58(2):95–121.
- Schmechel D, Marangos PJ, Brightman M. Neurone-specific enolase is a molecular marker for peripheral and central neuroendocrine cells. *Nature*. 1978;276(5690):834–6.
- Schmechel DE. Gamma-subunit of the glycolytic enzyme enolase: nonspecific or neuron specific? *Lab Invest*. 1985;52(3):239–42.
- Tapia FJ, Polak JM, Barbosa AJ, Bloom SR, Marangos PJ, Dermody C, Pearse AG. Neuron-specific enolase is produced by neuroendocrine tumours. *Lancet*. 1981;1(8224):808–11.
- Erickson LA, Lloyd RV. Practical markers used in the diagnosis of endocrine tumors. *Adv Anat Pathol*. 2004;11(4):175–89.
- Leader M, Collins M, Patel J, Henry K. Antineuron specific enolase staining reactions in sarcomas and carcinomas: its lack of neuroendocrine specificity. *J Clin Pathol*. 1986;39(11):1186–92.
- Lloyd RV, Mervak T, Schmidt K, Warner TF, Wilson BS. Immunohistochemical detection of chromogranin and neuron-specific enolase in pancreatic endocrine neoplasms. *Am J Surg Pathol*. 1984;8(8):607–14.
- Portela-Gomes GM, Hacker GW, Weitgasser R. Neuroendocrine cell markers for pancreatic islets and tumors. *Appl Immunohistochem Mol Morphol*. 2004;12(3):183–92.
- Rindi G, Bordi C, Rappel S, La Rosa S, Stolte M, Solcia E. Gastric carcinoids and neuroendocrine carcinomas: pathogenesis, pathology, and behavior. *World J Surg*. 1996;20(2):168–72.
- Angelsen A, Syversen U, Haugen OA, Stridsberg M, Mjølnerod OK, Waldum HL. Neuroendocrine differentiation in carcinomas of the prostate: do neuroendocrine serum markers reflect immunohistochemical findings? *Prostate*. 1997;30(1):1–6.
- Bofin AM, Qvigstad G, Waldum C, Waldum HL. Neuroendocrine differentiation in carcinoma of the breast. Tyramide signal amplification discloses chromogranin A-positive tumour cells in more breast tumours than previously realized. *APMIS*. 2002;110(9):658–64.
- Fresvig A, Qvigstad G, Halvorsen TB, Falkmer S, Waldum HL. Neuroendocrine differentiation in bronchial carcinomas of classic squamous-cell type: an immunohistochemical study of 29 cases applying the tyramide signal amplification technique. *Appl Immunohistochem Mol Morphol*. 2001;9(1):9–13.
- Langley K, Gratzl M. Neural cell adhesion molecule NCAM in neural and endocrine cells. In: Gratzl M, Langley K, editors. *Markers for Neural and Endocrine Cells. Molecular and Cell Biology, Diagnostic Applications*. Weinheim, Germany: Verlag Chemie; 1991;133–78.
- Jin L, Hemperly JJ, Lloyd RV. Expression of neural cell adhesion molecule in normal and neoplastic human neuroendocrine tissues. *Am J Pathol*. 1991;138(4):961–9.
- Zheng G, Ettinger DS, Maleki Z. Utility of the quantitative Ki-67 proliferation index and CD56 together in the cytologic diagnosis of small cell lung carcinoma and other lung neuroendocrine tumors. *Acta Cytol*. 2013;57(3):281–90.
- Birkenkamp-Demtröder K, Wagner L, Sørensen FB, Astrup LB, Gartner W, Scherübl H, Heine B, Christiansen



- P, Ørntoft TF. Secretagogin is a novel marker for neuroendocrine differentiation. *Neuroendocrinology*. 2005;82(2):121–38.
19. Adolf K, Wagner L, Bergh A, Stattin P, Ottosen P, Borre M, Birkenkamp-Demtröder K, Ørntoft TF, Tørring N. Secretagogin is a new neuroendocrine marker in the human prostate. *Prostate*. 2007;67(5):472–84. doi:10.1002/pros.20523.
  20. Mjones PG, Nordrum IS, Qvigstad G, Sordal O, Rian LL, Waldum HL. Expression of erythropoietin and neuroendocrine markers in clear cell renal cell carcinoma. *APMIS*. 2017;125(3):213–22. doi:10.1111/apm.12654.
  21. Bakkelund K, Fossmark R, Nordrum I, Waldum H. Signet ring cells in gastric carcinomas are derived from neuroendocrine cells. *J Histochem Cytochem*. 2006;54(6):615–21. doi:10.1369/jhc.5A6806.2005.
  22. Bosman FT, Carneiro F, Hruban RH, Theise ND, editors. WHO classification of tumours of the digestive system. 4th ed. Lyon: International Agency for Research on Cancer; 2010.
  23. Travis WD, Brambilla E, Burke A, Marx A, Nicholson AG. WHO classification of tumours of the lung, pleura, thymus and heart. Lyon: International Agency for Research on Cancer; 2015.
  24. Lakhani SR. WHO classification of tumours of the breast. Lyon: International Agency for Research on Cancer; 2012.
  25. Ulbright TM, Amin MB, Balzer B, Berney DM, Epstein JI, Guo C, Skakkebaek NE. WHO classification of tumours of the urinary system and male genital organs. Lyon: International Agency for Research on Cancer; 2016.
  26. Lauren P. The two histological main types of gastric carcinoma: diffuse and so-called intestinal-type carcinoma. An attempt at a histo-clinical classification. *Acta Pathol Microbiol Scand*. 1965;64:31–49.
  27. Mahul BM, editor. AJCC cancer staging manual. 8th ed. Cham, Switzerland: Springer International Publishing; 2017.
  28. McShane LM, Altman DG, Sauerbrei W, Taube SE, Gion M, Clark GM. REporting recommendations for tumour MARKer prognostic studies (REMARK). *Nat Clin Pract Urol*. 2005;2(8):416–22.
  29. Wilson BS, Lloyd RV. Detection of chromogranin in neuroendocrine cells with a monoclonal antibody. *Am J Pathol*. 1984;115(3):458–68.
  30. Haimoto H, Takahashi Y, Koshikawa T, Nagura H, Kato K. Immunohistochemical localization of gamma-enolase in normal human tissues other than nervous and neuroendocrine tissues. *Lab Invest*. 1985;52(3):257–63.
  31. Ronkainen H, Soini Y, Vaarala MH, Kauppila S, Hirvikoski P. Evaluation of neuroendocrine markers in renal cell carcinoma. *Diagn Pathol*. 2010;5:28. doi:10.1186/1746-1596-5-28.
  32. Abbona G, Papotti M, Viberti L, Macri L, Stella A, Bussolati G. Chromogranin A gene expression in non-small cell lung carcinomas. *J Pathol*. 1998;186(2):151–6. doi:10.1002/(sici)1096-9896(1998100)186:2<151::aid-path154>3.0.co;2-7.
  33. Wagner L, Oliyarnyk O, Gartner W, Nowotny P, Groeger M, Kaserer K, Waldhäusl W, Pasternack MS. Cloning and expression of secretagogin, a novel neuroendocrine- and pancreatic islet of Langerhans-specific Ca<sup>2+</sup>-binding protein. *J Biol Chem*. 2000;275(32):24740–51.
  34. Ilhan A, Nezir D, Maj M, Mazal PR, Susani M, Base W, Gartner W, Wagner L. Expression of secretagogin in clear-cell renal cell carcinomas is associated with a high metastasis rate. *Hum Pathol*. 2011;42(5):641–8. doi:10.1016/j.humpath.2010.10.004.
  35. Wick MR, Scheithauer BW, Kovacs K. Neuron-specific enolase in neuroendocrine tumors of the thymus, bronchus, and skin. *Am J Clin Pathol*. 1983;79(6):703–7.
  36. Veras E, Deavers MT, Silva EG, Malpica A. Ovarian non-small cell neuroendocrine carcinoma: a clinicopathologic and immunohistochemical study of 11 cases. *Am J Surg Pathol*. 2007;31(5):774–82.
  37. Qvigstad G, Sandvik AK, Brenna E, Aase S, Waldum HL. Detection of chromogranin A in human gastric adenocarcinomas using a sensitive immunohistochemical technique. *Histochem J*. 2000;32(9):551–6.
  38. Paganì A, Papotti M, Abbona GC, Bussolati G. Chromogranin gene expressions in colorectal adenocarcinomas. *Mod Pathol*. 1995;8(6):626–32.
  39. Righi L, Sapino A, Marchio C, Papotti M, Bussolati G. Neuroendocrine differentiation in breast cancer: established facts and unresolved problems. *Semin Diagn Pathol*. 2010;27(1):69–76.
  40. Berruti A, Bollito E, Cracco CM, Volante M, Ciccone G, Porpiglia F, Papotti M, Scarpa RM, Dogliotti L. The prognostic role of immunohistochemical chromogranin A expression in prostate cancer patients is significantly modified by androgen-deprivation therapy. *Prostate*. 2010;70(7):718–26. doi:10.1002/pros.21104.
  41. Jiang SX, Mikami T, Umezawa A, Saegusa M, Kameya T, Okayasu I. Gastric large cell neuroendocrine carcinomas: a distinct clinicopathologic entity. *Am J Surg Pathol*. 2006;30(8):945–53.
  42. Ferolla P, Faggiano A, Mansueto G, Avenia N, Cantelmi MG, Giovenali P, Del Basso De Caro ML, Milone F, Scarpelli G, Masone S, Santeusano F, Lombardi G, Angeletti G, Colao A. The biological characterization of neuroendocrine tumors: the role of neuroendocrine markers. *J Endocrinol Invest*. 2008;31(3):277–86. doi:10.1007/bf03345602.
  43. Sarvi S, Mackinnon AC, Avlonitis N, Bradley M, Rintoul RC, Rassl DM, Wang W, Forbes SJ, Gregory CD, Sethi T. CD133+ cancer stem-like cells in small cell lung cancer are highly tumorigenic and chemoresistant but sensitive to a novel neuropeptide antagonist. *Cancer Res*. 2014;74(5):1554–65. doi:10.1158/0008-5472.can-13-1541.
  44. Friedmann-Morvinski D, Bushong EA, Ke E, Soda Y, Marumoto T, Singer O, Ellisman MH, Verma IM. Dedifferentiation of neurons and astrocytes by oncogenes can induce gliomas in mice. *Science*. 2012;338(6110):1080–4. doi:10.1126/science.1226929.
  45. Ryberg B, Tielemans Y, Axelson J, Carlsson E, Hakanson R, Mattson H, Sundler F, Willems G. Gastrin stimulates the self-replication rate of enterochromaffin-like cells in the rat stomach. Effects of omeprazole, ranitidine, and gastrin-17 in intact and antrectomized rats. *Gastroenterology*. 1990;99(4):935–42.