Neurobiology of Aging 36 (2015) 2555–2562

Contents lists available at ScienceDirect

Neurobiology of Aging

journal homepage: www.elsevier.com/locate/neuaging

Perimenopausal hormone therapy is associated with regional sparing of the CA1 subfield: a HUNT MRI study

Carl W.S. Pintzka [a,b], Asta K. Håberg [a,b,*]

[a] Department of Neuroscience, Faculty of Medicine, Norwegian University of Science and Technology (NTNU), Trondheim, Norway
[b] Department of Medical Imaging, St. Olav's Hospital, Trondheim, Norway

ARTICLE INFO

Article history:
Received 5 January 2015
Received in revised form 5 May 2015
Accepted 31 May 2015
Available online 9 June 2015

Keywords:
Critical widow theory
Estrogen
Menopause
Hippocampus
Aging
Alzheimer's disease

ABSTRACT

Observational studies support a neuroprotective role of hormone therapy (HT) in the perimenopause, with hippocampal size being a widely used biomarker. We investigated the effect of HT started before the onset of menopause and lasting for at least 3 years on hippocampal volume and shape in 80 postmenopausal women and 80 controls matched on age and intracranial volume taken from a large community-based sample (Nord-Trøndelag Health Study—magnetic resonance imaging). The main effect of hormone group showed a statistically significant difference in hippocampal volumes ($p = 0.028$). Both the right (3.2%) and left (2.8%) hippocampal volumes were larger in the HT group but only significant for the right hippocampus ($p = 0.023$). Shape analysis revealed significant regional sparing of the medial aspect of the right hippocampal head and lateral aspect of the body extending to the tail, corresponding to the cornu ammonis, including part of the subiculum, in the HT group. A similar nonsignificant pattern was observed in the left hippocampus. The present study provides support for the critical window theory demonstrating that HT initiated in the perimenopause has neuroprotective properties.

1. Introduction

Whether hormone therapy (HT) has the potential to reduce the risk of dementia and Alzheimer's disease (AD) in women continues to draw debate. Despite convincing evidence from several human observational studies (Kawas et al., 1997; Shao et al., 2012; Tang et al., 1996; Whitmer et al., 2011; Zandi et al., 2002), 2 large randomized controlled trials (RCTs), the Women's Health Initiative Memory Study (WHIMS) and the Heart and Estrogen/Progestin Replacement Study, found poorer cognitive performance (Espeland et al., 2004; Grady et al., 2002; Rapp et al., 2003) and increased risk of developing dementia (Shumaker et al., 2003) in women that used HT. Several methodological differences are suggested to explain the discrepant results between observational and clinical trials, including differences in HT formulation, dosage, cyclic versus continuous hormone delivery and timing of HT administration in relation to menopause (Fischer et al., 2014; Maki and Henderson, 2012). The importance of the timing of HT in relation to menopause may be particularly relevant. Indeed, the critical window theory proposes that only HT initiated around the onset of menopause has neuroprotective effects (Marder and Sano, 2000; Resnick and Henderson, 2002). The WHIMS and Heart and Estrogen/Progestin Replacement Studies included women who were much older and started HT many years after menopause, in whom positive effects of HT are not expected according to the critical window theory. Although there are several observational studies that support the critical window theory (Shao et al., 2012; Whitmer et al., 2011), a recent meta-analysis of HT trials on cognition was unable to provide evidence for a specific effect of HT treatment started before menopause as opposed to later (Hogervorst and Bandelow, 2010). No effect of age, initiation perimenopausally or postmenopausally, nor duration of HT affected the cognitive outcome (Hogervorst and Bandelow, 2010). However, based largely on the WHIMS study, there is strong evidence to support that HT initiated at age 65 years or older increases dementia risk (Maki and Henderson, 2012). Much less is known about the effect of HT administration to younger women starting around the onset of menopause, although this represents the group potentially benefitting most from HT treatment according to the critical window theory.

In humans, the hippocampus is considered a strong predictor for overall brain health (Wnuk et al., 2012) and is essential for declarative memory (Squire, 1992). AD is associated with hippocampal pathology (Braak and Braak, 1991), and both hippocampal shape and volume can predict the onset of AD (Csernansky et al., 2005).

* Corresponding author at: Department of Neuroscience, Faculty of Medicine, Norwegian University of Science and Technology (NTNU), 7489 Trondheim, Norway. Tel.: +47 73551352; fax: +47 73551350.
E-mail address: asta.haberg@ntnu.no (A.K. Håberg).

0197-4580/
http://dx.doi.org/10.1016/j.neurobiolaging.2015.05.023

The hippocampus has a high level of estrogen receptors (Bean et al., 2014) and is therefore the preferred structure to investigate for estrogen-induced neuroprotective effects. Moreover, hippocampal size is associated with verbal memory performance (Hackert et al., 2002; O'Driscoll et al., 2001), and recent evidence has shown that independent of age, menopause is followed by a decline in verbal memory (Epperson et al., 2013), suggesting a negative effect of menopause on hippocampal function. The hippocampal volume in HT users has in observational studies been reported to be larger (Eberling et al., 2003; Erickson et al., 2005, 2010; Lord et al., 2008) or not affected (Greenberg et al., 2006; Low et al., 2006) compared to controls. The only RCT that has assessed the effects of HT on hippocampal size is the WHIMS–magnetic resonance imaging (MRI) study, which demonstrated a negative effect on hippocampal volume when HT was initiated 15–30 years after menopause (Resnick et al., 2009). The discrepancies between these studies may be explained by the critical window theory, which posits that a positive effect on hippocampal structure will be limited to HT taken around the onset of menopause. Moreover, one study reported that duration of HT was negatively associated with hippocampal volume, pointing to a treatment duration effect (Lord et al., 2008).

In contrast to the ambiguous results from human studies, animal studies have firmly established beneficial effects of estrogens for brain physiology, anatomy, and function. For example, rodent studies in ovariectomized female rats have shown that estradiol replacement promotes angiogenesis (Barouk et al., 2011) and improves cell proliferation and cell survival in the hippocampus (Galea et al., 2006). Moreover, estradiol administration increases spine synapse density on pyramidal cell dendrites in the cornu ammonis (CA1) subfield of the hippocampus (Woolley and McEwen, 1992) and restores a more youthful synaptic profile in the CA1 subfield in normally aging female rats (Adams et al., 2004). Not only decreased hormone levels but also a lower number of estrogen receptors is reported in the normally aging female rat, with a specific reduction in estrogen receptor positive neurons in the CA1 subfield (Mehra et al., 2005). This reduction in number of estrogen receptors has been linked to the diminished cognitive enhancing effect of HT with increasing age observed in humans (Foster, 2012) and thus to the critical window theory. Furthermore, estradiol administration enhances performance on hippocampus-dependent tasks such as spatial navigation and working memory in ovariectomized rats (Gibbs, 2000; Luine et al., 1998; Packard and Teather, 1997). Estrogens are considered to counteract the neurodegenerative effects of aging via numerous pathways including increased expression of genes related to neuroprotection, preservation of neuronal microstructure, synaptic plasticity, and neurogenesis, while decreasing the expression of genes related to inflammation, stress, and transcription repressors (Bean et al., 2014). Estrogens have also been demonstrated to protect against brain pathology such as AD. In vitro models have shown that estradiol provides neuroprotection against β-amyloid protein toxicity (Goodman et al., 1996; Yao et al., 2007) and inhibits β-amyloid protein accumulation and tau hyperphosphorylation, crucial components in the development of AD (Pike et al., 2009).

In recent years, techniques for automated brain morphometric analyses have improved immensely. For example, local volume differences within hippocampal regions are detectable—even in the presence of similar overall volume (Persson et al., 2014). Previous studies examining the effects of HT on hippocampal volume have either investigated total volume (Erickson et al., 2010; Greenberg et al., 2006; Low et al., 2006) or subdivided the hippocampus into volumes of interests along its anterior-posterior axis (Eberling et al., 2003; Erickson et al., 2005). However, the evidence from rodent studies supports a specific neuroprotective effect of HT initiated around menopause in the CA1 subfield, which cannot be identified with these methods. We predicted that HT initiated around onset of menopause would result in larger hippocampal volume compared with controls and that the volume difference would be regionally confined to the CA1 subfield. To this end, we investigated the effects of HT initiated around the onset of menopause on hippocampal volume and shape in a large, community-based sample of postmenopausal women.

2. Material and methods

The study was approved by the Nord-Trøndelag Health Study (HUNT) board of directors and the regional ethics and health research committee (2011/456). All participants gave their informed written consent.

The HUNT Study is a collaboration between HUNT Research Centre (Faculty of Medicine, Norwegian University of Science and Technology NTNU), Nord-Trøndelag County Council, Central Norway Health Authority, and the Norwegian Institute of Public Health (Krokstad et al., 2013). It is a large multiphase, multipurpose health study on the inhabitants ≥13 years in the county of Nord-Trøndelag. The inhabitants of Nord-Trøndelag county have been invited to participate in 3 waves; HUNT1 (1984–86), HUNT2 (1995–97), and HUNT3 (2006–08). The overall participation rates were 89.4%, 69.5%, and 54.1%, respectively. However, in HUNT3 the participation rate for women in the age group 60–69 years was 74.5%. A nonparticipation study from HUNT3 showed that nonparticipants had lower socioeconomic status, higher mortality, and higher prevalences of several chronic diseases, whereas opposite patterns were found for common problems like musculoskeletal pain, urine incontinence, and headache (Langhammer et al., 2012). HUNT MRI was a substudy after HUNT3. The cohort invited to participate in HUNT MRI was drawn from the HUNT population, but limited to volunteers who had participated in HUNT 1, 2, and 3, and were between 50–65 years at time of inclusion in the HUNT MRI study. In total 73% of those invited to HUNT MRI agreed to participate (Honningsvag et al., 2012). The HUNT MRI cohort consisted of 1006 subjects (530 women). A study comparing participants and nonparticipants in the HUNT MRI study and subjects from the HUNT cohort not invited found that the groups were not widely different, but HUNT MRI participating women had a higher level of education, lower body mass index (BMI), lower blood pressure, but there was no difference with regard to number of individuals with hypertension, and fewer had fasting blood glucose ≥ 5.6 mmol/L but no difference in number of diabetic individuals (Honningsvag et al., 2012).

There were 175 women (33% of all HUNT MRI women) who were current or past users of HT, 80 (45.7%) of which met the inclusion criteria which were HT started before menopause and continued at least for 3 years and through the menopause. Both current and past users fulfilling these criteria were included. These subjects were then matched on intracranial volume (ICV) (±5%) and age (±1 year) with 80 never-users of HT from the remaining cohort. Although we were unable to retrieve information about the precise type of HT used by each individual, data from the Norwegian Prescription Registry show that during the time frame of the study and in this region, 83.5% of HT users were prescribed a combination of estradiol and/or estriol and progesterone, 9.0% either estradiol or estriol without progesterone, and 7.5% used the synthetic estrogen tibolone. Importantly, there were no users of conjugated equine estrogens.

Information about age, BMI, systolic and diastolic blood pressure, HT (age at onset and duration), age at menarche and menopause, number of pregnancies and births, type of menopause (surgical and/or natural), as well as a number of comorbidities were taken from HUNT3 clinical measurement data which was obtained

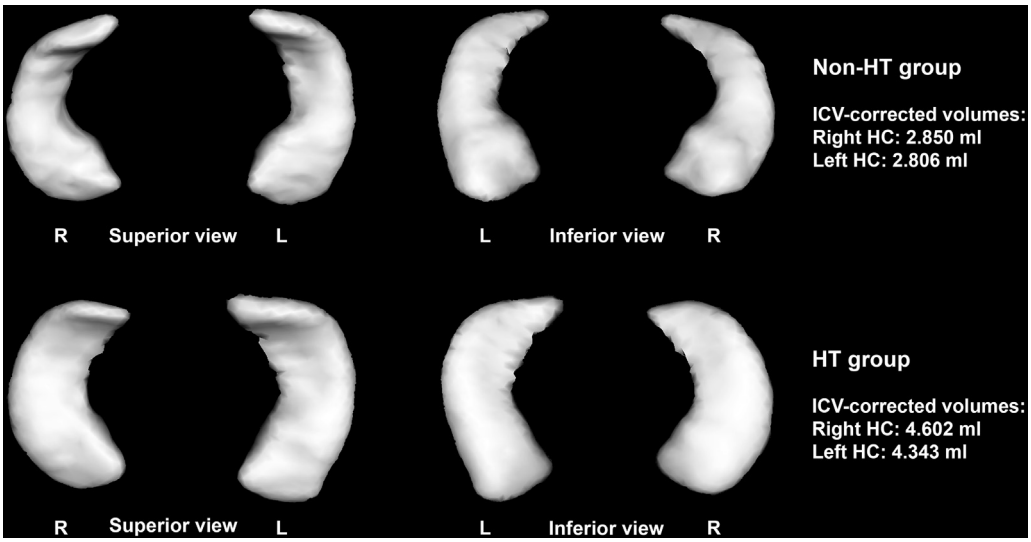

Fig. 1. Example of hippocampal shape in one HT participant and non-HT participant matched on age and ICV. These hippocampal surface models were used in the vertex-by-vertex shape analysis, for details see Section 2. Abbreviations: HC, hippocampus; HT, hormone therapy; ICV, intracranial volume.

right before HUNT MRI scanning. The following 13 comorbidities were investigated; cerebral insult and hemorrhage, psychological problems, myocardial infarction, atrial fibrillation, heart failure, diabetes, epilepsy, asthma, chronic obstructive pulmonary disease as well as the number of daily and occasional smokers, and the number of heavy drinkers (>2 drinks per day). Furthermore, self-reported memory problems were assessed with 9 questions in HUNT3 based on the metamemory questionnaire (Fromholt and Berg, 1997). The 2 first items asked about memory capacity in general: "Do you have problems with your memory?" and "Has your memory changed since you were younger?" The response categories were "no", "yes, some", and "yes, a lot". The following 7 items were related to performance on specific memory tasks: "Do you have problems remembering…": (1) "… what happened a few minutes ago", (2) "… the names of other people", (3) "… dates", (4) "… to carry out planned activities", (5) "… what happened a few days ago", (6) "… what happened some years ago", and (7) "Do you have problems keeping track of a conversation". Response categories were "never", "sometimes", and "often" (Holmen et al., 2013). There were missing or partial missing data on the self-reported memory problems in 18 participants. Information on education (a scale from 1 to 5, 1 = primary school, 2 = high school, 3 = junior college, 4 = university less than 4 years, 5 = university more than 4 years) was taken from the HUNT2 demographic data.

Imaging was performed on the same 1.5 T General Electric Signa HDx MRI scanner equipped with an 8-channel head coil (GE Healthcare) and software version pre-14.0M4. The examinations were conducted by 8 MRI technologists following a standardized written and illustrated procedure. In the present study the Alzheimer's disease Neuroimaging Initiate volume, (http://adni.loni.usc.edu/methods/documents/mri-protocols/) which is a T1-weighted (T1W) magnetization prepared rapid gradient echo (MP-RAGE) volume (repitition time = 10.156 ms, echo time = 4.044 ms, field of view = 240 mm, slice thickness = 1.2 mm, matrix 192 × 192, flip angle 10°) was used.

The data sets were analyzed with FreeSurfer 4.5 (http://surfer.nmr.mgh.harvard.edu/) for segmentation of the hippocampal volumes using an automated procedure described previously (Fischl et al., 2002). To avoid bias, all FreeSurfer results were visually inspected by a blinded colleague at the Multimodal Imaging Laboratory, University of California, San Diego, where the data analysis was performed and all subpar data sets removed. There have been numerous studies comparing FreeSurfer segmentation with manual segmentation of hippocampal volumes and the general finding is that FreeSurfer segmentation is a reliable option to manual segmentation (Cherbuin et al., 2009; Doring et al., 2011; Morey et al., 2009; Mulder et al., 2014; Shen et al., 2010; Wenger et al., 2014). ICV estimation was performed in SPM8 (rel. 5236) (http://www.fil.ion.ucl.ac.uk/spm) using an automated version of the reverse brain mask method (Keihaninejad et al., 2010) called the "automatic reverse brain mask method". This method was recently shown to have improved accuracy compared with the ICV estimate generated by FreeSurfer (Hansen et al., 2015). Right and left hippocampal volume was ICV corrected using the residuals method (Buckner et al., 2004; Raz et al., 2004).

Reliable manual subfield segmentation based on the current MP-RAGE volume obtained at 1.5 T is not possible. Automated subfield segmentation in FreeSurfer is theoretically possible, but there have been several reports that raise concerns about the validity of this method based on both 1.5 T and 3.0 T standard resolution T1W 3D MRI images (de Flores et al., 2015; Wisse et al., 2014). We therefore opted for an alternative method, which through shape analysis reflects changes in subfield volumes (Patenaude et al., 2011). We used tools from the FMRIB Software Library 5.0.7 software to analyze regional volume changes in the hippocampus (Smith et al., 2004). Local shape differences were compared between the 2 groups using a vertex-by-vertex analysis based on FMRIB's Integrated Registration and Segmentation Tool (FIRST) 1.2 (Patenaude et al., 2011). First, a surface mesh of the hippocampus in each subject is created using a deformable mesh model composed of a set of vertices. The number of vertices in the hippocampus is fixed so that corresponding vertices can be compared between groups (Lim et al., 2012a). Examples of the shape analysis for 1 HT and 1 non-HT subject are shown in Fig. 1. The hippocampal surface for the right and left hippocampus, respectively, of each participant were then aligned to an average hippocampus model of left and right hippocampus, respectively, provided by FIRST using a 6-degrees of freedom transformation. Group differences in the surface displacement maps were analyzed in FMRIB Software Library using randomize for nonparametric permutation-based inference (n = 5000) and cluster corrected for multiple comparisons at $F > 2.3$ (Winkler et al., 2014). The anatomical subfields with significant differences in surface areas between the groups were identified

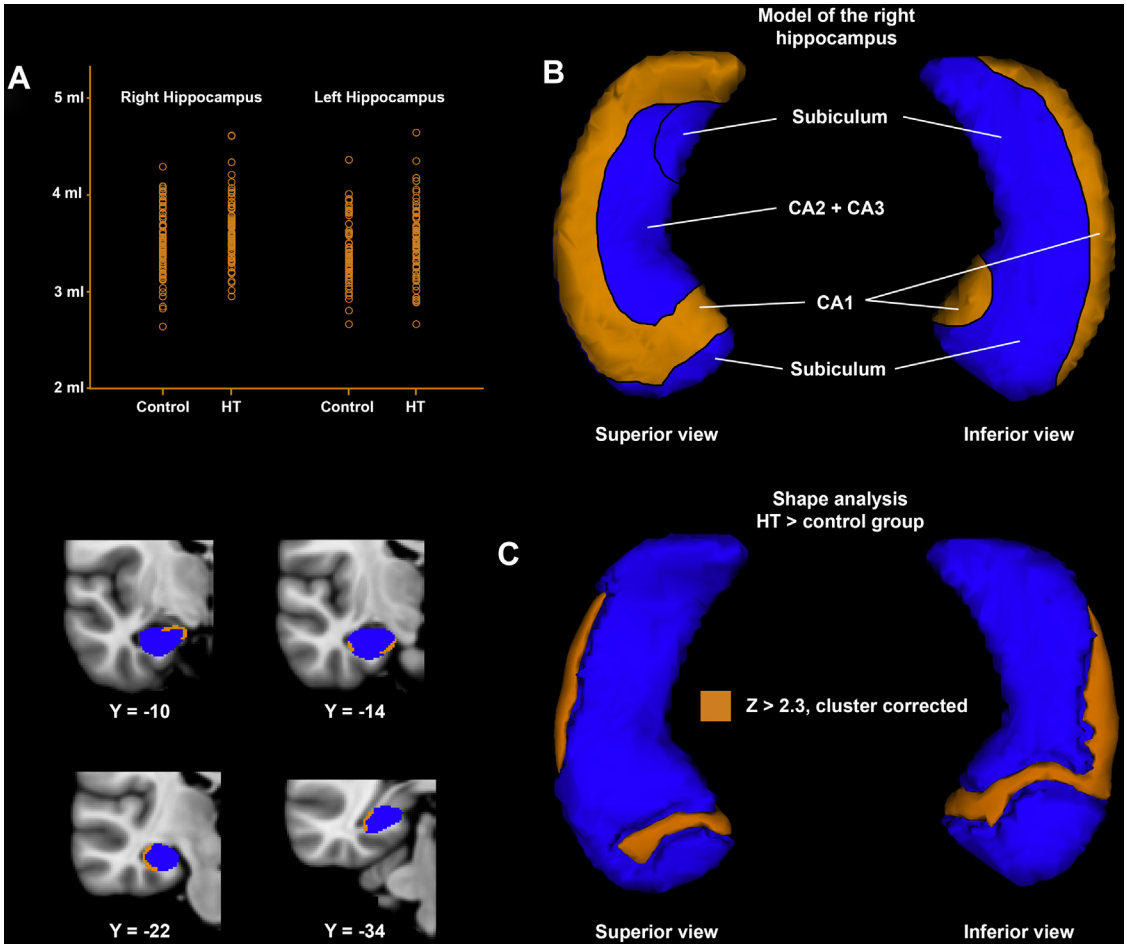

Fig. 2. (A) A significant volume sparing effect of hormone therapy (HT) was found for the right hippocampus. A nonsignificant trend was found for the left hippocampus. (B) Hippocampal subfields mapped onto a model of the right hippocampus, based on the definitions from Duvernoy, 2005 and West and Gundersen, 1990. The cornu ammonis (CA1) subfield is colored in orange. (C) A vertex (shape) analysis reveals that the overall volume difference of the right hippocampus was driven by regional sparing of the CA1 and parts of the subiculum. Orange color indicates areas that are larger in the HT group. The analysis was performed using FIRST, cluster corrected for multiple comparisons, $F > 2.3$.

based on the definitions from (Duvernoy, 2005) and (West and Gundersen, 1990) (Fig. 2B).

Other statistical analyses were performed in SPSS 21.0 (SPSS Inc, Chicago, Illinois, USA). Statistical outliers were determined using the outlier labeling rule (Hoaglin and Iglewicz, 1987). A mixed analysis of variance was run to determine the main effect of HT on the hippocampal volumes. Subsequently, simple main effects were investigated using separate between-subjects analyses of variance for the right and left hippocampus. Independent-sample *t* tests were run to determine if there were differences in mean ICV, age, BMI, age at menarche and menopause, and overall self-reported memory problem score between the HT and control group, whereas nonparametric Mann-Whitney *U* tests were run to determine if there were group differences in level of education and number of pregnancies and births. χ^2 tests were run to assess group differences in the type of menopause (surgical and/or natural), the 13 comorbidities, and the separate self-reported memory questions. A corrected $p < 0.05$ was considered significant. Data are presented as mean ± standard deviation, unless otherwise stated.

3. Results

The age range of the included women was 51–66 years. There was no difference in ICV nor was there any difference in BMI, blood pressure, education, time at menarche, menopause, number of pregnancies or births, or type of menopause (surgical and/or natural) between the 2 groups. The HT group had used estrogen for 7.82 ± 3.43 years (range: 3–15 years) and included 15 current and 65 past users (Table 1). There were no significant differences between the 2 groups on any of the investigated comorbidities (Table 2). The mean overall self-reported memory problems score in the HT group (14.26 ± 2.66) was similar to the control group (13.62 ± 2.80), $p = 0.174$. Table 3 shows the scores on each self-reported memory question, no differences between the HT and control groups were found.

Fig. 2A and Table 1 show the group differences for the ICV corrected hippocampal volumes. The hippocampal volumes were normally distributed and there were no statistical outliers (Fig. 2A). The main effect of hormone group demonstrated a statistically significant difference in hippocampal volumes between the 2 groups, $F(1, 158) = 4.932$, $p = 0.028$. Both the right (3.627 ± 0.314 vs. 3.511 ± 0.327 mL) and left (3.511 ± 0.351 vs. 3.413 ± 0.301 mL) hippocampal volumes were larger in the HT group. This difference was, however, only significant for the right hippocampus, $F(1, 158) = 5.236$, $p = 0.023$.

Fig. 2C shows the results from the vertex analysis of the right hippocampus. The orange areas indicate surface areas that were significantly larger in the HT group, cluster corrected for multiple

Table 1
Demographic characteristics and magnetic resonance imaging–derived intracranial and hippocampal volumes of the HT and matched control group

	Control group (n = 80)	HT group (n = 80)	*p*-value
Age (y)	59.8 ± 3.6	59.8 ± 3.6	1.000[a]
BMI (kg/m^2)	26.8 ± 4.4	26.7 ± 4.1	0.790[a]
SBP (mm Hg)	132.2 ± 18.8	130.6 ± 15.1	0.560[a]
DBP (mm Hg)	74.1 ± 10.8	74.0 ± 10.5	0.934[a]
Education (group)	2.53 ± 1.48	2.62 ± 1.30	0.693[b]
Menarche (y)	13.3 ± 1.4	13.3 ± 1.5	0.955[a]
Menopause (y)	50.0 ± 4.7	50.4 ± 3.1	0.505[a]
Number of pregnancies	2.9 ± 1.3	2.6 ± 1.2	0.181[b]
Number of births	2.4 ± 0.9	2.3 ± 0.8	0.332[b]
Number of participants with surgical menopause	2 (2.5)	6 (7.5)	0.147[c]
Age at onset of HT (y)	NA	50.0 ± 3.2	NA
Duration of HT (y)	NA	7.8 ± 3.4	NA
ICV (mL)	1438.5 ± 96.3	1435.3 ± 98.6	0.833[a]
Right hippocampal volume (mL)	3.511 ± 0.327	3.628 ± 0.314	0.023[d,*]
Left hippocampal volume (mL)	3.413 ± 0.301	3.511 ± 0.351	0.060[d]

*p-value < 0.05.
Education is rated on a scale from 1 to 5, 1 = primary school, 2 = high school, 3 = junior college, 4 = university less than 4 y, 5 = university more than 4 y. Data are presented as mean ± standard deviation or as n with (%) for surgical menopause.
Key: BMI, body mass index; DBP, diastolic blood pressure; HT, hormone therapy; ICV, intracranial volume; NA, not applicable; SBP, systolic blood pressure.
[a] Group differences assessed with independent samples *t* tests.
[b] Group differences assessed with nonparametric Mann-Whitney *U* test.
[c] Group differences assessed with χ^2 test.
[d] Group differences assessed with between-subjects analysis of variance.

comparisons at F > 2.3. The shape analysis showed that the effect of HT on the right hippocampal volume was driven by regional sparing of the medial aspect of the head and lateral aspect of the body extending to the tail, corresponding to the CA1 subfield and including part of the subiculum. The assignment of the shape changes to these hippocampal subfields was based on anatomical knowledge (Fig. 2B). No statistically significant difference in the left hippocampal shape was detected between the 2 groups, although a similar pattern was observed below the predefined statistical threshold.

4. Discussion

In the present study, we demonstrate a positive effect of perimenopausal HT on hippocampal volume in a large, general population based, well-matched sample of women aged 51–66 years. The volume sparing effect of HT was shown to be regionally confined mainly to the CA1 subfield and was significant for the right side only.

We found increased hippocampal volume in the medial aspect of the head and lateral aspect of the body extending to the tail, approximately corresponding to the CA1 subfield, including part of the subiculum. This pattern of hippocampal subfield volume loss in the nonHT group compared to the HT group, is strikingly similar to the hippocampal volume loss reported in numerous imaging studies comparing AD or mild cognitive impairment (MCI) patients with matched controls (Apostolova et al., 2006; Gerardin et al., 2009; Lim et al., 2012b; Seidl et al., 2012). Moreover, histopathological studies have demonstrated that these hippocampal subfields are predominantly affected in AD (Hyman et al., 1984; Van Hoesen and Hyman, 1990). The shape in the areas corresponding to the CA2 and CA3 subfields were similar in the HT compared with the non-HT group, which is consistent with both histopathological (Hyman et al., 1984; Van Hoesen and Hyman, 1990) and imaging (Frisoni et al., 2006) findings in AD patients. Significant volume sparing effects of HT was found in the right hippocampus only, although a similar volume sparing pattern was observed in the left hippocampus below the predefined statistical threshold (results not shown). A more marked effect of HT on the right hippocampus is in-line with several of the previous observational HT studies (Eberling et al., 2003, 2004; Lord et al., 2008). Moreover, an asymmetrical atrophy rate with faster volume loss in the right hippocampus has been shown during the transition from healthy to MCI and from MCI to AD, for review see Shi et al., 2009. Indeed, a strong correlation between hippocampal volume and CA1 neuron loss has been demonstrated in both AD patients and normal aging (Kril et al., 2004), suggesting that the larger hippocampal volume in the present study represents an actual neuroprotective effect of HT. Taken together, we have demonstrated a localized volume sparing effect of HT on the right hippocampal CA1 subfield, an area that is affected in the development of MCI and AD.

In the present study, the HT group had used HT for a relative short time (mean 7.8 years). Previous studies that report positive effects of HT on hippocampal volumes report somewhat longer HT duration than our study (~12.0, 14.3, and 10.5 years) (Erickson et al., 2005, 2010; Lord et al., 2008), whereas 1 study that found a negative effect of HT on gray matter volumes had a very long mean duration of treatment (23.5 years) (Greenberg et al., 2006). It has further been shown that the duration of HT is negatively associated

Table 2
Prevalence of comorbidities in the HT and matched control group

	Control group (n = 80)	HT group (n = 80)	*p*-value
Cerebral insult	4 (5.0)	1 (1.3)	0.173
Cerebral hemorrhage	4 (5.0)	2 (2.5)	0.405
Psychological problems	16 (20.0)	21 (26.3)	0.348
Myocardial infarction	1 (1.3)	0 (0)	0.316
Atrial fibrillation	1 (1.3)	0 (0)	0.316
Heart failure	0 (0)	0 (0)	1.000
Diabetes	2 (2.5)	2 (2.5)	1.000
Epilepsy	1 (1.3)	0 (0)	0.316
Asthma	6 (7.5)	8 (10.0)	0.576
COPD	1 (1.3)	0 (0)	0.316
Daily smokers	17 (21.3)	15 (18.8)	0.693
Occasional smokers	6 (7.5)	8 (10.0)	0.576
Heavy drinkers	1 (1.3)	2 (2.5)	0.560

Data are presented as n (%). Group differences assessed with χ^2 test. A corrected *p*-value of 0.0038 (0.05/13) was considered significant.
Key: COPD, chronic obstructive pulmonary disease; HT, hormone therapy.

Table 3
Prevalence of 9 items of self-reported memory problems in the HT and matched control group

	Control group		HT group		*p*-value
	Some	Great	Some	Great	
Problems with memory (%)	49.2	0	53.2	1.3	0.568
Memory changed (%)	70.8	4.6	78.5	10.1	0.071
	Sometimes	Often	Sometimes	Often	
Problems remembering minutes ago (%)	17.2	0	17.9	0	0.906
Problems remembering names (%)	71.4	14.3	81.3	13.8	0.150
Problems remembering dates (%)	57.1	4.8	66.3	5.0	0.494
Problems remembering plans (%)	25.0	0	27.8	0	0.701
Problems remembering days ago (%)	28.6	3.2	43.8	0	0.062
Problems remembering years ago (%)	57.8	6.3	73.8	3.8	0.131
Problems keeping track of conversation (%)	15.4	0	26.3	0	0.112

Data are presented as %. Group differences assessed with χ^2 test. A corrected *p*-value of 0.0055 (0.05/9) was considered significant.
Key: HT, hormone therapy.

with hippocampal volume, pointing to a treatment duration effect, that is, that HT is only beneficial for a limited time after menopause (Lord et al., 2008). Consistent with our results, 1 observational study found an association between HT initiated coincidentally with menopause and larger overall hippocampal volume, whereas no difference in hippocampal volume was found when HT was initiated several years after menopause (Erickson et al., 2010). The only RCT that has assessed the effects of HT on hippocampal volume demonstrated a negative effect when HT was initiated 15–30 years after menopause (Resnick et al., 2009). Moreover, no group difference was found in the mean self-reported memory score in the present study, and both groups' self-reported memory score was comparable to the results found in a larger sample from the HUNT cohort (Holmen et al., 2013). The WHIMS of younger women clinical trial found neither beneficial nor harmful effects of 7 years of HT on several cognitive measures. Although the participants in WHIMS of younger women were younger than in the original WHIMS study, the mean time between menopause and initiation of HT was 7 years (Espeland et al., 2013). Likewise, preliminary results from the Kronos Early Estrogen Prevention Study assessing the effects of HT started within 3 years after menopause indicate neither beneficial nor harmful effects of HT on tests of cognition. Importantly, neither of these studies investigated the effects of HT started before the menopause, but rather several years after, and thus outside the hypothesized critical window.

Some limitations should be noted. First, the vertex analysis for demonstration of hippocampal shape differences is performed on the whole hippocampus, and no subfield segmentation was performed. Thus, the anatomical localization of the differences in surface anatomy between the groups relies on anatomical knowledge (Duvernoy, 2005; West and Gundersen, 1990). To date, no validation study has been performed that compares local shape differences with volumetric measurement of the underlying subfield. Although shape analysis cannot be compared directly to either manual or automatically derived subfield volumetric measurements, it provides similar and sometimes more information. Indeed, a recent study in early-stage Parkinson's patients demonstrated that disease-related structural change was undetectable when investigating overall regional volume but could be identified with shape analysis (Menke et al., 2014). Furthermore, in disorders where hippocampal atrophy does not occur uniformly, localized shape differences can be detected despite comparable overall subfield volume. For example, a study by Costafreda et al. (2011) investigated the hippocampal shape in a group of 103 MCI subjects acquired with 1.5 T using the Alzheimer's disease Neuroimaging Initiate protocol (Costafreda et al., 2011). Using hippocampal shape abnormalities they were able to predict 1-year conversion to AD with an accuracy of 80% and the pattern of atrophy associated with increased risk of conversion to AD was localized to the anterior part of the CA1. Moreover, using hippocampal shape to predict the conversion to AD was found to be comparable or superior to volumetric models. This study clearly demonstrates that even in MRI images with limited resolution, shape analysis cannot only pinpoint differences to hippocampal subfields but also predict future disease, thus demonstrating that detected shape differences represent relevant pathological processes. The shape analysis method has also been successfully used on both 1.5 T and 3.0 T standard resolution T1W 3D MRI images to address the impact of AD and MCI (Lim et al., 2012a, 2012b; Seidl et al., 2012), normal aging (Jiang et al., 2014; Thomann et al., 2013), temporal lobe epilepsy (Mumoli et al., 2013), multiple sclerosis (Gold et al., 2014), puberty (Satterthwaite et al., 2014), Niemann-Pick disease (Walterfang et al., 2013), and erythropoietin (Miskowiak et al., 2014) on the shape of the hippocampus and its subfields.

Furthermore, we did not differentiate between current and past users of HT. Whether HT has transient or lasting neuroprotective effects remains unknown. One study reported an effect of time since HT use on hippocampal volume (Lord et al., 2008), but most studies have grouped current and past users and reported beneficial effects of HT on brain structure (Erickson et al., 2005, 2010). Finally, HT users were identified by means of self-report, and no information about exact type or dose was registered at the individual level. However, HT users in Norway and in this region, as established through the Norwegian Prescription Registry, take primarily estradiol and/or estriol with progesterone, rather than conjugated equine estrogens, which are widely used in the United States. The results, thus, point to a positive effect of perimenopausal HT in general on hippocampal volume, which may be further potentiated with more tailored drugs.

The main strengths of the study include a large, ICV- and age-matched population-based sample with a narrow age range. There are several methods to correct for ICV differences and consensus is lacking on which method to use. Indeed, amongst the previous studies investigating the effects of HT on hippocampal volume none were matched on ICV, and several different ICV correction methods have been used including the proportions method (Eberling et al., 2003), the residuals method (Erickson et al., 2010), analysis of covariance (Resnick et al., 2009), or no ICV correction at all (Lord et al., 2008). A recent study comparing different ICV correction methods report a significant effect of method when investigating the impact of sex and aging on different cortical and subcortical volumetric measures (Voevodskaya et al., 2014). By matching the subjects on ICV this possible confounder is eliminated. To the best of our knowledge, only 2 previous studies investigating the effects of HT on hippocampal volumes have been performed on general population-based samples (Eberling et al., 2003; Low et al., 2006), both performed in older women than here, and less stringently described cohorts. The HUNT MRI study had a participation rate of 73%, and participants were drawn from the HUNT study, a longitudinal population health study in Norway, where participation for the age range invited here is also >70% (Honningsvag et al., 2012). A participation rate of >70% is acceptable and increases the probability of representativeness (Stovner et al., 2014). In contrast, the use of volunteers in cross-sectional studies can be problematic as they are unlikely to be representative of the general population (Mann, 2003).

5. Conclusions

The present study supports the hypothesis that HT initiated around the onset of menopause has neuroprotective properties. We further demonstrate, for the first time, regional sparing confined mainly to the CA1 subfield of the right hippocampus, an area that is closely linked to the development of MCI and AD.

Disclosure statement

The authors declare no competing financial interests and have not received funding or other benefits from pharmacological companies.

Acknowledgements

This study was supported by Medical Research Student grant, Norwegian University of Science and Technology, and the Norwegian National Advisory Unit for functional MRI.

The authors would like to thank Professor Lars Jacob Stovner for initiating HUNT MRI, and the Multimodal Imaging Laboratory at UCSD for help with the FreeSurfer processing.

References

Adams, M.M., Fink, S.E., Janssen, W.G., Shah, R.A., Morrison, J.H., 2004. Estrogen modulates synaptic N-methyl-D-aspartate receptor subunit distribution in the aged hippocampus. J. Comp. Neurol. 474, 419–426.

Apostolova, L.G., Dutton, R.A., Dinov, I.D., Hayashi, K.M., Toga, A.W., Cummings, J.L., Thompson, P.M., 2006. Conversion of mild cognitive impairment to Alzheimer disease predicted by hippocampal atrophy maps. Arch. Neurol. 63, 693–699.

Barouk, S., Hintz, T., Li, P., Duffy, A.M., Maclusky, N.J., Scharfman, H.E., 2011. 17β-estradiol increases astrocytic vascular endothelial growth factor (VEGF) in adult female rat hippocampus. Endocrinology 152, 1745–1751.

Bean, L.A., Ianov, L., Foster, T.C., 2014. Estrogen receptors, the Hippocampus, and memory. Neuroscientist 20, 534–545.

Braak, H., Braak, E., 1991. Neuropathological stageing of Alzheimer-related changes. Acta Neuropathol. 82, 239–259.

Buckner, R.L., Head, D., Parker, J., Fotenos, A.F., Marcus, D., Morris, J.C., Snyder, A.Z., 2004. A unified approach for morphometric and functional data analysis in young, old, and demented adults using automated atlas-based head size normalization: reliability and validation against manual measurement of total intracranial volume. Neuroimage 23, 724–738.

Cherbuin, N., Anstey, K.J., Réglade-Meslin, C., Sachdev, P.S., 2009. In vivo hippocampal measurement and memory: a comparison of manual tracing and automated segmentation in a large community-based sample. PLoS One 4, e5265.

Costafreda, S.G., Dinov, I.D., Tu, Z., Shi, Y., Liu, C.-Y., Kloszewska, I., Mecocci, P., Soininen, H., Tsolaki, M., Vellas, B., Wahlund, L.-O., Spenger, C., Toga, A.W., Lovestone, S., Simmons, A., 2011. Automated hippocampal shape analysis predicts the onset of dementia in mild cognitive impairment. Neuroimage 56, 212–219.

Csernansky, J.G., Wang, L., Swank, J., Miller, J.P., Gado, M., McKeel, D., Miller, M.I., Morris, J.C., 2005. Preclinical detection of Alzheimer's disease: hippocampal shape and volume predict dementia onset in the elderly. Neuroimage 25, 783–792.

de Flores, R., La Joie, R., Landeau, B., Perrotin, A., Mézenge, F., de La Sayette, V., Eustache, F., Desgranges, B., Chételat, G., 2015. Effects of age and Alzheimer's disease on hippocampal subfields. Hum. Brain Mapp. 36, 463–474.

Doring, T.M., Kubo, T.T.A., Cruz, L.C.H., Juruena, M.F., Fainberg, J., Domingues, R.C., Gasparetto, E.L., 2011. Evaluation of hippocampal volume based on MR imaging in patients with bipolar affective disorder applying manual and automatic segmentation techniques. J. Magn. Reson. Imaging 33, 565–572.

Duvernoy, H.M., 2005. The Human Hippocampus: Functional Anatomy, Vascularization and Serial Sections with MRI. Springer Science & Business Media, Berlin, Heidelberg.

Eberling, J., Wu, C., Haan, M., Mungas, D., Buonocore, M., Jagust, W., 2003. Preliminary evidence that estrogen protects against age-related hippocampal atrophy. Neurobiol. Aging 24, 725–732.

Eberling, J.L., Wu, C., Tong-Turnbeaugh, R., Jagust, W.J., 2004. Estrogen- and tamoxifen-associated effects on brain structure and function. Neuroimage 21, 364–371.

Epperson, C.N., Sammel, M.D., Freeman, E.W., 2013. Menopause effects on verbal memory: findings from a longitudinal community cohort. J. Clin. Endocrinol. Metab. 98, 3829–3838.

Erickson, K.I., Colcombe, S.J., Raz, N., Korol, D.L., Scalf, P., Webb, A., Cohen, N.J., McAuley, E., Kramer, A.F., 2005. Selective sparing of brain tissue in postmenopausal women receiving hormone replacement therapy. Neurobiol. Aging 26, 1205–1213.

Erickson, K.I., Voss, M.W., Prakash, R.S., Chaddock, L., Kramer, A.F., 2010. A cross-sectional study of hormone treatment and hippocampal volume in postmenopausal women: evidence for a limited window of opportunity. Neuropsychology 24, 68.

Espeland, M.A., Rapp, S.R., Shumaker, S.A., Brunner, R., Manson, J.E., Sherwin, B.B., Hsia, J., Margolis, K.L., Hogan, P.E., Wallace, R., 2004. Conjugated equine estrogens and global cognitive function in postmenopausal women: Women's Health Initiative Memory Study. JAMA 291, 2959–2968.

Espeland, M.A., Shumaker, S.A., Leng, I., Manson, J.E., Brown, C.M., LeBlanc, E.S., Vaughan, L., Robinson, J., Rapp, S.R., Goveas, J.S., Wactawski-Wende, J., Stefanick, M.L., Li, W., Resnick, S.M., WHIMSY Study Group, 2013. Long-term effects on cognitive function of postmenopausal hormone therapy prescribed to women aged 50 to 55 years. JAMA Intern. Med. 173, 1429–1436.

Fischer, B., Gleason, C., Asthana, S., 2014. Effects of hormone therapy on cognition and mood. Fertil. Steril. 101, 898–904.

Fischl, B., Salat, D.H., Busa, E., Albert, M., Dieterich, M., Haselgrove, C., van der Kouwe, A., Killiany, R., Kennedy, D., Klaveness, S., Montillo, A., Makris, N., Rosen, B., Dale, A.M., 2002. Whole brain segmentation: automated labeling of neuroanatomical structures in the human brain. Neuron 33, 341–355.

Foster, T.C., 2012. Role of estrogen receptor alpha and beta expression and signaling on cognitive function during aging. Hippocampus 22, 656–669.

Frisoni, G., Sabattoli, F., Lee, A., Dutton, R., Toga, A., Thompson, P., 2006. In vivo neuropathology of the hippocampal formation in AD: a radial mapping MR-based study. Neuroimage 32, 104–110.

Fromholdt, P., Berg, S., 1997. Self-reported memory and cognitive performance among 75-year old people from three Nordic Cities. In: Heikkinen, E., Berg, S., Schroll, M., Steen, B., Viidik, A. (Eds.), Functional Status, Health and Aging, The NORA Study (Series: Facts, Research and Intervention). Paris: Serdi Publishing Company, pp. 55–65.

Galea, L.A.M., Spritzer, M.D., Barker, J.M., Pawluski, J.L., 2006. Gonadal hormone modulation of hippocampal neurogenesis in the adult. Hippocampus 16, 225–232.

Gerardin, E., Chételat, G., Chupin, M., Cuingnet, R., Desgranges, B., Kim, H.S., Niethammer, M., Dubois, B., Lehéricy, S., Garnero, L., Eustache, F., Colliot, O., 2009. Multidimensional classification of hippocampal shape features discriminates Alzheimer's disease and mild cognitive impairment from normal aging. Neuroimage 47, 1476–1486.

Gibbs, R.B., 2000. Long-term treatment with estrogen and progesterone enhances acquisition of a spatial memory task by ovariectomized aged rats. Neurobiol. Aging 21, 107–116.

Gold, S.M., O'Connor, M.F., Gill, R., Kern, K.C., Shi, Y., Henry, R.G., Pelletier, D., Mohr, D.C., Sicotte, N.L., 2014. Detection of altered hippocampal morphology in multiple sclerosis-associated depression using automated surface mesh modeling. Hum. Brain Mapp. 35, 30–37.

Goodman, Y., Bruce, A.J., Cheng, B., Mattson, M.P., 1996. Estrogens attenuate and corticosterone exacerbates excitotoxicity, oxidative injury, and amyloid β-peptide toxicity in hippocampal neurons. J. Neurochem. 66, 1836–1844.

Grady, D., Yaffe, K., Kristof, M., Lin, F., Richards, C., Barrett-Connor, E., 2002. Effect of postmenopausal hormone therapy on cognitive function: the Heart and Estrogen/progestin Replacement Study. Am. J. Med. 113, 543–548.

Greenberg, D.L., Payne, M.E., MacFall, J.R., Provenzale, J.M., Steffens, D.C., Krishnan, R.R., 2006. Differences in brain volumes among males and female hormone-therapy users and nonusers. Psychiatry Res. 147, 127–134.

Hackert, V.H., den Heijer, T., Oudkerk, M., Koudstaal, P.J., Hofman, A., Breteler, M.M.B., 2002. Hippocampal head size associated with verbal memory performance in nondemented elderly. Neuroimage 17, 1365–1372.

Hansen, T., Brezova, V., Eikenes, L., Håberg, A., Vangberg, T., 2015. How does the accuracy of intracranial volume measurements affect normalized brain volumes? sample size estimates based on 966 subjects from the HUNT MRI cohort. AJNR Am J Neuroradiol.

Hoaglin, D.C., Iglewicz, B., 1987. Fine-tuning some resistant rules for outlier labeling. J. Am. Stat. Assoc. 82, 1147–1149.

Hogervorst, E., Bandelow, S., 2010. Sex steroids to maintain cognitive function in women after the menopause: a meta-analyses of treatment trials. Maturitas 66, 56–71.

Holmen, J., Langballe, E.M., Midthjell, K., Holmen, T.L., Fikseaunet, A., Saltvedt, I., Tambs, K., 2013. Gender differences in subjective memory impairment in a general population: the HUNT study, Norway. BMC Psychol. 1, 19.

Honningsvag, L., Linde, M., Haberg, A., Stovner, L., Hagen, K., 2012. Does health differ between participants and non-participants in the MRI-HUNT study, a population based neuroimaging study? the Nord-Trøndelag health studies 1984-2009. BMC Med. Imaging 12, 23.

Hyman, B.T., Van Hoesen, G.W., Damasio, A.R., Barnes, C.L., 1984. Alzheimer's disease: cell-specific pathology isolates the hippocampal formation. Science 225, 1168–1170.

Jiang, J., Sachdev, P., Lipnicki, D.M., Zhang, H., Liu, T., Zhu, W., Suo, C., Zhuang, L., Crawford, J., Reppermund, S., 2014. A longitudinal study of brain atrophy over two years in community-dwelling older individuals. Neuroimage 86, 203–211.

Kawas, C., Resnick, S., Morrison, A., Brookmeyer, R., Corrada, M., Zonderman, A., Bacal, C., Donnell Lingle, D., Metter, E., 1997. A prospective study of estrogen replacement therapy and the risk of developing Alzheimer's disease: the Baltimore Longitudinal Study of Aging. Neurology 48, 1517–1521.

Keihaninejad, S., Heckemann, R.A., Fagiolo, G., Symms, M.R., Hajnal, J.V., Hammers, A., 2010. A robust method to estimate the intracranial volume across MRI field strengths (1.5T and 3T). NeuroImage 50, 1427–1437.

Kril, J.J., Hodges, J., Halliday, G., 2004. Relationship between hippocampal volume and CA1 neuron loss in brains of humans with and without Alzheimer's disease. Neurosci. Lett. 361, 9–12.

Krokstad, S., Langhammer, A., Hveem, K., Holmen, T.L., Midthjell, K., Stene, T.R., Bratberg, G., Heggland, J., Holmen, J., 2013. Cohort profile: the HUNT study, Norway. Int. J. Epidemiol. 42, 968–977.

Langhammer, A., Krokstad, S., Romundstad, P., Heggland, J., Holmen, J., 2012. The HUNT study: participation is associated with survival and depends on socioeconomic status, diseases and symptoms. BMC Med. Res. Methodol. 12, 143.

Lim, H.K., Hong, S.C., Jung, W.S., Ahn, K.J., Won, W.Y., Hahn, C., Kim, I.S., Lee, C.U., 2012a. Hippocampal shape and cognitive performance in amnestic mild cognitive impairment. Neuroreport 23, 364–368.

Lim, H.K., Jung, W.S., Ahn, K.J., Won, W.Y., Hahn, C., Lee, S.Y., Kim, I., Lee, C.U., 2012b. Relationships between hippocampal shape and cognitive performances in drug-naïve patients with Alzheimer's disease. Neurosci. Lett. 516, 124–129.

Lord, C., Buss, C., Lupien, S.J., Pruessner, J.C., 2008. Hippocampal volumes are larger in postmenopausal women using estrogen therapy compared to past users, never users and men: a possible window of opportunity effect. Neurobiol. Aging 29, 95–101.

Low, L.F., Anstey, K.J., Maller, J., Kumar, R., Wen, W., Lux, O., Salonikas, C., Naidoo, D., Sachdev, P., 2006. Hormone replacement therapy, brain volumes and white matter in postmenopausal women aged 60-64 years. Neuroreport 17, 101–104.

Luine, V.N., Richards, S.T., Wu, V.Y., Beck, K.D., 1998. Estradiol enhances learning and memory in a spatial memory task and effects levels of monoaminergic neurotransmitters. Horm. Behav. 34, 149–162.

Maki, P.M., Henderson, V.W., 2012. Hormone therapy, dementia, and cognition: the Women's Health Initiative 10 years on. Climacteric 15, 256–262.

Mann, C., 2003. Observational research methods. Research design II: cohort, cross sectional, and case-control studies. Emerg. Med. J. 20, 54–60.
Marder, K., Sano, M., 2000. Estrogen to treat Alzheimer's disease: too little, too late? So what'sa woman to do? Neurology 54, 2035–2037.
Mehra, R.D., Sharma, K., Nyakas, C., Vij, U., 2005. Estrogen receptor α and β immunoreactive neurons in normal adult and aged female rat hippocampus: a qualitative and quantitative study. Brain Res. 1056, 22–35.
Menke, R.A., Szewczyk-Krolikowski, K., Jbabdi, S., Jenkinson, M., Talbot, K., Mackay, C.E., Hu, M., 2014. Comprehensive morphometry of subcortical grey matter structures in early-stage Parkinson's disease. Hum. Brain Mapp. 35, 1681–1690.
Miskowiak, K.W., Vinberg, M., Macoveanu, J., Ehrenreich, H., Koster, N., Inkster, B., Paulson, O.B., Kessing, L.V., Skimminge, A., Siebner, H.R., 2014. Effects of erythropoietin on hippocampal volume and memory in mood disorders. Biol. Psychiatry. http://dx.doi.org/10.1016/j.biopsych.2014.12.013.
Morey, R.A., Petty, C.M., Xu, Y., Hayes, J.P., Wagner, H.R., Lewis, D.V., LaBar, K.S., Styner, M., McCarthy, G., 2009. A comparison of automated segmentation and manual tracing for quantifying hippocampal and amygdala volumes. Neuroimage 45, 855–866.
Mulder, E.R., de Jong, R.A., Knol, D.L., van Schijndel, R.A., Cover, K.S., Visser, P.J., Barkhof, F., Vrenken, H., 2014. Hippocampal volume change measurement: quantitative assessment of the reproducibility of expert manual outlining and the automated methods FreeSurfer and FIRST. Neuroimage 92, 169–181.
Mumoli, L., Labate, A., Vasta, R., Cherubini, A., Ferlazzo, E., Aguglia, U., Quattrone, A., Gambardella, A., 2013. Detection of hippocampal atrophy in patients with temporal lobe epilepsy: a 3-Tesla MRI shape. Epilepsy Behav. 28, 489–493.
O'Driscoll, G.A., Florencio, P.S., Gagnon, D., Wolff, A.-L.V., Benkelfat, C., Mikula, L., Lal, S., Evans, A.C., 2001. Amygdala–hippocampal volume and verbal memory in first-degree relatives of schizophrenic patients. Psychiatry Res. 107, 75–85.
Packard, M.G., Teather, L.A., 1997. Intra-hippocampal estradiol infusion enhances memory in ovariectomized rats. Neuroreport 8, 3009–3013.
Patenaude, B., Smith, S.M., Kennedy, D.N., Jenkinson, M., 2011. A Bayesian model of shape and appearance for subcortical brain segmentation. Neuroimage 56, 907–922.
Persson, J., Spreng, R.N., Turner, G., Herlitz, A., Morell, A., Stening, E., Wahlund, L.-O., Wikström, J., Söderlund, H., 2014. Sex differences in volume and structural covariance of the anterior and posterior hippocampus. Neuroimage 99, 215–225.
Pike, C.J., Carroll, J.C., Rosario, E.R., Barron, A.M., 2009. Protective actions of sex steroid hormones in Alzheimer's disease. Front. Neuroendocrinol. 30, 239–258.
Rapp, S.R., Espeland, M.A., Shumaker, S.A., Henderson, V.W., Brunner, R.L., Manson, J.E., Gass, M.L., Stefanick, M.L., Lane, D.S., Hays, J., 2003. Effect of estrogen plus progestin on global cognitive function in postmenopausal women: the Women's Health Initiative Memory Study: a randomized controlled trial. JAMA 289, 2663–2672.
Raz, N., Gunning-Dixon, F., Head, D., Rodrigue, K.M., Williamson, A., Acker, J.D., 2004. Aging, sexual dimorphism, and hemispheric asymmetry of the cerebral cortex: replicability of regional differences in volume. Neurobiol. Aging 25, 377–396.
Resnick, S.M., Espeland, M.A., Jaramillo, S.A., Hirsch, C., Stefanick, M.L., Murray, A.M., Ockene, J., Davatzikos, C., 2009. Postmenopausal hormone therapy and regional brain volumes: the WHIMS-MRI Study. Neurology 72, 135–142.
Resnick, S.M., Henderson, V.W., 2002. Hormone therapy and risk of Alzheimer disease: a critical time. JAMA 288, 2170–2172.
Satterthwaite, T.D., Vandekar, S., Wolf, D.H., Ruparel, K., Roalf, D.R., Jackson, C., Elliott, M.A., Bilker, W.B., Calkins, M.E., Prabhakaran, K., 2014. Sex differences in the effect of puberty on hippocampal morphology. J. Am. Acad. Child Adolesc. Psychiatry 53, 341–350 e1.
Seidl, U., Traeger, T.V., Hirjak, D., Remmele, B., Wolf, R.C., Kaiser, E., Stieltjes, B., Essig, M., Schröder, J., Thomann, P.A., 2012. Subcortical morphological correlates of impaired clock drawing performance. Neurosci. Lett. 512, 28–32.
Shao, H., Breitner, J.C.S., Whitmer, R.A., Wang, J., Hayden, K., Wengreen, H., Corcoran, C., Tschanz, J., Norton, M., Munger, R., Welsh-Bohmer, K., Zandi, P.P., 2012. Hormone therapy and Alzheimer disease dementia: new findings from the Cache County Study. Neurology 79, 1846–1852.
Shen, L., Saykin, A., Kim, S., Firpi, H., West, J., Risacher, S., McDonald, B., McHugh, T., Wishart, H., Flashman, L., 2010. Comparison of manual and automated determination of hippocampal volumes in MCI and early AD. Brain Imaging Behav. 4, 86–95.
Shi, F., Liu, B., Zhou, Y., Yu, C., Jiang, T., 2009. Hippocampal volume and asymmetry in mild cognitive impairment and Alzheimer's disease: meta-analyses of MRI studies. Hippocampus 19, 1055–1064.
Shumaker, S.A., Legault, C., Rapp, S.R., Thal, L., Wallace, R.B., Ockene, J.K., Hendrix, S.L., Jones 3rd, B.N., Assaf, A.R., Jackson, R.D., Kotchen, J.M., Wassertheil-Smoller, S., Wactawski-Wende, J., WHIMS Investigators, 2003. Estrogen plus progestin and the incidence of dementia and mild cognitive impairment in postmenopausal women: the women's health initiative memory study: a randomized controlled trial. JAMA 289, 2651–2662.
Smith, S.M., Jenkinson, M., Woolrich, M.W., Beckmann, C.F., Behrens, T.E.J., Johansen-Berg, H., Bannister, P.R., De Luca, M., Drobnjak, I., Flitney, D.E., Niazy, R.K., Saunders, J., Vickers, J., Zhang, Y., De Stefano, N., Brady, J.M., Matthews, P.M., 2004. Advances in functional and structural MR image analysis and implementation as FSL. Neuroimage 23 (Suppl. 1), S208–S219.
Squire, L.R., 1992. Memory and the hippocampus: a synthesis from findings with rats, monkeys, and humans. Psychol. Rev. 99, 195–231.
Stovner, L., Al Jumah, M., Birbeck, G., Gururaj, G., Jensen, R., Katsarava, Z., Queiroz, L., Scher, A., Tekle-Haimanot, R., Wang, S.-J., Steiner, T., 2014. The methodology of population surveys of headache prevalence, burden and cost: principles and recommendations from the Global Campaign against Headache. J. Headache Pain 15, 1–30.
Tang, M.-X., Jacobs, D., Stern, Y., Marder, K., Schofield, P., Gurland, B., Andrews, H., Mayeux, R., 1996. Effect of oestrogen during menopause on risk and age at onset of Alzheimer's disease. Lancet 348, 429–432.
Thomann, P.A., Wüstenberg, T., Nolte, H.M., Menzel, P.B., Wolf, R.C., Essig, M., Schröder, J., 2013. Hippocampal and entorhinal cortex volume decline in cognitively intact elderly. Psychiatry Res. Neuroimaging 211, 31–36.
Van Hoesen, G.W., Hyman, B.T., 1990. Hippocampal formation: anatomy and the patterns of pathology in Alzheimer's disease. Prog. Brain Res. 83, 445–457.
Voevodskaya, O., Simmons, A., Nordenskjöld, R., Kullberg, J., Ahlström, H., Lind, L., Wahlund, L.-O., Larsson, E.-M., Westman, E., Alzheimer's Disease Neuroimaging Initiative, 2014. The effects of intracranial volume adjustment approaches on multiple regional MRI volumes in healthy aging and Alzheimer's disease. Front. Aging Neurosci. 6, 264.
Walterfang, M., Patenaude, B., Abel, L., Kluenemann, H., Bowman, E., Fahey, M., Desmond, P., Kelso, W., Velakoulis, D., 2013. Subcortical volumetric reductions in adult Niemann-Pick disease type C: a cross-sectional study. AJNR Am J Neuroradiol. 34, 1334–1340.
Wenger, E., Mårtensson, J., Noack, H., Bodammer, N.C., Kühn, S., Schaefer, S., Heinze, H.-J., Düzel, E., Bäckman, L., Lindenberger, U., Lövdén, M., 2014. Comparing manual and automatic segmentation of hippocampal volumes: reliability and validity issues in younger and older brains. Hum. Brain Mapp. 35, 4236–4248.
West, M.J., Gundersen, H., 1990. Unbiased stereological estimation of the number of neurons in the human hippocampus. J. Comp. Neurol. 296, 1–22.
Whitmer, R.A., Quesenberry, C.P., Zhou, J., Yaffe, K., 2011. Timing of hormone therapy and dementia: the critical window theory revisited. Ann. Neurol. 69, 163–169.
Winkler, A.M., Ridgway, G.R., Webster, M.A., Smith, S.M., Nichols, T.E., 2014. Permutation inference for the general linear model. Neuroimage 92, 381–397.
Wisse, L.E.M., Biessels, G.J., Geerlings, M.I., 2014. A critical appraisal of the hippocampal subfield segmentation package in FreeSurfer. Front. Aging Neurosci. 6, 261.
Wnuk, A., Korol, D.L., Erickson, K.I., 2012. Estrogens, hormone therapy, and hippocampal volume in postmenopausal women. Maturitas 73, 186–190.
Woolley, C.S., McEwen, B.S., 1992. Estradiol mediates fluctuation in hippocampal synapse density during the estrous cycle in the adult rat. J. Neurosci. 12, 2549–2554.
Yao, M., Nguyen, T.V.V., Pike, C.J., 2007. Estrogen regulates Bcl-w and Bim expression: role in protection against β-amyloid peptide-induced neuronal death. J. Neurosci. 27, 1422–1433.
Zandi, P.P., Carlson, M.C., Plassman, B.L., Welsh-Bohmer, K.A., Mayer, L.S., Steffens, D.C., Breitner, J.C., Investigators, C.C.M.S, 2002. Hormone replacement therapy and incidence of Alzheimer disease in older women: the Cache County Study. JAMA 288, 2123–2129.