



Correlation between prenatal ultrasound and postmortem findings in 1029 fetuses following termination of pregnancy

Journal:	<i>Ultrasound in Obstetrics and Gynecology</i>
Manuscript ID	UOG-2015-0401.R1
Wiley - Manuscript type:	Original Article
Date Submitted by the Author:	20-Aug-2015
Complete List of Authors:	Struksnæs, Camilla; Faculty of Medicine, Norwegian University of Science and Technology (NTNU), Department of Laboratory Medicine, Children's and Women's Health Blaas, Harm-Gerd Karl; St. Olavs Hospital, National Center for Fetal Medicine Eik-Nes, Sturla; St. Olavs Hospital, National Center for Fetal Medicine; Norwegian University of Science and Technology (NTNU), Department of Laboratory Medicine, Children's and Women's Health Vogt, Christina; St. Olavs Hospital, Department of Pathology and Medical Genetics; Norwegian University of Science and Technology (NTNU), Department of Laboratory Medicine, Children's and Women's Health
Manuscript Categories:	Obstetrics
Keywords:	congenital anomalies , ultrasonography, TOP, autopsy

SCHOLARONE™
Manuscripts

Correlation between prenatal ultrasound and postmortem findings in 1029 fetuses following termination of pregnancy

C. Struksnæs¹, H-G. K. Blaas¹⁻², S.H. Eik-Nes¹⁻², C. Vogt^{1,3}

¹ Department of Laboratory Medicine, Children's and Women's Health, Norwegian University of Science and Technology (NTNU), Trondheim

² National Center for Fetal Medicine, Department of Obstetrics and Gynecology, St. Olavs Hospital, Trondheim University Hospital, Trondheim, Norway

³ Department of Pathology and Medical Genetics, St. Olavs Hospital, Trondheim University Hospital, Trondheim, Norway

Key words: congenital anomalies, ultrasonography, TOP, autopsy

Short title: Ultrasound and autopsy

Corresponding author:

Camilla Struksnæs

Medical Research Student

Faculty of Medicine, Norwegian University of Science and Technology (NTNU)

Institute of Laboratory Medicine, Children's and Women's Health

N-7006 Trondheim

Mobile: +47 93837330

ABSTRACT

Objectives

A prenatal ultrasound examination together with a postmortem examination provide the basis for correct diagnosis in fetuses terminated due to congenital anomalies. The aim of this study is to correlate fetal anomalies detected by ultrasound examination with autopsy findings following termination of pregnancy (TOP) over a 30-year period, and to evaluate the correlation rate at different gestational ages.

Methods

The study group consists of **1029 TOPs carried out over a 30-year period from 1985 to 2014**. The gestational age spans between 11 and 33 weeks. The ultrasound examinations were performed at the National Center for Fetal Medicine (NCFM), St. Olavs Hospital, Trondheim. **The autopsies were performed at the Department of Pathology and Medical Genetics at the same hospital or a collaborating hospital.**

Results

There was full agreement between ultrasound and autopsy findings in 88.1% (907/1029) of the TOPs, and the main diagnosis was correct in 97.8% (1007/1029). When comparing the 15-year period 2000-2014 with the previous period, 1985-1999, the differences in detection rate were statistically significant for full agreement and for main diagnosis. In 1.3% (13/1029) of the cases, the US findings were not confirmed at autopsy. There were no false-positive diagnoses leading to TOP. Throughout the 30-year period, there was an increase in early TOPs, while late TOPs have declined.

1
2
3
4 Conclusions

5
6 Our study demonstrates that there is a clear correlation between ultrasound and autopsy
7
8 findings; this correlation is continuously improving. In spite of this high correlation,
9
10 there is reason to continue the practice of validation to ensure the safety of the
11
12 diagnostic process leading to termination of pregnancy. The trend towards performing
13
14 earlier termination emphasises the necessity of such a practice.
15
16
17
18
19
20
21
22
23
24
25
26
27
28
29
30
31
32
33
34
35
36
37
38
39
40
41
42
43
44
45
46
47
48
49
50
51
52
53
54
55
56
57
58
59
60

For Peer Review

INTRODUCTION

A prenatal ultrasound examination and a conscientious postmortem examination provide the basis for correct diagnosis in fetuses terminated due to congenital anomalies (1,2). The risk of false-positive diagnoses with congenital anomalies is a major concern in prenatal diagnostics, in particular where termination of pregnancy (TOP) might be an option. The verification of ultrasound findings is important for the involved parents, for genetic counseling, for the obstetrician and for epidemiological analysis (3-15).

The Norwegian routine second trimester ultrasound (US) scan at 17-18 gestational weeks includes a survey of the fetal anatomy (16-18). Detection rates of the different congenital anomalies vary from 44 % to 86% depending on the type of anomaly (7,8,12,19-23). Some structural anomalies of the conceptus can be sonographically detected as early as during the embryonic period at 7 to 8 weeks of gestational age based on the last menstrual period. A scan at the end of the first trimester at 11-13 weeks, can detect numerous types of anomalies (24).

Throughout the years of ultrasound diagnostics, detection by ultrasound has improved, especially due to increasing expertise of the ultrasonographers and higher quality of the ultrasound equipment (25). However, ultrasound diagnostics of congenital anomalies at earlier gestational age and the presence of more subtle conditions challenge the verification of congenital anomalies and require other pre- and postmortem examination methods (26).

1
2
3
4 This study is a quality control on TOPs carried out as a consequence of sonographically
5 diagnosed fetal anomalies. The aim is to correlate fetal anomalies detected by
6 ultrasound examination with autopsy following termination of pregnancy (TOP)
7 throughout a 30-year period, and to evaluate the correlation rate at different gestational
8 ages.
9
10
11
12
13
14
15
16

17 **METHODS**

18
19 The study is a collaboration between the National Center for Fetal Medicine (NCFM),
20 which functions as a referral center for pregnant women from all over Norway, and the
21 Department of Pathology and Medical Genetics at St. Olavs Hospital, University
22 Hospital of Trondheim. The study includes cases from the non-selected area and cases
23 referred from the rest of the country. Criteria for inclusion in the study were a prenatal
24 ultrasound examination performed at the NCFM, diagnosis of an anomaly that led to
25 termination of pregnancy between gestational weeks 11 and 33 **following approval by**
26 **an abortion committee**, and an autopsy performed at the Department of Pathology at
27 St. Olav's Hospital or a collaborating hospital.
28
29
30
31
32
33
34
35
36
37
38
39
40
41

42 According to Norwegian law from 1975 with later revisions, a fetus considered viable
43 outside the mother's womb can not be terminated (27). The limit for viability was
44 initially assumed to be approximately 23+6 weeks until the nineties and later gradually
45 restricted. Since 2001, the upper limit for termination of a viable fetus is 21+6 weeks. A
46 fetus with a lethal condition may be terminated later in pregnancy. **A total of 1029**
47 **terminated fetuses fulfilled the inclusion criteria during a 30-year period from**
48 **1985 to 2014.**
49
50
51
52
53
54
55
56
57
58
59
60

1
2
3
4 **All cases were over time prospectively registered in a database at the NCFM and**
5 **continuously validated. The database includes several variables such as maternal**
6 **age, obstetric history and results of fetal invasive procedures. After autopsy, organ**
7 **anomalies were registered and categorized. When multiple anomalies were**
8 **present, the lethal anomaly or the anomaly considered as the most serious was**
9 **chosen as the “primary diagnosis”, while the others were classified as “secondary**
10 **diagnoses” (2). The final diagnosis at the last ultrasound examination and the autopsy**
11 **findings were documented. In Norway, pregnancy length and expected day of**
12 **delivery are determined at the 17-18 week routine scan by measurement of**
13 **biparietal diameter (BPD) and femur length (FL). In early pregnancies, BPD or**
14 **crown-rump length (CRL) is used (28). In cases where the anomaly affected fetal**
15 **size, gestational age was based on the best estimate of clinical data. The**
16 **termination of pregnancy was performed as soon as possible, preferably the day**
17 **after the decision for termination was made. In cases where anomalies were**
18 **detected as early as week 9 to 10, the termination of pregnancy was delayed 2-3**
19 **weeks to enable a proper postmortem assessment.**
20
21
22
23
24
25
26
27
28
29
30
31
32
33
34
35
36
37
38
39
40
41
42
43
44
45
46
47
48
49
50
51
52
53
54
55
56
57
58
59
60

Fetal medicine experts were responsible for most of the ultrasound examinations at NCFM. Between the years 1985 to 1990 and 2005 to 2014, doctors in training, supervised by a senior pathologist, performed the autopsies. Between the years 1991 to 2004, two consultant pathologists with experience in perinatal pathology were responsible for all the autopsies. From 1990, a standardized autopsy protocol was followed, which included full body radiology and photographic documentation. All organs were examined, including in situ examination of the heart and removal of the

1
2
3
4 brain under water in order to minimize trauma. **Ultrasound reports were available to**
5
6 **the pathologist at the postmortem examination.**
7
8

9
10
11 Correlations between US findings and autopsy were categorized, in accordance with a
12
13 modification of the method described by Isaksen et al. (20).
14
15

- 16
17 1. Full agreement between ultrasound and autopsy findings
- 18
19 2. Minor autopsy findings not seen or recorded at ultrasound examination
- 20
21 3. Major autopsy findings not detected at ultrasound examination
- 22
23 4. None of the autopsy findings suspected at ultrasound examination
- 24
25 5. Ultrasound findings not confirmed or not possible to confirm at autopsy
- 26
27
28
29

30
31 We used **SPSS 21.0** (SPSS Inc., Chicago, Ill., USA) in the statistical analysis, and
32
33 correlation analyses were performed using Independent samples t-test. $P < 0.05$ was
34
35 considered statically significant.
36

37 The study was approved by the Regional Ethics Committee (REC).
38
39
40

41 **RESULTS**

42
43
44 All 1029 fetuses underwent autopsy following termination of pregnancy between weeks
45
46 11 and 33. The mean maternal age was 29.2 years (range 16-45 years). The median
47
48 gestational age was week 19.0 (range 11-33). The gender differentiation included 51.4%
49
50 females (529/1029) and 48.4% males (498/1029). It was not possible to determine the
51
52 gender in two cases.
53
54
55
56
57
58
59
60

1
2
3
4 Table 1 shows an overview of congenital anomalies among 1029 autopsies of fetuses
5 terminated between weeks 11 and 33. The dominating primary diagnoses were CNS
6 anomalies (34.4%, 354/1029), followed by cardiovascular system anomalies (18.2%,
7 187/1029), urinary system anomalies (13.1%, 135/1029) and fetal hydrops/cystic
8 hygroma (9.4%, 97/1029). In addition to the primary diagnosis leading to termination of
9 pregnancy, 46.1 % (474/1029) of all fetuses had a secondary diagnosis. In this study,
10 34/1029 (3.3%) cases with normal morphology were terminated due to chromosome
11 anomalies. Table 2 gives an overview of the karyotype of the terminated pregnancies.
12 The karyotype was normal in 59.5% of the cases, unknown among 10.1%. Thirty
13 percent (313/1029) of all cases had an abnormal karyotype. Trisomy 18 was the most
14 common abnormal karyotype (8.7%, 90/1029), thereafter trisomy 21 (8.3%, 85/1029).

15
16
17
18
19
20
21
22
23
24
25
26
27
28
29
30
31 Table 3 demonstrates the distribution of primary diagnoses among 1029 terminated
32 fetuses: 13.7 % (141/1029) of the fetuses were terminated between weeks 11+0 to 15+6
33 (early TOP), 79.0% (813/1029) between weeks 16+0 to 21+6 (intermediate TOP) and
34 7.3% (75/1029) between weeks 22+0 to 33+6 (late TOP). The rate of congenital
35 anomalies at different gestational ages was almost constant for cardiovascular system
36 anomalies (17.7% - 18.3% - 17.3%) and CNS anomalies (31.9% - 34.7% - 36.0%), but
37 the rate of fetal hydrops and cystic hygroma declined with increasing gestational age
38 (14.2% - 9.2% - 2.7%). Figure 1 shows the rate of terminations in weeks 11+0 to 15+6,
39 weeks 16+0 to 21+6 and weeks 22+0 to 33+6, over five-year periods between 1985 and
40 2014 for 1029 fetuses. There is an increase in the number of early TOPs, while the
41 number of late TOPs decreases throughout the 30-year period (Figure 1).

42
43
44
45
46
47
48
49
50
51
52
53
54
55
56
57
58
59
60

1
2
3
4 Table 4 describes the correlation between prenatal ultrasound findings and autopsy
5 findings in 1029 terminated fetuses between 1985 and 2014. In the total study group
6 between week 11 and 33, there was full agreement between ultrasound and autopsy
7 findings in 88.1% (907/1029), and the main diagnosis was correct in 97.8%
8 (1007/1029). When comparing the 15-year period 2000-2014 with the previous period
9 1985-1999, the differences in detection rate were statistically significant, with $p=0.003$
10 for full agreement and $p=0.008$ for main diagnosis. By differentiating the groups by
11 gestational age, we found full agreement in the three groups in 86.5% (weeks 11+0 to
12 15+6), 88.8% (weeks 16+0 to 21+6) and 84.0% (weeks 22+0 to 33+6), respectively.
13
14 However, there were non-significant differences in the correlation rate for full
15 agreement ($p=0.43$) and main diagnosis ($p=0.66$) between first gestational group (weeks
16 11+0 to 15+6) and second gestational group (weeks 16+0 to 21+6). Further, minor and
17 major autopsy findings not detected at ultrasound, constituted 9.7% (100/1029) and
18 0.9% (9/1029) respectively, of the total material. There were no cases in category 4. In
19 1.3% (13/1029) of the pregnancies, ultrasound findings other than those leading to
20 termination, were not confirmed at autopsy. There were no false-positive diagnoses
21 leading to TOP throughout the 30-year period.
22
23
24
25
26
27
28
29
30
31
32
33
34
35
36
37
38
39
40
41
42
43

44 Table 5 demonstrates the correlation between prenatal ultrasound examination and
45 autopsy findings according to primary diagnosis in 1029 terminated fetuses between
46 1985 and 2014. **The correlation rates for full agreement were high among skeletal**
47 **dysplasia (92.5%, 62/67), CNS anomalies (90.1%, 319/354) and urinary system**
48 **anomalies (87.4%, 118/135) and slightly lower for cardiovascular system anomalies**
49 **(83.4%, 156/187), but significantly lower ($p = 0.01$) for diaphragmatic/abdominal**
50
51
52
53
54
55
56
57
58
59
60

1
2
3
4 **wall defects (76.4%, 42/55) (Category 1, Table 5).** Figure 2 demonstrates the number
5
6 of TOPs in each correlation category grouped in five-year periods throughout the 30-
7
8 year period. Table 6 describes the cases in category 3, major autopsy findings not
9
10 detected at prenatal ultrasound, among 9 terminated fetuses. The discrepant findings in
11
12 this category involve particularly CNS anomalies (occipital myelocele), cardiovascular
13
14 anomalies (VSD) and urinary system anomalies (renal agenesis and cystic dysplastic
15
16 kidneys). Moreover, in case number 3, limb-body-wall complex was interpreted as a
17
18 large gastroschisis at US.
19
20
21
22
23

24 Table 7 shows all TOPs with ultrasound findings not confirmed or not possible to
25
26 confirm at autopsy among 13 terminated fetuses. **In cases 2, 3 and 5, the ultrasound**
27
28 **findings were not possible to confirm at autopsy due to maceration or**
29
30 **traumatization of the fetus. In all 13 cases, the unconfirmed findings did not affect**
31
32 **the termination decision since there were other serious findings present.** The
33
34 discrepant findings in CNS (nr. 1-3) include **Dandy-Walker anomaly** and
35
36 hydrocephaly. The discrepant findings in the cardiovascular system (nr. 4-8) are
37
38 atrioventricular septal defect (AVSD), ventricular septal defect (VSD), double outlet
39
40 right ventricle and overriding aorta. The discrepant findings in the urinary system (nr. 9-
41
42 12) are cystic dysplastic kidneys. In case number 13, sonographic findings of dwarfism
43
44 were confirmed at autopsy. Finally, cases with hydrops and cystic hygroma at
45
46 ultrasound were not always possible to confirm at autopsy due to desiccation and they
47
48 were not included as discrepant.
49
50
51
52
53
54
55
56
57
58
59
60

DISCUSSION

Seen over the 30-year period, there was full agreement between ultrasound and autopsy findings in 88.1% (907/1029), and the main diagnosis was correct in 97.8% (1007/1029) (Table 4). In 1.3% (13/1029) of the cases, the US findings were not confirmed at autopsy. The present validation showed that none of the terminated pregnancies were based on an ultrasound finding which retrospectively turned out to be a false positive diagnosis. Considering the extensive use of ultrasound in prenatal diagnosis and the serious consequences the diagnosis may have, this particular finding represents the most important basis for continuing to rely on ultrasound diagnosis in the diagnostic evaluation of the fetus. This validation also demonstrates the progress in the diagnostic development that has taken place over 30 years (25,29). Since 1985, the routine ultrasound examination has been the most important tool to assess the fetal anatomy. Interestingly, figure 1 shows that the gradual reduction in the relatively late diagnosis of anomalies has been paralleled with a similar increase in anomaly detection during weeks 11-14.

Figure 2 shows a gradual increase in the rate of full agreement between ultrasound examination and autopsy (category 1) over five-year intervals during the 30-year period. There were significant differences in the full agreement and main diagnosis when comparing the 15-year period 2000-2014 with the previous period 1985-1999. **Skeletal dysplasia and CNS anomalies had high correlation rates, while correlation rate in diaphragmatic/abdominal wall defects was significantly lower than average in the present study (88.1%, Table 4). However, the correlation rates for full agreement improved throughout the study period for both diaphragmatic and abdominal wall**

1
2
3
4 **defects.** Throughout the 30-year period, a small group of fetal medicine experts have
5
6 been responsible for most of the ultrasound examinations at the center. As other studies
7
8 state, US examinations performed at tertiary centers turn out to be more accurate than
9
10 examinations performed in non-specialized departments (3,4,8,10,30). **Additionally,**
11
12 **our policy has been to search for all anomalies present, also in cases where a**
13
14 **dominant serious finding leads to the decision to terminate a pregnancy.**
15
16
17

18
19 Many studies have documented discrepancies between ultrasound and autopsy findings
20
21 (2-15,30,40-43). **Table 8 shows 10 studies addressing TOP during the last decade**
22
23 **(2006-2015). In category 1, there is a range between 44.0-88.1% (mean 58.2, 95%**
24
25 **CI: 46.6, 69.8). The studies previous to our study are relatively small; they present**
26
27 **an average of 146 terminations, range 52 to 378. Based on the evaluation of the full**
28
29 **agreement cases (category 1) and the additional findings by autopsy (categories 2**
30
31 **and 3) for the ten series, it seems that the higher proportion of full agreement in**
32
33 **the present study and Rodriguez' study might be due to a better detection of minor**
34
35 **anomalies, e.g. small VSD, horseshoe kidney, clubfoot, and polydactyly.**
36
37
38
39

40
41
42 **In category 5, there is a range between 0-17.0% (mean 8.9, 95% CI: 5.4,12.4)**
43
44 **(Table 8). We have distinguished between whether or not the unconfirmed findings**
45
46 **at autopsy implied wrong management of the pregnancy. In 10/13 cases (1.0%) in**
47
48 **our study, other major findings were confirmed by autopsy (Table 7, Table 8 *),**
49
50 **while in 3/13 (0.3%) cases, confirmation of the prenatal diagnosis was not possible**
51
52 **due to fetal maceration (Table 7, Table 8 †). However, in all 13 cases, the**
53
54 **confirmation of other serious findings indicated that the pregnancy was not**
55
56
57
58
59
60

1
2
3
4 **mismanaged.** The unconfirmed findings involved especially CNS anomalies,
5
6 cardiovascular system anomalies and renal anomalies (Table 7). Concerning CNS,
7
8 **ventriculomegaly and small post posterior fossa abnormalities such as Dandy-**
9
10 **Walker anomaly can collapse during autopsy and therefore be difficult to verify**
11
12 **(31, 32). Imaging methods such as postmortem magnetic resonance imaging (MRI)**
13
14 **may better verify the findings (33,34).** Traditionally, anomalies in the cardiovascular
15
16 system, e.g. **small VSDs**, are more difficult to examine by ultrasound, but the detection
17
18 rate improves when a specialist in fetal echocardiography performs the heart
19
20 examination (35-37). Further, renal anomalies often cause difficulties because of
21
22 oligohydramnios (38,39).
23
24
25
26
27

28
29 There are limitations concerning both ultrasound and autopsy and therefore they are
30
31 often considered as complementary techniques. Both methods are dependent on the
32
33 skills and knowledge of the sonographer and pathologist. Factors such as fetal position,
34
35 gestational age, amount of amniotic fluid and maternal obesity, influence visualization
36
37 during ultrasound examination (44,45). Ultrasound reports were available to the
38
39 pathologist at the postmortem examination and might introduce bias in the evaluation of
40
41 autopsy findings (9). Fetal maceration is a factor that may hinder the accuracy of the
42
43 autopsy, especially autolysis of the brain.
44
45
46
47

48 **Improvement of ultrasound technology and diagnostic skills has led to earlier**
49
50 **diagnosis of anomalies, with a detection rate of fetal anomalies between 40-50%**
51
52 **during the first trimester (24, 46-49).** In the present study, there was full agreement
53
54 between US and autopsy findings in 86.5% of early TOP and 88.8% of intermediate
55
56
57
58
59
60

1
2
3
4 TOP (Table 4). However, very early diagnoses of anomalies during the embryonic
5
6 period may lead to relatively early TOPs possibly resulting in traumatic destruction of
7
8 the conceptus making verification impossible. Therefore, we tried to delay the final
9
10 sonographic diagnosis to approximately 12 to 13 weeks. Early diagnosis of anomalies
11
12 with early TOP has fewer medical and surgical complications (50). However, earlier
13
14 autopsies represent additional challenges for the perinatal pathologist. Abortion of
15
16 increasingly smaller fetuses necessitates new methods of postmortem examination, and
17
18 a dissecting microscope or magnifying lenses are often necessary to discern features not
19
20 visible to the naked eye, for example in cases with a small VSD. Photo documentation
21
22 is especially useful when examining small fetuses and, when possible, genetic testing
23
24 may verify certain syndromes (51). The progress in ultrasound diagnostics has resulted
25
26 in a diagnostic shift towards “chromosomal markers” (24,52,53), which has proven to
27
28 be of great help in early detection of an underlying anatomical abnormality and in their
29
30 verification.
31
32
33
34
35
36

37 In conclusion, fetal autopsy remains a quality control of the ultrasound findings
38
39 resulting in termination of pregnancy. Our study demonstrates that the correlation is
40
41 continuously improving. However, we believe it is necessary to continue the validation
42
43 practice, in particular due to the challenges of validating diagnosis made very early in
44
45 pregnancy.
46
47
48
49

50 **ACKNOWLEDGEMENT**

51 Nancy Lea Eik-Nes revised the manuscript.
52
53
54
55
56
57
58
59
60

REFERENCES

1. Salomon LJ, Alfirevic Z, Berghella V, Bilardo C, Hernandez-Andrade E, Johnsen SL, Kalache K, Leung KY, Malinger G, Munoz H, Prefumo F, Toi A, Lee W. Practice guidelines for performance of the routine mid-trimester fetal ultrasound scan. *Ultrasound Obstet Gynecol* 2011; 37: 116-26.
2. Vogt C, Blaas HGK, Salvesen KÅ, Eik-Nes SH. Comparison between prenatal ultrasound and postmortem findings in fetuses and infants with developmental anomalies. *Ultrasound Obstet Gynecol* 2012; 39: 666-72.
3. Rodriguez MA, Prats P, Rodriguez I, Cusi V, Comas C. Concordance between prenatal ultrasound and autopsy findings in a tertiary center. *Prenat Diagn* 2014; 34: 784-9.
4. Vimercati A, Grasso S, Abruzzese M, Chincoli A, de Gennaro A, Miccolis A, Serio G, Selvaggi L, Fascilla FD. Correlation between ultrasound diagnosis and autopsy findings of fetal malformations. *J Prenat Med* 2012; 6: 13-7.
5. Hauerberg L, Skibsted L, Graem N, Maroun LL. Correlation between prenatal diagnosis by ultrasound and fetal autopsy findings in second-trimester abortions. *Acta Obstet Gynecol Scand* 2012; 91: 386-90.
6. Picone O, Levailant JM, Hirt R, Frydman R, Boulvain M, Senat MV. Correlation between referral ultrasound with suspected foetal anomalies and autopsy examination in two prenatal diagnosis centres. Impact of the routine use of 3D/4D scan. *Prenat Diagn* 2008; 28: 191-6.
7. Antonsson P, Sundberg A, Kublickas M, Pilo C, Ghazi S, Westgren M, Papadogiannakis N. Correlation between ultrasound and autopsy findings after 2nd trimester terminations of pregnancy. *J Perinat Med* 2008; 36: 59-69.

- 1
2
3
4 8. Akgun H, Basbug M, Ozgun MT, Canoz O, Tokat F, Murat N, Ozturk F.
5
6 Correlation between prenatal ultrasound and fetal autopsy findings in fetal
7
8 anomalies terminated in the second trimester. *Prenat Diagn* 2007; 27: 457-62.
9
- 10 9. Kaasen A, Tuveng J, Heiberg A, Scott H, Haugen G. Correlation between prenatal
11
12 ultrasound and autopsy findings: A study of second-trimester abortions. *Ultrasound*
13
14 *Obstet Gynecol* 2006; 28: 925-33.
15
- 16 10. Ramalho C, Matias A, Brandao O, Montenegro N. Critical evaluation of elective
17
18 termination of pregnancy in a tertiary fetal medicine center during 43 months:
19
20 correlation of prenatal diagnosis findings and postmortem examination. *Prenat*
21
22 *Diagn* 2006; 26: 1084-8.
23
- 24 11. Amini H, Antonsson P, Papadogiannakis N, Ericson K, Pilo C, Eriksson L,
25
26 Westgren M, Axelsson O. Comparison of ultrasound and autopsy findings in
27
28 pregnancies terminated due to fetal anomalies. *Acta Obstet Gynecol Scand* 2006; 85:
29
30 1208-16.
31
32
- 33 12. Boyd PA, Tondi F, Hicks NR, Chamberlain PF. Autopsy after termination of
34
35 pregnancy for fetal anomaly: retrospective cohort study. *BMJ* 2004; 328: 137.
36
37
- 38 13. Yeo L, Guzman ER, Shen-Schwarz S, Walters C, Vintzileos AM. Value of a
39
40 complete sonographic survey in detecting fetal abnormalities: correlation with
41
42 perinatal autopsy. *J Ultrasound Med* 2002 May; 21: 501-10.
43
44
- 45 14. Kaiser L, Vizer M, Arany A, Veszpremi B. Correlation of prenatal clinical findings
46
47 with those observed in fetal autopsies: pathological approach. *Prenat Diagn* 2000;
48
49 20: 970-5.
50
51
52
53
54
55
56
57
58
59
60

- 1
2
3
4 15. Tennstedt C, Chaoui R, Bollmann R, Korner H, Dietel M. Correlation of prenatal
5
6 ultrasound diagnosis and morphological findings of fetal autopsy. *Pathol Res Pract*
7
8 1998; 194: 721-4.
9
- 10 16. Eik-Nes SH. The 18-week fetal examination and detection of anomalies. *Prenat*
11
12 *Diagn* 2010; 30: 624-30.
13
14
- 15 17. Backe B, Buhaug H. Bruk av ultralyd i svangerskapet [Use of ultrasound in
16
17 pregnancy]. Konsensuskonferanse, NIS-rapport nr. 8/1986. Norsk Institutt for
18
19 sykehusforskning, Trondheim 1986.
20
21
- 22 **18. Norges forskningsråd. Bruk av ultralyd i svangerskapet [Use of ultrasound in**
23
24 **pregnancy]. Konsensuskonferanse, Oslo 1995.**
25
- 26 19. Chescheir NC, Reitnauer PJ. A comparative study of prenatal diagnosis and
27
28 perinatal autopsy. *J Ultrasound Med* 1994; 13: 451-6.
29
30
- 31 20. Isaksen CV, Eik-Nes SH, Blaas HGK, Torp SH. Comparison of prenatal ultrasound
32
33 and postmortem findings in fetuses and infants with central nervous system
34
35 anomalies. *Ultrasound Obstet Gynecol* 1998; 11: 246-53.
36
- 37 21. Isaksen CV, Eik-Nes SH, Blaas HGK, Tegnander E, Torp SH. Comparison of
38
39 prenatal ultrasound and postmortem findings in fetuses and infants with congenital
40
41 heart defects. *Ultrasound Obstet Gynecol* 1999; 13: 117-26.
42
43
- 44 22. Isaksen CV, Eik-Nes SH, Blaas HGK, Torp SH. Fetuses and infants with congenital
45
46 urinary system anomalies: correlation between prenatal ultrasound and postmortem
47
48 findings. *Ultrasound Obstet Gynecol* 2000; 15: 177-85.
49
50
- 51 23. Isaksen CV, Eik-Nes SH, Blaas HGK, Torp SH, van der Hagen CB, Ormerod E. A
52
53 correlative study of prenatal ultrasound and post-mortem findings in fetuses and
54
55 infants with an abnormal karyotype. *Ultrasound Obstet Gynecol* 2000; 16: 37-45.
56
57
58
59
60

- 1
2
3
4 24. Blaas HGK. Detection of structural abnormalities in the first trimester using
5 ultrasound. *Best Pract Res Clin Obstet Gynaecol* 2014; 28: 341-53.
6
7
8
9 25. Levi S. Ultrasound in prenatal diagnosis: polemics around routine ultrasound
10 screening for second trimester fetal malformations. *Prenat Diagn* 2002; 22: 285-95.
11
12
13 26. Thayyil S, Cleary JO, Sebire NJ, Scott RJ, Chong K, Gunny R, Owens CM, Olsen
14 OE, Offiah AC, Parks HG, Chitty LS, Price AN, Yousry TA, Robertson NJ,
15 Lythgoe MF, Taylor AM. Post-mortem examination of human fetuses: a comparison
16 of whole-body high-field MRI at 9.4 T with conventional MRI and invasive
17 autopsy. *Lancet* 2009; 374: 467-75.
18
19
20
21
22
23
24 27. The Norwegian Law on Termination of Pregnancy. In: Håndbok for
25 abortnemndarbeid, rapport IS-1496, Helsedirektoratet 2013.
26
27
28
29 **28. Salomon LJ, Alfirevic Z, Bilardo CM, Chalouhi GE, Ghi T, Kagan KO, et al.**
30 **ISUOG practice guidelines: performance of first-trimester fetal ultrasound**
31 **scan. *Ultrasound Obstet Gynecol* 2013; 41: 102-13.**
32
33
34
35 29. Boyd PA, Devigan C, Khoshnood B, Loane M, Garne E, Dolk H. Survey of prenatal
36 screening policies in Europe for structural malformations and chromosome
37 anomalies, and their impact on detection and termination rates for neural tube
38 defects and Down's syndrome. *BJOG* 2008; 115: 689-96.
39
40
41
42
43
44 30. Johns N, Al-Salti W, Cox P, Kilby MD. A comparative study of prenatal ultrasound
45 findings and post-mortem examination in a tertiary referral centre. *Prenat Diagn*
46 2004; 24: 339-46.
47
48
49
50
51 31. Blaas HGK, Eik-Nes SH. Sonoembryology and early prenatal diagnosis of neural
52 anomalies. *Prenat Diagn* 2009; 29: 312-25.
53
54
55
56
57
58
59
60

- 1
2
3
4 32. Phillips JJ, Mahony BS, Siebert JR, Lalani T, Fligner CL, Kapur RP. Dandy-Walker
5 malformation complex: correlation between ultrasonographic diagnosis and
6 postmortem neuropathology. *Obstet Gynecol* 2006; 107: 685-93.
7
8
9
10
11 33. Cohen MC, Paley MN, Griffiths PD, Whitby EH. Less invasive autopsy: benefits
12 and limitations of the use of magnetic resonance imaging in the perinatal
13 postmortem. *Pediatr Dev Pathol* 2008; 11: 1-9.
14
15
16
17 34. Brookes JA, Hall-Craggs MA, Sams VR, Lees WR. Non-invasive perinatal
18 necropsy by magnetic resonance imaging. *Lancet* 1996; 348: 1139-41.
19
20
21 35. Ramalho C, Brandao O, Monterroso J, Matias A, Montenegro N. Cardiac findings
22 in routine fetal autopsies: more than meets the eye? *Eur J Obstet Gynecol Reprod*
23 *Biol* 2012 Aug; 163: 142-7.
24
25
26
27
28 36. Tegnander E, Eik-Nes SH. The examiner's ultrasound experience has a significant
29 impact on the detection rate of congenital heart defects at the second-trimester fetal
30 examination. *Ultrasound Obstet Gynecol* 2006 Jul; 28: 8-14.
31
32
33
34 37. Lapierre C, Rypens F, Grignon A, Dubois J, Dery J, Garel L. Prenatal ultrasound
35 screening of congenital heart disease in the general population: general concepts,
36 guidelines, differential diagnoses. *Ultrasound Q* 2013 Jun; 29: 111-24.
37
38
39
40 38. Akgun H, Basbug M, Ozgun MT, Ozturk F, Okten T. Correlation between prenatal
41 ultrasound and fetal autopsy findings on urinary system anomalies terminated in the
42 second trimester. *Prenat Diagn* 2014; 34: 285-90.
43
44
45
46
47 39. Sankar VH, Phadke SR. Clinical utility of fetal autopsy and comparison with
48 prenatal ultrasound findings. *J Perinatol* 2006; 26: 224-9.
49
50
51
52
53
54
55
56
57
58
59
60

- 1
2
3
4 40. Lomax L, Johansson H, Valentin L, Sladkevicius P. Agreement between prenatal
5
6 ultrasonography and fetal autopsy findings: a retrospective study of second trimester
7
8 terminations of pregnancy. *Ultraschall Med* 2012; 33: E31-7.
9
- 10 41. Phadke SR, Gupta A. Comparison of prenatal ultrasound findings and autopsy
11
12 findings in fetuses terminated after prenatal diagnosis of malformations: an
13
14 experience of a clinical genetics center. *J Clin Ultrasound* 2010; 38: 244-9.
15
16
- 17 42. Clayton-Smith J, Farndon PA, McKeown C, Donnai D. Examination of fetuses after
18
19 induced abortion for fetal abnormality. *BMJ* 1990; 300: 295-7.
20
21
- 22 43. Shen-Schwarz S, Neish C, Hill LM. Antenatal ultrasound for fetal anomalies:
23
24 importance of perinatal autopsy. *Pediatr Pathol* 1989; 9: 1-9.
25
26
- 27 44. Racusin D, Stevens B, Campbell G, Aagaard KM. Obesity and the risk and
28
29 detection of fetal malformations. *Semin Perinatol* 2012; 36: 213-21.
30
31
- 32 45. Tabor A, Zdravkovic M, Perslev A, Moller LK, Pedersen BL. Screening for
33
34 congenital malformations by ultrasonography in the general population of pregnant
35
36 women: factors affecting the efficacy. *Acta Obstet Gynecol Scand* 2003; 82: 1092-8.
37
38
- 39 46. Timor-Tritsch IE, Fuchs KM, Monteagudo A, D'Alton M E. Performing a fetal
40
41 anatomy scan at the time of first-trimester screening. *Obstet Gynecol* 2009; 113:
42
43 402-7.
44
45
- 46 47. Syngelaki A, Chelemen T, Dagklis T, Allan L, Nicolaides KH. Challenges in the
47
48 diagnosis of fetal non-chromosomal abnormalities at 11-13 weeks. *Prenat Diagn*
49
50 2011; 31: 90-102.
51
52
- 53 48. Ebrashy A, El Kateb A, Momtaz M, El Sheikhah A, Aboulghar MM, Ibrahim M,
54
55 Saad M. 13-14-week fetal anatomy scan: a 5-year prospective study. *Ultrasound*
56
57 *Obstet Gynecol* 2010; 35: 292-6.
58
59
60

- 1
2
3
4 49. Iliescu D, Tudorache S, Comanescu A, Antsaklis P, Cotarcea S, Novac L, Cernea N,
5
6 Antsaklis A. Improved detection rate of structural abnormalities in the first trimester
7
8 using an extended examination protocol. *Ultrasound Obstet Gynecol* 2013; 42: 300-
9
10 9.
11
12 50. Gawron LM, Cameron KA, Phisuthikul A, Simon MA. An exploration of women's
13
14 reasons for termination timing in the setting of fetal abnormalities. *Contraception*
15
16 2013; 88: 109-15.
17
18 51. Peres LC, Vogt C. The fetus less than 15 weeks gestation. In *The Pediatric and*
19
20 *Perinatal Autopsy Manual*, Cohen MC, Scheimberg I (eds.) Cambridge University
21
22 Press, 2014; 47-61.
23
24 52. Sonek J, Croom C. Second trimester ultrasound markers of fetal aneuploidy. *Clin*
25
26 *Obstet Gynecol* 2014; 57: 159-81.
27
28
29
30 53. Ahman A, Axelsson O, Maras G, Rubertsson C, Sarkadi A, Lindgren P.
31
32 Ultrasonographic fetal soft markers in a low-risk population: incidence, association
33
34 with trisomies and invasive tests. *Acta Obstet Gynecol Scand* 2014; 93: 367-73.
35
36
37
38
39
40
41
42
43
44
45
46
47
48
49
50
51
52
53
54
55
56
57
58
59
60

Table 1. Congenital anomalies in 1029 autopsies of fetuses terminated between weeks 11 and 33

Diagnoses	Primary diagnosis				Secondary diagnosis		Total diagnoses	
	n	%	Abnormal karyotype		n	%	n	%
			n	%				
Chromosomal anomalies with normal morphology	34	3.3	34	100	-	-	34	1.9
Central nervous system anomalies	354	34.4	66	18.6	66	8.1	420	22.8
Cardiovascular system anomalies	187	18.2	95	50.8	133	16.3	320	17.3
Respiratory system anomalies	6	0.6	2	33.3	35	4.3	41	2.2
Diaphragmatic/abdominal wall defects	55	5.3	26	47.3	52	6.4	107	5.8
Gastrointestinal system anomalies	7	0.7	4	57.1	102	12.5	109	5.9
ARS/LBWC	33	3.2	0	0	1	-	34	1.9
Urinary system anomalies	135	13.1	9	6.7	135	16.5	270	14.6
Genital system anomalies	-	-	-	-	29	3.6	29	1.6
Skeletal anomalies *	11	1.1	3	27.3	146	17.9	157	8.5
Skeletal dysplasia †	67	6.5	4	6.0	-	-	67	3.6
Arthrogyriposis, including LMPS	32	3.1	2	6.3	-	-	32	1.7
Facial defects	5	0.5	2	40.0	66	8.1	71	3.9
Fetal hydrops, cystic hygroma	97	9.4	66	68.0	51	6.3	148	8.0
Conjoined twins	6	0.6	0	0	-	-	6	0.3
Total	1029	100	313	30.4	816	100	1845	100

ARS, Amnion rupture sequence; LBWC, Limb-body-wall complex; LMPS, Lethal multiple pterygium syndrome

* Skeletal anomalies include malposition, isolated limb anomalies, vertebral anomalies, clubfeet, polydactyly, syndactyly, etc.

† Skeletal dysplasia includes osteochondrodysplasias such as thanatophoric dysplasia, achondrogenesis, osteogenesis imperfecta, etc.

Table 2. Fetal karyotype among 1029 pregnancies terminated between weeks 11 and 33

Karyotype		Total		Associated primary diagnosis							
				CNS anomalies		Cardiovascular anomalies		Urinary system anomalies		Fetal hydrops, cystic hygroma	
				n	%	n	%	n	%	n	%
Normal		612	59.5	256	72.3	82	43.9	98	72.6	22	22.7
Unknown *		104	10.1	32	9.0	10	5.3	28	20.7	9	9.3
Abnormal		313	30.4	66	18.7	95	50.8	9	6.6	66	68.0
	Trisomy 13	36	3.5	18	5.1	12	6.4	-	-	1	1.0
	Trisomy 18	90	8.7	23	6.5	37	19.8	1	0.8	4	4.1
	Trisomy 21	85	8.3	4	1.1	33	17.6	2	1.5	20	20.6
	Triploidy	13	1.2	8	2.3	1	0.5	1	0.7	1	1.0
	Turner syndrome	39	3.8	1	0.3	-	-	-	-	37	38.2
	Klinefelter syndrome	3	0.3	-	-	-	-	-	-	-	-
	Other chromosomal aberrations	47	4.6	12	3.4	12	6.4	5	3.7	3	3.1
Total		1029	100	354	100	187	100	135	100	97	100

* Unknown: not karyotyped or karyotyping unsuccessful

Table 3. Distribution of primary diagnoses among 1029 terminated pregnancies between weeks 11 and 33

Primary diagnosis	Detection rate at different gestational ages							
	Week 11+0 to 15+6		Week 16+0 to 21+6		Week 22+0 to 33+6		Week 11+0 to 33+6	
	n	%	n	%	n	%	n	%
Chromosomal anomalies with normal morphology	5	3.6	29	3.6	-	-	34	3.3
CNS anomalies	45	31.9	282	34.7	27	36.0	354	34.4
Cardiovascular system anomalies	25	17.7	149	18.3	13	17.3	187	18.2
Respiratory system anomalies	1	0.7	5	0.6	-	-	6	0.6
Diaphragmatic/abdominal wall defects	11	7.8	36	4.4	8	10.7	55	5.3
Gastrointestinal system anomalies	-	-	7	0.9	-	-	7	0.7
ARS/LBWC	7	5.0	25	3.1	1	1.3	33	3.2
Urinary system anomalies	11	7.8	111	13.6	13	17.3	135	13.1
Genital system anomalies	-	-	-	-	-	-	-	-
Skeletal anomalies *	2	1.4	8	1.0	1	1.3	11	1.1
Skeletal dysplasia †	3	2.1	58	7.1	6	8.0	67	6.5
Arthrogryposis, including LMPS	9	6.4	21	2.6	2	2.7	32	3.1
Facial defects	-	-	4	0.5	1	1.3	5	0.5
Fetal hydrops/cystic hygroma	20	14.2	75	9.2	2	2.7	97	9.4
Conjoined twins	2	1.4	3	0.4	1	1.3	6	0.6
Total	141	100	813	100	75	100	1029	100

ARS, Amnion rupture sequence; LBWC, Limb-body-wall complex; LMPS, Lethal multiple pterygium syndrome

* Skeletal anomalies include malposition, isolated limb anomalies, vertebral anomalies, clubfeet, polydactyly, syndactyly, etc.

† Skeletal dysplasia includes osteochondrodysplasias such as thanatophoric dysplasia, achondrogenesis, osteogenesis imperfecta, etc.

1
2
3
4
5
6
7
8
9
10
11
12
13
14
15
16
17
18
19
20
21
22
23
24
25
26
27
28
29
30
31
32
33
34
35
36
37
38
39
40
41
42
43
44
45
46
47
48
49

Table 4. Correlation between prenatal ultrasound (US) and autopsy findings in 1029 terminated fetuses between 1985 and 2014

Correlation	Detection rate at different gestational ages							
	Week 11+0 to 15+6		Week 16+0 to 21+6		Week 22+0 to 33+6		Week 11+0 to 33+6	
	n	%	n	%	n	%	n	%
Category 1: Full agreement between US and autopsy findings	122	86.5	722	88.8	63	84.0	907	88.1
Category 2: Minor autopsy findings not detected at US	17	12.1	75	9.2	8	10.7	100	9.7
Category 1 + 2 (Correct main diagnosis)	139	98.6	797	98.0	71	94.7	1007	97.8
Category 3: Major autopsy findings not detected at US	1	0.7	5	0.6	3	4.0	9	0.9
Category 4: None of the autopsy findings suspected at US	0	0	0	0	0	0	0	0
Category 5: US findings not confirmed at autopsy	1	0.7	11	1.4	1	1.3	13	1.3
Category 1-5: Total	141	100	813	100	75	100	1029	100

Table 5. Correlation between prenatal ultrasound examination and autopsy findings according to primary diagnosis in 1029 terminated fetuses between 1985 and 2014

Diagnoses	Categories									
	1		2		3		4		5	
	n	%	n	%	n	%	n	%	n	%
Chromosomal anomalies with normal morphology	34	100	0	0	0	0	0	0	0	0
Central nervous system anomalies	319	90.1	27	7.6	5	1.4	0	0	3	0.9
Cardiovascular system anomalies	156	83.4	25	13.4	1	0.5	0	0	5	2.7
Respiratory system anomalies	5	83.3	1	16.7	0	0	0	0	0	0
Diaphragmatic/abdominal wall defects	42	76.4	11	20.0	1	1.8	0	0	1	1.8
Gastrointestinal anomalies	6	85.7	1	14.3	0	0	0	0	0	0
ARS/LBWD	29	87.9	4	12.1	0	0	0	0	0	0
Urinary system anomalies	118	87.4	15	11.1	1	0.7	0	0	1	0.7
Genital anomalies	-	-	-	-	-	-	-	-	-	-
Skeletal anomalies *	8	72.7	1	9.1	1	9.1	0	0	1	9.1
Skeletal dysplasia †	62	92.5	4	6.0	0	0	0	0	1	1.5
Arthrogryposis, including LMPS	32	100	0	0	0	0	0	0	0	0
Facial defects	5	100	0	0	0	0	0	0	0	0
Fetal hydrops/cystic hygroma	86	88.7	10	10.3	0	0	0	0	1	1.0
Conjoined twins	5	83.3	1	16.7	0	0	0	0	0	0
Total	907	88.1	100	9.7	9	0.9	0	0	13	1.3

ARS, Amnion rupture sequence; LBWC, Limb-body-wall complex; LMPS, Lethal multiple pterygium syndrome

* Skeletal anomalies include malposition, isolated limb anomalies, vertebral anomalies, clubfeet, polydactyly, syndactyly, etc.

† Skeletal dysplasia includes osteochondrodysplasias such as thanatophoric dysplasia, achondrogenesis, osteogenesis imperfecta, etc.

1. Full agreement between ultrasound and autopsy findings
2. Minor autopsy findings not seen or recorded at ultrasound examination
3. Major autopsy findings not detected at ultrasound examination
4. None of the autopsy findings suspected at ultrasound examination
5. Ultrasound findings not confirmed or not possible to confirm at autopsy

Table 6. Category 3 – Major autopsy findings not detected at prenatal ultrasound among 9 terminated fetuses between 1985 and 2014

Case n=9	Year	Mat. age	Sex	GA	Indication for TOP	Final diagnosis after autopsy	Major autopsy findings not detected at ultrasound
1	1986	31	M	23	Cystic dysplastic kidneys	Meckel-Gruber syndrome with cystic dysplastic kidneys, occipital myelocele and polydactyly	Occipital myelocele, polydactyly
2	1986	25	F	23	Cystic dysplastic kidneys (anhydramnios), short extremities, small thorax	VSD and common ventricle, lung hypoplasia, cystic dysplastic kidneys, micrognathia, cleft palate, short extremities. Possible Saldino-Noonan syndrome (radiology not performed)	VSD and common ventricle, micrognathia, cleft palate
3	1986	34	F	21	Corpus callosum agenesis, gastroschisis, scoliosis and pelvic deformity	LBWC, corpus callosum agenesis, scoliosis and pelvic deformity	LBWC interpreted as large gastroschisis at US
4	1988	21	M	22	Hydrocephalus	Hydrocephalus, left renal agenesis, bilateral radial aplasia with missing thumb	Left renal agenesis, bilateral radial aplasia with missing thumb
5	1988	22	M	18	Oligohydramnion, lung hypoplasia, vertebral deformities, clubfeet	Renal agenesis, anal atresia, lung hypoplasia, vertebral deformities, clubfeet	Renal agenesis (adrenals interpreted as kidneys by US), anal atresia
6	1992	26	F	21	Triploidy, IUGR, holoprosencephaly, lumbosacral bifid spine, left renal agenesis and cystic dysplastic right kidney	Triploidy, IUGR, holoprosencephaly, lumbosacral bifid spine, omphalocele, left renal agenesis and cystic dysplastic right kidney, VSD, syndactyly right hand	VSD, omphalocele, syndactyly right hand
7	1993	29	M	18	Alobar holoprosencephaly, urethral and anal atresia, cleft lip and palate	Alobar holoprosencephaly, cystic dysplastic kidneys, urethral and anal atresia, cleft lip and palate	Cystic dysplastic kidneys

8	2012	34	M	19	Lumbosacral myelomeningocele, Arnold Chiari malformation, left clubfoot	Lumbosacral myelomeningocele, Arnold Chiari malformation, left clubfoot, right renal agenesis and double left ureter.	Right renal agenesis and double left ureter
9	2013	24	F	13	Thoracal scoliosis, dysplastic right lower limb with missing fibula	Thoracal scoliosis, dysplastic right lower limb with missing fibula, cystic dysplastic right kidney and hydronephrosis left kidney, esophageal atresia with tracheoesophageal fistula, anal atresia and persistent cloaca	Cystic dysplastic right kidney and hydronephrosis left kidney, esophageal atresia with tracheoesophageal fistula, anal atresia and persistent cloaca

Mat. age, maternal age; IUGR, intrauterine growth restriction; LBWC, limb-body-wall complex; VSD, ventricular septal defect

Table 7. Category 5 – Prenatal ultrasound findings not confirmed or not possible to confirm at autopsy among 13 terminated fetuses between 1985 and 2014

Discrepant anomalies	Case n=13	Year	Mat. age	Sex	GA	Indication for TOP	Final diagnosis after autopsy	Ultrasound findings not confirmed or not possible to confirm at autopsy
CNS anomalies (n=3)	1	1991	28	F	23	Microcephaly, IUGR, Dandy-Walker anomaly	Microcephaly, IUGR	Dandy-Walker anomaly
	2	1992	35	F	22	Hydrocephaly, IUGR	IUGR	Hydrocephaly (not confirmed due to fetal maceration)
	3	1996	30	F	19	Trisomy 13, Tetralogy of Fallot, Dandy-Walker anomaly and cerebellar hypoplasia, bilateral cleft lip and palate	Trisomy 13, Tetralogy of Fallot, bilateral cleft lip and palate, cerebellar hypoplasia	Dandy-Walker anomaly (brain was autolytic)
Cardiovascular system anomalies (n=5)	4	1991	41	M	19	Trisomy 21, AVSD	Trisomy 21, possible ASD and VSD	Not AVSD at autopsy
	5	1992	41	M	13	Trisomy 18, AVSD	Trisomy 18	AVSD (not confirmed due to traumatised fetus)
	6	2003	33	F	18	Trisomy 18 (FISH), VSD and double outlet right ventricle, bilateral cleft lip and palate, bilateral claw hand	Trisomy 18, aortic coarctation, bilateral cleft lip and palate, bilateral claw hand	VSD and double outlet right ventricle
	7	2005	39	M	21	Trisomy 18 (FISH), small VSD and overriding aorta, choroid plexus cyst, vertebral deformities, syndactyly left foot	Trisomy 18, choroid plexus cyst, vertebral deformities, syndactyly left foot	Small VSD and overriding aorta
	8	2005	32	M	20	Trisomy 13, VSD, double outlet right ventricle and overriding aorta, left cleft lip and palate, polydactyly	Trisomy 13, left cleft lip and palate, polydactyly, arhinencephaly (not seen at US)	VSD, double outlet right ventricle and overriding aorta

Urinary system anomalies (n=4)	9	1987	26	F	18	Cystic dysplastic kidneys (oligohydramnios)	Renal agenesis	Cystic dysplastic kidneys
	10	1993	26	M	19	Trisomy 18, IUGR, cystic dysplastic kidneys, VSD, fetal hydrops/cystic hygroma, limb contractures (possible arthrogyrosis)	Trisomy 18, IUGR, VSD, fetal hydrops/cystic hygroma, limb contractures	Cystic dysplastic kidneys
	11	2001	36	M	22	Trisomy 18, omphalocele, AVSD, unilateral cystic dysplastic kidney, bilateral cleft lip and palate, claw hands	Trisomy 18, omphalocele, AVSD, bilateral cleft lip and palate, claw hands	Unilateral cystic dysplastic kidney
	12	1990	34	F	18	Turner syndrome, fetal hydrops and cystic hygrom, cystic dysplastic kidneys	Turner syndrome, fetal hydrops and cystic hygrom	Cystic dysplastic kidneys
Skeletal dysplasia (n=1)	13	1987	17	F	23	Lethal dwarfism	Short limbs and large head in relation to extremities. Hypoplastic lungs.	Lethal dwarfism

Mat. age, maternal age; IUGR, intrauterine growth restriction; LBWC, limb-body-wall complex; VSD, ventricular septum defect; AVSD atrioventricular septum defect; FISH, fluorescence in situ hybridization

Table 8. Studies of TOP during the last decade (2006-2015) comparing prenatal ultrasound examination and autopsy findings

Study	Year	TOP (n)	Full agreement Category 1 (%)	Additional findings by autopsy Category 2-3 (%)	Disagreement Category 5 (%)	Gestational age (weeks)
Struksnæs et al.	2015	1029	88.1	10.6	1.3 (1.0*, 0.3†)	11-33
Rodriguez et al.	2014	151	86.0	4.6	9.1 (1.9*, 7.2†)	11-24
Vimercati et al.	2012	144	49.0	34.0	17 (13.0*, 4.0†)	12-24
Hauerberg et al.	2012	52	46.0	44.0	9.6 (7.7*, 1.9†)	12-25
Lomax et al.	2012	71	44.0	46.0	10 (8.6*, 1.4†)	16-22
Antonsson et al.	2008	112	44.6	40.2	15.2 (11.6*, 3.6†)	Second trimester
Akgun et al.	2007	107	51.0	42.0	0	13-28
Kaasen et al.	2006	274	58.4	31.4	9.9*	12-24
Amini et al.	2006	328	53.4	37.8	8.8 (7.0*, 1.8†)	11-24
Ramalho et al.	2006	76	61.1	33.6	5.3†	7-35

* Proportion of TOPs with ultrasound findings that were not confirmed by autopsy. These findings came in addition to other findings that were confirmed by autopsy, and they did not affect the clinical indication for terminating the pregnancy.

† Proportion of TOPs where the clinical indication for terminating the pregnancy, based on specific ultrasound findings, could not be supported by the autopsy findings. The disagreements between prenatal US and autopsy findings were often due to the presence of prenatally oligo/anhydramnion and/or postmortem fetal maceration/autolysis.

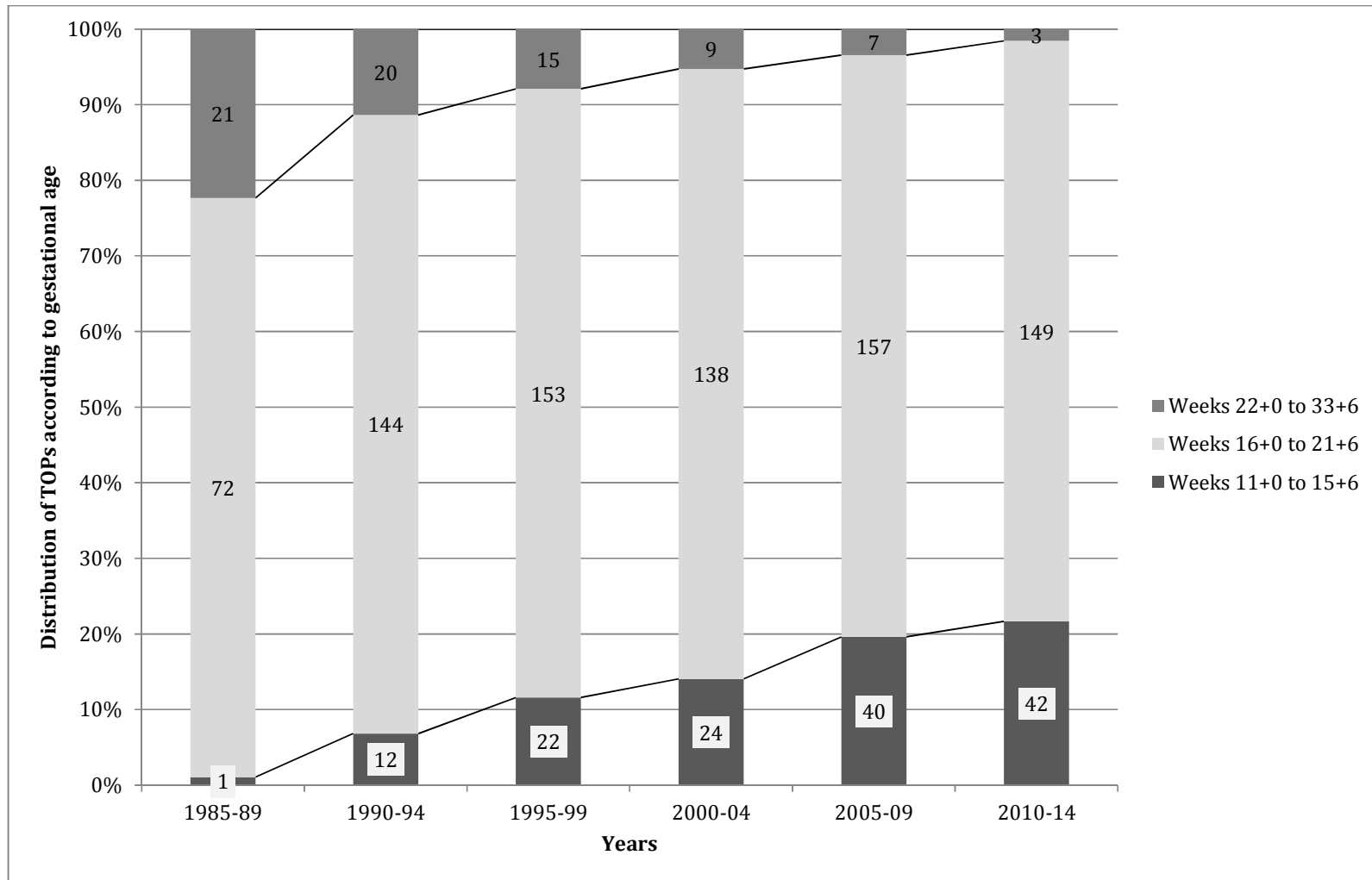
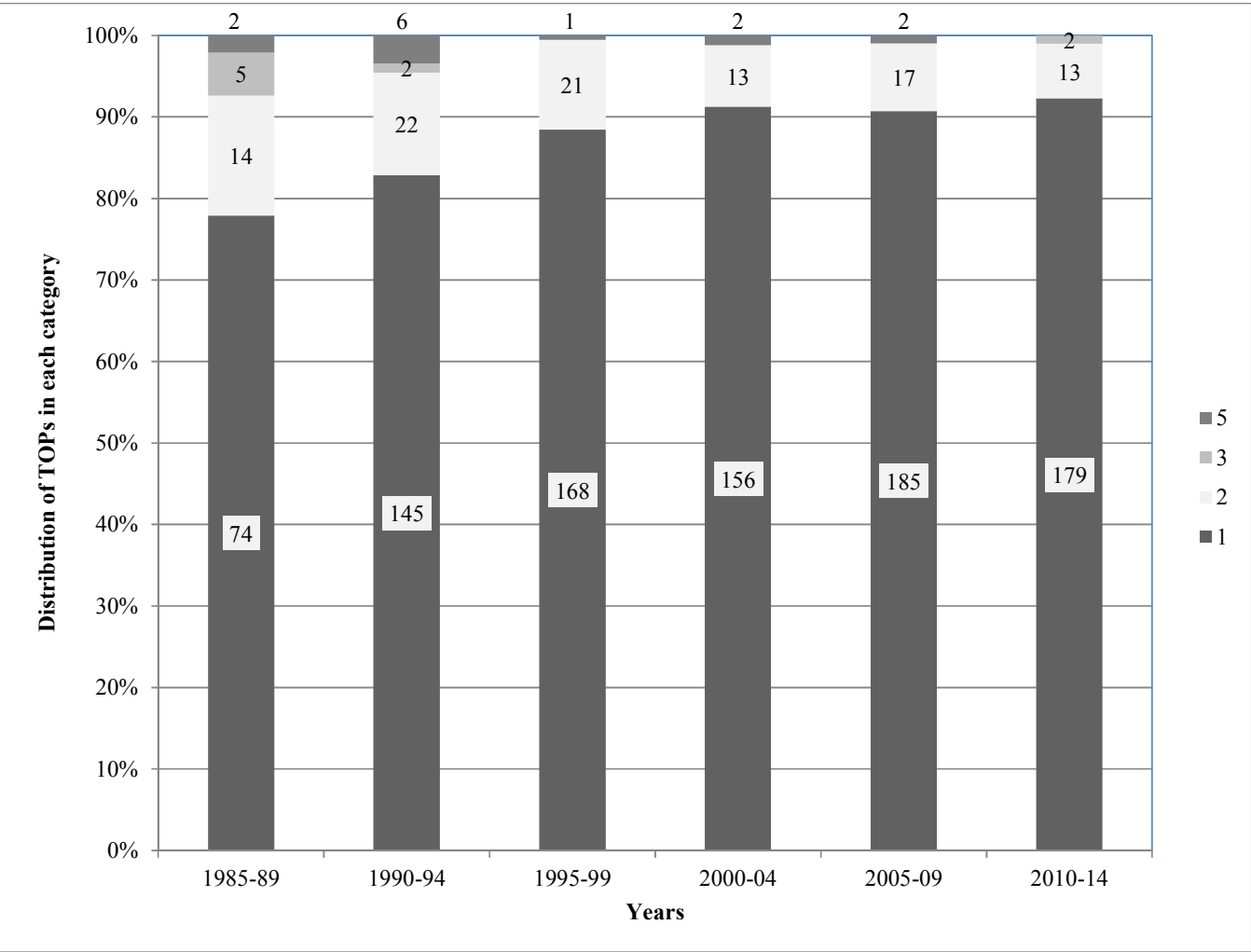


Figure 1. The rate of terminations in weeks 11+0 to 15+6 (early TOP), weeks 16+0 to 21+6 (intermediate TOP) and weeks 22+0 to 33+6 (late TOP) over five-year intervals between 1985 and 2014 for 1029 fetuses. The numbers in each column represents the number of TOPs.

1
2
3
4
5
6
7
8
9
10
11
12
13
14
15
16
17
18
19
20
21
22
23
24
25
26
27
28
29
30
31
32
33
34
35
36
37
38
39
40
41
42
43
44
45
46
47
48
49



1. Full agreement between ultrasound and autopsy findings
2. Minor autopsy findings not seen or recorded at ultrasound examination
3. Major autopsy findings not detected at ultrasound examination
4. None of the autopsy findings suspected at ultrasound examination
5. Ultrasound findings not confirmed or not possible to confirm at autopsy

Figure 2. The distribution of TOPs in each correlation category among 1029 terminated fetuses over five-year intervals between 1985 and 2014. The numbers in each column represent the number of TOPs in each category.